STUDIES ON THE HEPATOPROTECTIVE EFFECTS OF WHITE GRUBS (*PHYLLOPHAGA EPHILIDA (*SAY)) METHANOLIC EXTRACTS ON LIVER INJURY INDUCED BY CABON TETRACHLORIDEIN RATS

BY

MUSA MARWANA

DEPARTMENT OF BIOLOGICAL SCIENCES

AHMADU BELLO UNIVERSITY, ZARIA

NIGERIA

MARCH, 2015

STUDIES ON THE HEPATOPROTECTIVE EFFECT OF WHITE GRUBS (*PHYLLOPHAGA EPHILIDA*(SAY)) METHANOLIC EXTRACTS ON LIVER INJURY INDUCED BY CARBON TETRACHLORIDEIN RATS

BY

Musa MARWANA B.Sc Ed (UMYU) 2010
MSc./Sci/9971/2011-2012

A THESIS SUBMITTED TO THE SCHOOL OF POSTGRADUATE STUDIES, AHMADU BELLO UNIVERSITY, ZARIA IN PARTIAL FULFILLMENT OF THE REQUIREMENTS FOR THE AWARDOF MASTER OF SCIENCE (MSc) DEGREE IN ZOOLOGY

DEPARTMENT OF BIOLOGICAL SCIENCES

FACULTY OF SCIENCE

AHMADU BELLO UNIVERSITY, ZARIA

NIGERIA

MARCH, 2015

DECLARATION

I declare that the work in this thesis entitled, "*Studies on the hepatoprotective effects of White Grubs (Phyllophagaephilida Say) methanolic extracts on liver injury induced by carbon tetrachloride in rats*" has been carried out by me in the Department of Biological Sciences. The information derived from the literature has been duly acknowledged in the text and a list of references provided. No part of this thesis was previously presented for another degree or diploma at this or any other institution.

Musa MARWANA _____ _____

Signature **Date**

CERTIFICATION

This thesis entitled "STUDIES ON THE HEPATOPROTECTIVE EFFECTS OF WHITE GRUBS (*PHYLLOPHAGA EPHILIDA*)METHANOLIC EXTRACTS ON LIVER INJURY INDUCED BY CARBON TETRACHLORIDE IN RATS" by Musa MARWANA meets the regulations governing the award of the Degree of Master of Science in Zoology of Ahmadu Bello University, and is approved for its contribution to knowledge and literary presentation.

Prof. I. H. Nock Chairman, Supervisory Committee Department of Biological Sciences, Ahmadu Bello University, Zaria.	_____ Signature	_____ Date
Dr. A. Ahmed Member, Supervisory Committee Department of Pharmacognosy And Drug development, Ahmadu Bello University, Zaria.	_____ Signature	_____ Date
Prof. A. K. Adamu Head of Department Department of Biological Sciences, Ahmadu Bello University, Zaria.	_____ Signature	_____ Date
Prof. A. Z. Hassan Dean, Postgraduate School Ahmadu Bello University, Zaria.	_____ Signature	_____ Date

DEDICATION

Thanks to Almighty God for giving me the strength and courage during the course of this programme, and to members of my family for their full support.

ACKNOWLEDGEMENTS

This work is a success as result of tremendous support and contributions of some individuals.

My appreciation goes to my supervisors; Professor I. H. Nock for his time and advice and the opportunity he granted me to work on this project. My appreciation also goes to my Co-supervisor, Dr. A. Ahmed for his patience and attention in guiding me during the course of the work and in reading the manuscripts, I am very grateful sir.

I am also grateful to Mal. BabbaLomi of KukaBiyar Village, All staff of the Animal House, Department of Pharmacology, especially Mal. Salihu and Alh. Ya'u for their guidance during the practical work, I would not forget the immense contribution of Mal. Kamilu, Mal. Kabiru and Mal. Mustapha of Pharmacognosy Laboratory for their technical support.

I shall ever be grateful to my Aunty Hajiya Maryam and her husband AlhajiJafaru, for being my parent in Zaria.

I wish to acknowledge the Head of Department of Biological Sciences and entire members of staff for their contributions.

Finally, I am thankful to my father AlhajiMarwana, my mother HajiyaAmina, and my siblings for their love and support.

ABSTRACT

This study was carried out to evaluate the hepatoprotective effects of the methanolic extracts of white grubs (anterior and posterior portions) on liver injury induced by carbon tetrachloride (CCl_4) in rat (*Rattusnorvegicus*). The anterior methanolic extract (AME) and posterior methanolic extract (PME) were obtained from the incision of white grub's abdomen and extracted by using methanol. Male albino rats weighing between 150g- 200g were used. Ten groups of rats (n=6) were administered orally, once in a day for five days with normal saline (negative control), 10mg/kg of silymarin (positive control) or 50mg/kg and 100mg/kg of posterior methanolic extract (PME) and anterior methanolic extract (AME) of white grubs respectively followed by hepatotoxicity induction using CCl_4 on day 2 and 3 of the experiment. Blood and liver samples were collected for biochemical and histopathological studies. The extract was also subjected to antioxidant study using 2, 2-diphenyl-1-picrylhadrazyl (DPPH) radical scavenging assay. Rats pretreated with silymarim, PME (50mg/kg) and AME (100mg/kg) and normal control groups showed a significant decrease ($p \leq 0.05$) in the levels of aspartate amino transferase (AST), alanine amino transferase (ALT) and alkaline phosphatase (ALP). Histopathologicalstudy showed intense vacuolation, hepatic necrosis and haemorrhage in CCl_4 (negative control), PME (100mg/kg), AME (50mg/kg) pretreated groups;while normal hepatic structure was observed in groups pretreated with silymarin, PME (50mg/kg), AME (100mg/kg) and normal control groups. PME exhibited antioxidant activity. The study shows that PME (50mg/kg) and AME (100mg/kg) have hepatopotective effects against CCl_4–induced liver damage.

TABLE OF CONTENTS

Title page.....i

Declaration.....ii

Certification.....iii

Dedication.....iv

Acknowledgements.....v

Abstract.....vi

Table of Contents.....vii

List of Tables.....xii

List of Figures.....xiii

List of Plates..... xiv

CHAPTER ONE

1.0 INTRODUCTION..... 1

1.1 General Introduction..... 1

1.2 Statement of the Research Problem..... 6

1.3 Justification..... 6

1.4 Aim of the Study..... 6

1.5 Objectives.....7

1.6 Hypotheses..... 7

CHAPTER TWO

2.0 LITERATURE REVIEW..... 8

2.1 Traditional Medicine..... 8

2.1.1 Traditional medicine in the world....8
2.1.2 Traditional medicine in Africa....10
2.1.3 Traditional medicine in Nigeria....12
2.1.4 Zootherapy....13
2.2 White Grubs....16
2.2.1 Adult....16
2.2.2 Larvae....17
2.2.3 Distribution and life history....19
2.2.4 Species identification....20
2.2.5 Economic importance....21
2.2.6 Chemical content of white grubs....23
2.3 Liver....26
2.3.1 Functions of liver....26
2.3.2 Anatomy of liver....27
2.3.3 Bile duct, blood vessels and lobules....28
2.3.4 Physiology of liver....30
2.3.5 Detoxification....30
2.4 Stages of Liver Toxicity....30
2.4.1 Fatty liver and inflammation....30
2.4.2 Fibrosis....31
2.4.3 Cirrhosis....31
2.4.4 Liver failure....32
2.5 Types and Causes of Liver Toxicity....32

2.5.1 Hepatitis.....32
2.5.2 Effects of drugs.....32
2.5.3 Alcohol.....34
2.6 Carbon Tetrachloride.....34
2.6.1 Metabolism.....35
2.6.2 General toxicity.....36
2.7 Acute Toxicity.....37
CHAPTER THREE
3.0 MATERIALS AND METHODS.....38
3.1 Sample Collection and Identification.....38
3.2 Extract Preparation.....38
3.3 Experimental Animals.....38
3.4 Toxicity Studies.....41
3.5 Experimental Design.....42
3.5.1 Administration of extracts.....42
3.5.2 Administration of carbon tetrachloride.....42
3.6 Estimation of Biochemical Parameters.....42
3.6.1 Aspartate aminotransferase (AST).....43
3.6.2 Alanine aminotransferase (ALT).....43
3.6.3 Alkaline phosphatase (ALP).....44
3.7 Histopathological Examination of The Liver.....45
3.8 DPPH Radical-Scavenging Activity.....45
3.9 Statistical Analysis.....46

CHAPTER FOUR

4.0 RESULTS.....47

4.1 Toxicity Studies In Rats (LD_{50}).....47

4.2 Biochemical Studies.....52

4.3 Histopathological Studies.....52

4.4 DPPH Radical-Scavenging Activity.....57

CHAPTER FIVE

5.0 DISCUSSION.....61

5.1 Discussion.....61

CHAPTER SIX

6.0 SUMMARY, CONCLUSION AND RECOMMENDATION.....67

6.1 Summary.....67

6.2 Conclusion.....67

6.3 Recommendations.....68

REFERENCES.....69

APPENDICES.....79

LIST OF TABLES

Table **Page**

Table 1: Toxicity of Posterior Methanolic Extract Administered Orally to Rats.....48

Table 2: Toxicity of Anterior Methanolic Extract Administered Orally to Rats..... 49

Table 3: Effect of Posterior Methanolic Extract on weight of Organs of Rats.....50

Table 4: Effect of Anterior Methanolic Extract On weight of Organs Weight of Rats.....51

Table 5: Effect of Posterior MethanolicExtract on Enzyme Activities.....53

Table 6: Effect of Anterior MethanolicExtract on Enzyme Activities.....54

Table 7: Effect of anterior and posterior methanolic extracts on enzymes activities.....55

LIST OF FIGURES

Figure **Page**

Figure 1: White Grubs Identification.....22

Figure 2**:** In vitro Free Radical Scavenging Pattern of Posterior Methanolic Extract with 2, 2-Diphenyl-1-picrylhydrazyl.....59

Figure 3: In vitro Free Radical Scavenging Pattern of Ascorbic Acid with 2, 2-Diphenyl-1-picrylhydrazyl.....60

LIST OF PLATES

Plate **Page**

Plate I: Adult May/June Beetle.....18

Plate II: White Grubs.....40

Pate III(a): Section of Liver treated with PME (100mg/kg b. wt.) + CCl_4.....56

Plate III(b): Section of treated PME 50mg/kg b. wt. liver + CCl_4.....56

Plate III(c): Liver Section of Positive Control Group (silymarin 10mg/kg b. wt.).....56

Plate III(d): Liver Section of the Rat intoxicated with CCl_4..... 56

Plate III(e): Normal Control Liver of Rat with Normal Histology.....56

Plate IV(a): The Section of Liver treated with AME (100mg/kg b. wt.).....58

Plate IV(b): Section of the Liver treated with CCl_4 + AME (50mg/kg b. wt.).....58

Plate IV(c): Section of Liver treated with Silymarin(10mg/kg b. wt.).....58

Plate IV(d): Section of the Liver treated with CCl_4.....58

Plate IV(e): Section of the Liver in the control rats.....58

List of Appendices

Appendix **Page**

Appemdix I:Liver sections of toxicology studies of anterior methanolic extract..... 79

CHAPTER ONE

1.0 INTRODUCTION

1.1 General Introduction

Traditional medicine has a long history. It is the sum total of the knowledge, skills and practices based on the theories, beliefs and experiences indigenous to different cultures, whether explicable or not, used in the maintenance of health, as well as in the prevention, diagnosis, improvement or treatment of physical and mental illnesses. The terms complementary/alternative/non-conventional medicine are used interchangeably with traditional medicine in some countries (WHO, 2013).

In some Asian and African countries, 80% of the population depends on traditional medicine for primary health care. In many developed countries, 70% to 80% of the population use some form of alternative or complementary medicine (e.g. acupuncture)(WHO, 2008). Herbal treatments are the most popular form of traditional medicine, and are highly lucrative in the international market. Annual revenues in Western Europe reached US$ 5 billion in 2003-2004 (Richter, 2003). In China, sales of such products totaled US$ 14 billion in 2005. Herbal medicine revenue in Brazil was US$ 160 million in 2007(WHO, 2008).

The healing of human ailments by using therapeutics based on medicines obtained from animals or ultimately derived from them is known as zootherapy (Costa-Neto, 2005). In modern society, zootherapy constitutes an important alternative among many other known therapies practiced worldwide (Alves and Rosa, 2005). Research interest and activities in the areas of ethnobiology and ethnomedicine have increased tremendously in the last

decade. Since the inception of the disciplines, scientific researches in ethnobiology and ethnomedicine have made important contributions to understanding traditional subsistence and medical knowledge and practice (Pieroni, 2005). Since ancient time animals, their parts and their products have constituted part of the inventory of medicinal substances used in various cultures (Mahawarand Jaroli,2007).

Entire organism and their body parts like flesh, bones, teeth, bone marrow, fat, shells musk, secretions, tentacles, as well as products like urine and excreta (dung) are used in traditional medicine. They are used either alone or in combination with other herbs and minerals. Some species of mammals have proved a vital source of traditional medicine (Padmanabhan and Sujana, 2008).Among the domesticated animals, the products of cow, buffalo, camel, goat, sheep and pigs are mostly used, while among the wild animals, the product of tiger, panther, leopard, monkey mongoose, fox, hare, samba deer, porcupine and wild boar are used (Adeola, 1992; Anagelett*i et al.*, 1992). Body parts mostly used are exoskeleton, tissues, blood, fat, bones and gastrointestinal tracts. Similarly, insect larvae (White grubs) is used in the treatment of jaundice, fever, and general body weakness and as food ingredients by various communities in northern Nigeria (Alhassan*et al.*, 2009).

White grub (WG) is the larval stage of many species of beetle. Dung beetles play a crucial role by burying dung in natural savannah and grassland used for cattle grazing in Africa (Brussard and Hijdrin, 1986). In addition to their effect on plants, other species biodegrade, environmental wastes. A functional group found in soil consists of a group of organisms that have the same function and similar impact on soil and are called macro fauna and white grub is one of them (Gitay and Nobel, 1997).

True white grubs are the larvae of May beetles (also called June Beetles) found in the genus *Phyllophaga*, of which there are over 100 different species. *Phyllophaga* larvae and other larvae of the family Scarabaeidae are often referred to as "white grubs", including larvae of the Japanese beetle (*Popillia japonica* Newman), annual white grubs (*Cyclocephala* spp.), and the green June beetle (*Cotinisnitida* Linnaeus) (Brian, 2013).

June beetles (*Phyllophaga*species) have a three-year lifecycle and cause most damage in the second year. In June, the adult lays eggs in the soil and within two weeks the white grubs emerge (Watschke*et al*., 1995). The grubs feed on grass roots during the warm summer months, and then move deep into the soil for the winter. The grubs continue feeding the second summer, then transformed into the adult beetle during the third year (Hebda, 2010).

Many of the white grub species look similar to each other but vary in size. Mature grubs range in size from 1cm - 5cm. In general, grubs are C-shaped and have three pair of thoracic legs. The head capsule is dark, but the body is usually creamy white in color. The arrangement of hairs and spines on the posterior end of the grub, called the raster, is a distinguishing feature between white grubs' species (Hodgson, 2007).

The May/June beetles require three years to complete one generation. Adults are usually larger in size compared to the masked chafer and Japanese beetle and range from tan to black in colour (Ralph, 1998). Adults start emerging from turf grass in May and June and are strongly attracted to lights like the masked chafer. During the first summer, mated females deposit eggs in turf grass. Eggs hatch into small white grubs that feed on small turf grass roots until the temperature cools. Small grubs are the overwintering stage until the

next spring when they become active again. During the second summer, grubs continue to grow while feeding on larger turf grass roots until they are almost fully-developed. The large grubs are the overwintering stage. During the third summer, grubs pupate in the soil and adults emerge in May and June (Hodgson, 2007).

The larvae of May/June beetle have a large, fleshy, white to translucent body with a brown head capsule, large jaws with three pairs of brown legs on the thorax. The posterior (hind) portion of the abdomen is slightly enlarge and appears darker. While the anterior portion of the abdomen is whitish in colour. Two parallel rows of spines on the ventral segment of the abdominal end distinguish true white grubs from other larvae (Hill, 2008).

White grubs among Hausa – Fulani is called "Gwazarma or Doli – doli" and is used in the treatment of jaundice, fever and general body weakness, and as food ingredient by various communities in northern Nigeria (Alhassan*et al.,* 2009). According to Murtala*et al.*(2011) guinea pigs treated with 0.834g/kg aqueous white grubs extract for 48 and 96 hours had serum aspartate aminotransferase (AST), alanine aminotransferase (ALT) and alkaline phosphatase (ALP) very close to those of normal control but significantly decreased (at $P>0.05$) as compared to toxicity control . This would probably be due to hepatocurative effect of aqueous white grubs extract on chemically induced hepatocellular damage(Murtala*et al.*, 2011).Nevertheless, the serum cholesterol and triglyceride levels in guinea pigs after 48 and 96 hours of treatment with aqueous white grubs extract showed a significant increase in serum cholesterol and triglyceride compared to toxicity control (at $p<0.05$). The decrease in the serum levels of AST, ALT and ALP of tests compared to toxicity control and the increase in serum cholesterol and triglyceride are indications of

possible curative effect of aqueous white grubs extract on CCl_4 induced liver damage. Alhassan and Sule (2011) reported the percentage of humic substances (fulvic acid, humic acid and humin) in white grubs (WG) as 16.05 ± 4.28% fulvic acid, 9.50 ± 2.06% humic acid and 74. 65 ± 11.31% humin and that the mineral contents of white grub in terms of relative concentration was found to be in rank of K > Mg > Na >Ca>Mn> Zn > Fe > Cu.White grubs obtain these humic substances and mineral elements from the environmental waste and were found in appreciable amount to meet nutritional requirements and therefore, could be nutritionally and medically relevant (Alhassan and Sule, 2011).

The assumed hepatoprotective property was ascribed to any of the two white grub abdominal fluids. The antioxidant and hepatoprotective effects of the two abdominal components, of white grubs extract have not been investigated and therefore not known.

Liver is one of the largest organs in human body and the site for intense metabolism andexcretion. Thus, to maintain a healthy liver is a crucial factor for overall health and well-being. But it is continuously and variedly exposed to environmental toxins, and abused by poor drug habits, and alcohol and prescribed and over-the-counter drugs, which can eventually lead to various liver ailments like hepatitis, cirrhosis and alcoholic liver disease (Subranonium andPushpangadan, 1999; Sharma *et al*., 1991).

Carbon tetrachloride (CCl_4) is widely used for experimental induction of liver damage. The principle cause of CCl_4 induced hepatic damage in lipid peroxidation and decreased activities of anticooxidant enzymes and generation of free radicals (Shahjahan*et al.*, 2004).

In long term repeated dose studies in animals, the liver has been shown to be the most sensitive organ regarding toxicity (Shahjahan*et al.,* 2004).

1.2 Statement of the Research Problem

Whole white grub fluid is known to protect liver from injury induced by CCl_4; whether this is conferred by one or all the two components of the white grub fluid has not been clearly determined and thus not known.

1.3 Justification

White grub is traditionally used in the treatment of jaundice, fever and general body weakness, and as food ingredient by various communities in northern Nigeria. The result of this study could add value or otherwise to the use of white grubs in traditional medications. It will also provide baseline information about hepatoprotective potentials of the two components (posterior methanolic extract and anterior methanolic extract) of white grubs extract. Moreover it provide basis by which bioactive compounds could be extracted from the grubs and characterized to produce drugs.

1.4Aim of the study

To evaluate the prophylactic effect of the two abdominal fluids of white grub on liver injury in albino rats in order to standardized their therapeutic use.

1.5 Objectives

To determine:

i. The protective effect of the anterior and posterior abdominal components of white grubs' methanolic extracts (PME and AME) on liver injury.

ii. The antioxidant activities of posterior abdominal component of white grubs extract using 2, 2-diphenyl-1-picrylhydrazil (DPPH) assay.

1.6 Hypotheses

i. The anterior and posterior methanolic extracts (AMEand PME) have no protective effect on liver injury.

ii. The posterior methanol extracts (PME) have no antioxidant activities in DPPH assay.

CHAPTER TWO

2.0 LITERATURE REVIEW

2.1 Traditional Medicine

Traditional medicine is a way of protecting and restoring health that existed before the arrival of modern medicine(Holliday, 2003). As the term implies, these approaches to health belong to the traditions of each country, and have been handed down from generation to generation. Traditional systems in general have had to meet the needs of the local communities for many centuries. China and India, for example, have developed very sophisticated systems such as acupuncture and ayurvedic medicine respectively. In practice, the term "traditional medicine" refers to the following components: acupuncture, traditional birth attendants, mental healers and herbal medicine (Richter, 2003)

According to World Health Organization (2013),traditional medicine (TM) refers to the knowledge, skills and practices based on the theories, beliefs and experiences indigenous to different cultures, used in the maintenance of health and in the prevention, diagnosis, improvement or treatment of physical and mental illnesses. Traditional medicine covers a wide variety of therapies and practices which vary from country to country and region to region. In some countries, it is referred to as "alternative" or "complementary" medicine (CAM).

2.1.1Traditional medicine in the World

Over the years, the World Health Assembly has adopted a number of resolutions drawing attention to the fact that most of the population in various developing countries around the world depend on traditional medicine for primary health care and that the work force

represented by practitioners of traditional medicine is a potentially important resource for the delivery of health care and that medicinal plants are of great importance to the health of individuals and communities. A genuine interest in various traditional practices now exists among practitioners of modern medicine and growing numbers of practitioners of traditional, indigenous or alternative systems are beginning to accept and use some of the modern technology. This will help foster teamwork among all categories of health workers within the framework of primary health care. The reasons for the inclusion of traditional healers in primary health care are manifold: the healers know the sociocultural background of the people; they are highly respected and experienced in their work; economic considerations; the distances to be covered in some countries; the strength of traditional beliefs; the shortage of health professionals, particularly in rural areas, to name just a few (Richter, 2003).

Traditional medicine has been used for thousands of years with great contributions made by practitioners to human health, particularly as primary health care providers at the community level. TM/CAM has maintained its popularity worldwide. Since the 1990s its use has surged in many developed and developing countries (WHO, 2013).

A large proportion of the population in a number of developing countries still relies on traditional practitioners, including traditional birth attendants, herbalists and bone-setters and on local medicinal plants to satisfy their primary health care needs. WHO estimates that traditional birth attendants assist in up to 95% of all rural births and 70% of urban births in developing countries (Bang*et al.*, 1999).

Traditional medicine has maintained its popularity in a number of Asian countries, such as China, India, Japan and Pakistan. In China, for example, traditional medicines (herbal preparations) account for 30% to 50% of the total medicinal consumption. In 1993, the total sales of herbal medicines amounted to more than US$ 2.5 billion. In Japan, from 1974 to 1989, there was a 15-fold increase in Kampoh ("Chinese method") medicinal preparations in comparison with only 2.6-fold increase in the sales of mainstream pharmaceutical products. The Japanese per capita consumption of herbal medicine appears to be the highest in the world (Richter, 2003).

During the last decade, there has also been a growing interest in traditional and alternative systems of medicine in many developed countries. One-third of American adults have used alternative treatment and 60% of the public in the Netherlands and Belgium, and 74% in the United Kingdom are in favour of complementary medicine being available within the framework of the National Health Service. A survey among Member States of the European Union in 1991, identified about 1400 herbal drugs used in the European Economic Community (Richter, 2003).

2.1.2Traditional medicine in Africa

Modern science has, in the past, considered methods of traditional knowledge as primitive and backward (Agrawal, 1995). Under colonial rule, traditional diviner-healers were outlawed because they were considered by many nations to be practitioners of witchcraft and declared illegal by the colonial authorities, creating a war against witchcraft and magic. During this time, attempts were also made to control the sale of herbal medicines (Helwig, 2010). After Mozambique obtained independence in 1975, attempts to control

traditional medicine went as far as sending diviner-healers to re-education camps. As colonialism and Christianity spread through Africa, colonialists built general hospitals and Christian missionaries built private ones, with the hopes of making headway against widespread diseases. Little was done to investigate the legitimacy of these practices, as many foreigners believed that the native medical practices were pagan and superstitious and could only be suitably fixed by inheriting Western methods (Ubani, 2011). During times of conflict, opposition has been particularly vehement as people are more likely to call on the supernatural realm (Helwig, 2010). Consequently, doctors and health practitioners have, in most cases, continued to shun traditional practitioners despite their contribution to meeting the basic health needs of the population (Willian, 1999).

In recent years, the treatments and remedies used in traditional African medicine have gained more appreciation from researchers in Western science. Developing countries have begun to realize the high costs of modern health care systems and the technologies that are required, thus proving Africa's dependence to it (Agrawal, 1995). Due to this, interest has recently been expressed in integrating traditional African medicine into the continent's national health care systems (Helwig, 2010). An African healer embraced this concept by making a 48-bed hospital, the first of its kind, in Kwa-Mhlanga, South Africa, which combines traditional methods with homeopathy, iridology, and other Western healing methods, even including some traditional Asian medicine(Chin, 2000). However, the highly sophisticated technology involved in modern medicine, which is beginning to integrate into Africa's health care system, could possibly destroy Africa's deep-seated cultural values (Ubani, 2011).

Traditional African medicine is a holistic discipline involving indigenous herbalism and African spirituality, typically involving diviners, midwives, and herbalists. Practitioners of traditional African medicine claim to be able to cure various and diverse conditions such as cancers, psychiatric disorders, high blood pressure, cholera, most venereal diseases, epilepsy, asthma, eczema, fever, anxiety, depression, benign prostatic hyperplasia, urinary tract infections, gout, and healing of wounds and burns (Helwig, 2010).

Diagnosis is reached through spiritual means and a treatment is prescribed, usually consisting of an herbal remedy that has not only healing abilities, but symbolic and spiritual significance. Traditional African medicine, with its belief that illness is not derived from chance occurrences, but through spiritual or social imbalance, differs greatly from Western medicine, which is technically and analytically based. In the 21st century, modern pharmaceuticals and medical procedures remain inaccessible to large numbers of African people due to their relatively high cost and concentration of health centres in urban centres. In recent years, African medical practitioners have acknowledged that they have much to learn from traditional medical practice(Ubani, 2011).

2.1.3 Traditional medicine in Nigeria

Health is the most precious of all things and it is the foundation of all happiness. Traditional medicine has developed in various communities in Nigeria in response to the health needs of the people. Many communities have, therefore, since creation, developed various traditional systems using locally-available resources for the alleviation of their health problems. As once noted some 13 years ago (Tella, 1986), traditional medicine is as old as the hills in Nigeria. The development of traditional medicine in Nigeria has led to

various categories of healers, the various healing methods, strategies and medicines or remedies now known. The British colonial masters brought in orthodox medicine and, today, both systems of medicine exist in the country; both have the primary objective to cure, manage or prevent diseases and maintain good health(Last and Chavunduka, 1986).

It is important to stress the relevance of traditional medicine to the majority of Nigerians. Most Nigerians, especially those living in rural communities don't have access to orthodox medicine and it is estimated that about 75 per cent of the populace still prefer to solve their health problems consulting traditional healers. Where such access exists, the rising cost of imported medications and other commodities used for medicines have posed a big problem. Besides, many rural communities have great faith in traditional medicine, particularly the inexplicable aspects as they believe that it is the wisdom of their fore-fathers which also recognises their socio-cultural and religious background which orthodox medicine seems to neglect (Adesina, 2013).

2.1.4 Zootherapy

The World Health Organization (WHO) estimates that as many as 80% of the world's more than six billion people rely primarily on animal and plant-based medicines (WHO, 1993). Traditional human populations have a broad natural pharmacopoeia consisting of wild plant and animal species. Ingredients sourced from wild plants and animals are not only used in traditional medicines, but are also increasingly valued as raw materials in the preparation of modern medicines and herbal preparations (Kang and Phipps, 2003).

Animals products derived from different organs of their bodies have constituted part of the inventory of medicinal substances used in various cultures since ancient times (Lev, 2003;

Adeola, 1992). Such uses still exist in traditional medicine. The healing of human ailments by using therapeutics based on medicines obtained from animals or ultimately derived from them is known as zootherapy (Costa-Neto, 2005). As Marques (1994) states, "all human culture which presents a structured medical system will utilize animals as medicines". The phenomenon of zootherapy is marked both by a broad geographical distribution and very deep historical origins.

In modern societies, zootherapy constitutes an important alternative among many other known therapies practiced worldwide. Wild and domestic animals and their by-products (*e.g*., hooves, skins, bones, feathers, tusks) form important ingredients in the preparation of curative, protective and preventive medicine (Adeola, 1992; Anagelett*i et al.*, 1992). For example, in Traditional Chinese Medicine (TCM), more than 1500 animal species have been recorded to be of some medicinal use. In India nearly 15–20 percent of the Ayurvedic medicine is based on animal-derived substances (Unnikrishnan, 1998). In Bahia State, in the northeast of Brazil, over 180 medicinal animals have been recorded (Costa-Neto, 2004).

There are many reasons why studies on the use of animals, integrally or in parts, as medicines and their implications should be carried out and recorded. Among several approaches to be considered are the ecological, cultural (traditional knowledge), economical, and sanitary aspects of zootherapy (Alves and Rosa, 2005).

Despite their importance, studies on the therapeutic uses of animals and their body parts have been neglected, when compared to plants (Solovan*et al*., 2004). Scholarly investigation of studies on medicinal uses of animals and their products, as well as of

inorganic materials, should not be neglected and should be considered as an important complementary body of knowledge (Lev, 2003).

The extensive practice of traditional medicine in developing countries and the rapidly growing demand for alternative and basic therapeutic means (also in industrialized countries) constitute the international relevancy of research and development in the field of traditional drugs (Labadie, 1986). An additional motivation for such activities is found in the practical necessity to integrate the potential of traditional medicine into current practices of modern health care (Labadie, 1986). Some traditional medicinal systems, like the Chinese Traditional Medicine, is recognized by the World Health Organization (Alves and Rosa, 2005) and accepted by one-fourth of the world human population.

There are numerous reasons to urgently re-think the medicinal use of animal products in traditional medicine both in humans and animals. In doing this, we should particularly take into account the rarity of some species, the unnecessary suffering involved in the harvesting (e.g., hunting, fishing) process, and the possible health risks linked to the administration of the animal-based remedies. A growing respect for traditional knowledge has led modern science to adapt its procedures, for assessing the impact of development projects on biological diversity, for monitoring of ecosystems, species, particular genetic resources and species at risk, for controlling alien species, and for promoting the in-situ conservation and sustainable management of biological diversity generally (Cambray, 2003). The use of animals for medicinal purposes is part of a body of traditional knowledge which is increasingly becoming more relevant to discussions on conservation

biology, public health policies, and sustainable management of natural resources, biological prospection, and patents (Alves and Rosa, 2005).

2.2 White Grubs

White grubs are the larval stage of various types of beetles belong toPhylum: Arthropoda; Class: Hexapoda (Insecta); Order: Coleoptera; Family: Scarabaeidae. They are found in turf lawns and can cause damage to the lawn by feeding on the root system (Brian, 2013). Several names are applied to immature *phyllophaga* species; white grubs, grub worms or simply worms (Watschke*et al*., 1995). White grub is generally a term given to the larval stage of a group of over 200 species of scarab beetle. White grubs among Hausa – Fulani arecollectively called "Gwazarma or Doli – doli" (Alhassan*et al.*, 2009).Pupa is white to yellowish in the early stages and gradually become brown. Its length varies from 20 to 24mm long.

Larvae are cream colored scarabs with a tan head capsule and dark internal markings on the end of the abdomen. Six true legs are easily seen on the thorax(McLeod, 2003).Freshly laid eggs are oval, white, about 2mm long and 2mm wide. After 3-4days, eggs become spherical and smooth and are about 2mm in diameter. Mature eggs are brownish-black with diameter of about 4mm.

2.2.1 Adult

Adult descriptions vary greatly but the most common is referred to as the May beetle. The adults are commonly found at lights during late spring and summer nights (Ortega, 1987). Adult May beetles are about 12 to 25mm long. They are often reddish brown to black,

robust, oblong, shining beetle. Some such as green june beetle, are more brightly coloured (Hill, 2008). Adult beetles differ considerably in colour, markings, shape, and size. Japanese beetle adults are brilliant metallic green, 3/8 to ½ inch (9-13mm) long, bearing coppery brown wing covers with five lateral spots with white hairs on each side of the abdomen and short gray hairs covering the underside of the insect. Northern mask chafer adults are chestnut brown, covered with the fine hairs, resemble small june beetles, and are roughly ½ inch (13mm) long. Likewise, the adult have dark chocolate brown heads that shade to a light brown (masked appearance)(Hill, 2008).

The body of *P. ephilida* (Say) is slightly cylindrical, elongate and rufotestaceous (Luginbill and Painter, 1953). Characteristic teeth-like structures on the outer margins of the tibia of the front legs enable the oval bodied, stout beetles to burrow into the soil (Potter, 1998). The head and thorax are commonly darker than the remaining parts of the body. The body surface of *P. ephilida* moderately reflects light, giving it a shiny appearance (plate 1). The criteria for identification of adults are often general and superficial: size, coloration, feeding habits and periods of adult activity (Potter, 1998).

2.2.2 Larvae

Length varies from about 2-3mm in length, when young, to 20-45mm, when mature.The larval stage has three instars. All *Phyllophaga*larvae are characterized by a broad Y-shaped anus with conspicuous rows of bristles around the anal slit (Watschke*et al.,* 1995).

Larvae are white with C-shape body, brown head with six well developed legs, with exception of green june beetle grubs, which do not have well developed legs. The size of



Plate I: Adult May/ June beetle (*Phyllophagaephilida*)

White grubs vary with the species and its age. Full grown third instar Japanese beetle and northern masked chafer grubs average slightly over one inch in length. The posterior (hind) portion of the abdomen of the larvae appears darker against the lighter colour of the anterior portion of the abdomen due to the soil particles showing through the transparent body wall (Tashiro, 1987).

2.2.3 Distribution and life history

According to Shetlar (2012), White grubs are distributed throughout the World, but the species composition varies from one area to another. The life cycle usually takes three years to complete. The general life cycle is as follows: eggs are laid in the soil and hatch into larvae in three to four weeks. Young larvae feed the first season on decaying and living vegetable matter in the soil. As winter approaches, they burrow 20 to 55cm deep in the soil and remain inactive until spring when they return to near the surface and begin feeding on roots of plants. In the fall, larvae again burrow into the soil to overwinter, returning to near the surface in the spring, and feeding on plant roots until late May and June when pupation occurs(Hodgson, 2007). Adults are formed six to eight weeks later, but remain in the pupa cell until the following April and May when they emerge from the soil. Adults feed on plant foliage and lay eggs in the soil in June and early July (Ralph, 1998).

The life cycle of *Phyllophaga* species may require 1 to 4 years to complete, depending on species and geographic location. Species with 2 and 3-years life cycles are common, and due to multiple species and overlapping broods, all life stages may occur during any given year at a particular location. Adults emerge from the ground in the evenings (typically in

May and June) and move to the foliage of nearby trees or other vegetation to mate and feed. At dawn, mated females return the soil and lay eggs at depths of 3 to 20cm (1.2 to 8.0 in) beneath the surface. Larvae hatch within 2 to 3 weeks and begin to feed, first on soil organic matter and eventually on nearby seedling roots. In autumn, larvae migrate downward to depths of up to 1.5 m (5 ft), depending on temperature, frost levels, and soil characteristics, and remain inactive until spring, when they return to near the soil surface to feed again on roots. Larvae may repeat these patterns of root-feeding in the warm season and downward migration to overwinter for 1 or more years. When larvae are fully mature they pupate in earthen cells and later emerge as adults (Selman, 2008).

2.2.4 Species identification

Grub identification is important because there are multiple species present all over the world and these species differ in life cycle and damage. Most species have a single-year (annual) life cycle, with only one generation per year, but some June beetles have a multi-year life cycle. Annual grubs stop feeding in the spring, and may be avoided by adjusting planting time, but a field infested with June beetle may be infested for several seasons. Some grubs pupate earlier in the season (European chafer) than others (Japanese beetle). Adults of the different species also differ in behavior and damage. European chafer beetles are a nuisance around lights, but do not feed. In contrast, Japanese and Asiatic garden beetles do feed and cause damage in the adult stage(King, 1984).

Larval structures sometimes utilized in their identification are the epipharynx, the rastral characters (Riley, 1988) and the mouthparts (Crocker *et al*., 1995). In general, the grubs of *Phyllophaga*are identified painstakingly (Flanders *et al*., 2000). The rastral pattern is like

a'fingerprint' on the underside of the last segment of the abdomen before the anus (Potter, 1998). This rastral pattern is made of an arrangement of small hairs and spines (Liskey, 1995).

Grubs are naturally C-shaped, and it is sometimes difficult to make them lay flat. Unfortunately, important characters for identification are on the butt-end of the grub (Figure 1). These include the shape of the anal slit(the anal opening of the insect) and the raster pattern(pattern of hairs and spines in front of the anal slit). The easiest way to view the anal slit and raster pattern is to cut off the end of the grub and put it upright in a dish of water or alcohol. It is important to keep the specimen intact, by setting the dead grub in a small dish of fine sand (such as play-ground sand)(Fisher *et al.*, 1903).

2.2.5 Economic importance

Larvae feed on roots of potatoes, grasses, corn, small fruits, and tree fruits as well as on ornamental plants such as rose, ash, elm, walnut, poplar, oak, and locust. Larval injury to tubers and roots severely weakens or kills the plant and reduces the economic value of tubers. Adults feed on the foliage of plants (Ralph, 1998).In Northern Nigeria, white grub among Hausa – Fulani is called “Gwazarma or Doli – doli” and is used in the treatment of jaundice, fever and general body weakness, and as food ingredient by various communities (Alhassan*et al.*, 2009).However, Alhassan and Sule (2011) reported that the mineral contents of white grub in terms of relative concentration was found to be in rank of K > Mg > Na >Ca>Mn> Zn > Fe > Cu. These elements were found in appreciable amount to meet nutritional requirements and therefore, could be nutritionally and medically relevant.

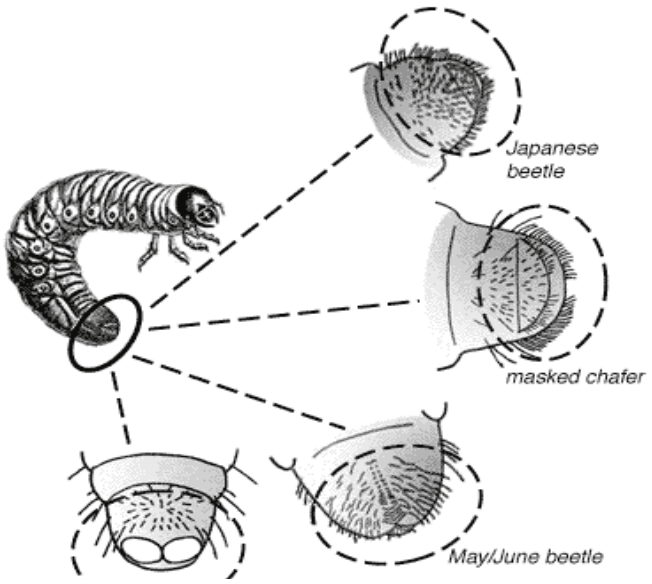

Figure a: Identification of White grubs (*Phyllophagaephilida*) Source: Hogson, E. (2007)

Anal slit: Y-shaped; Raster pattern: rows of spines

2.2.6 Chemical content of white grubs

Alhassan and Sule (2011) reported the percentage of humic substances (fulvic acid, humic acid and humin) in white grubs (WG). WG contains 16.05 ± 4.28% fulvic acid, 9.50 ± 2.06% humic acid and 74. 65 ± 11.31% humin.Humin has the highest percentage followed by fulvic acid and humic acid. Similarly the presence of mineral elements (Pb, Zn, Fe, Cu, Cr, Na, K, Ca, Co, Mn, and Mg) from white grubs was confirmed by Alhassan and Sule (2011). White grubs obtain these humic substances and mineral elements from the environmental waste.

Biologically derived compounds known as humic and fulvic acids are vital to life, Fulvic acids enter all life processes within plants and animals and function in different ways. When necessary they act as free radical scavengers, supply vital electrolytes, enhance and transport nutrients, make water wetter, catalyze enzyme reactions, increase assimilation, stimulate metabolism, chelate essential major and trace elements making them organic and demonstrate amazing capacity from electrochemical balance (Senesi, 1990). In addition fulvic acid stimulates metabolism, give positive effect on RNA and DNA, act as a catalyst in respiration, increase, metabolism of proteins, increase activities of multiple enzyme enhances the permiabilty of cell membranes, enhances cell division and cell elongation, contributes electrochemical balance as a donor or an acceptor, synthesize new minerals, chemically weather inorganic substances, decompose silica to release essential mineral nutrients and detoxify various pollutants (Pesticides, herbicides etc) (Jackson and Jackson, 1993). The effectiveness of fulvic acid as an anti-inflammatory agent and as a coagulants is nowhere less efficient compared with various anti-bacteria agents, antibiotics or other blood coagulants. Contrary to other anti-inflammatory drugs, fulvic acid does not have any

side effects and in many cases is actually superior in effectiveness (Jiangxi, 1993). It was found that humic administered prophylactically to rats decrease significantly the extension of gastric damage induced by ethanol (Brozozowski*et al.*, 1994). Pflug and Ziechman (1982) reported that humic acids are able to interact with the bacterium *Micrococcus luteus*, in this case humic materials protected the organism against cell-wall disruption by the enzyme lysozyme.

The elements present in white grubs as reported by Alhassan and Sule (2011) may have medicinal value. Lead (Pb) has no biological role in the body but it is toxic in cumulative way.The toxic effect of lead due to the use of white grubs for one reason or the other may not be possible because of the fact that it was found to be strongly bonded to humic substances found in the white grubs, hence making it less available in free form (Alhassan*et al.*, 2009). Over 300 different enzymes depend on zinc for their ability to catalyze vital chemical reactions, zinc dependent enzymes can be found in all known classes of enzyme (McCall *et al.*, 2000). Zinc plays important role in wound healing, structure of proteins and cell membranes. A finger-like structure known as zinc motif stabilizes the structure of a number of proteins for example copper provides the catalytic activity for the antioxidant enzyme copper-zinc superoxide dismutase (CuZnSOD), while zinc plays a critical structural role (King and Cousin, 2006). The structure and function of cell membranes are also affected by zinc (O' Dell, 2000). Iron is needed for a number of highly complex processes that continuously take place on a molecular level and that are indispensable to human life, example transportation of oxygen, production of red blood cells (a process known as haematoporesis), and conversion of blood sugar to energy. Iron

also involved in the production of enzymes (which play a vital role in the production of new cells, amino acids, hormones and neurotransmitters) this aspect become crucial during the recovery processes from illnesses (Nelson, 2004). Copper is essential in maintenance of healthy skin and connective tissues, wound healing, structural integrity and functions of heart and blood vessels, proper structure and function of circulating blood cells etc (Uriu-Adams and Keen, 2005). A biologically active form of chromium participates in glucose metabolism by enhancing the effects of insulin (Richard, 2007). The body needs a small amount of sodium to help maintain normal blood pressure and normal function of muscles and nerves, sodium is the major positive ion (cation) in fluid outside of cells. Potassium is a major positive ion (cation) found inside of cells. Potassium is crucial to cardiovascular and nerve function, it also releases energy from protein, fat and carbohydrates during metabolic processes, and it enhances the muscle control, the growth and health of cells (Elson, 2011). The body needs calcium to maintain strong bones although the amount of calcium outside bones and teeth is relatively small, it is required for a number of basic regulatory functions such as: contraction and relaxation of muscle (including normal heart beat), coagulation of blood, transmission of nerve impulses, activation of enzyme reactions, integrity of intracellular cement substances (Balch, 2006). Cobalt as part of B_{12} is used to prevent anaemia particularly pernicious anemia and is essential to red blood cell formation and also helpful to other cells (Elson 2011). Manganese plays an important role in a number of physiological processes as a constituent of multiple enzymes and an activator of other enzymes (Nelsen, 1999). Wound healing is a complex process that requires increased production of collagen. Manganese required for activation of prolidase, an enzyme that function to provide amino acid, proline, for collagen formation in human

skin cells (Muszynska, 2000). Magnesium is involved in more than 300 essential metabolic reactions (Gums, 2004) which include energy production; magnesium is required by adenosine triphosphate (ATP) synthesizing protein in mitochondria. ATP the molecule that provide energy for almost all metabolic processes exists primarily as a complex with magnesium (MgATP) (Rude and Shill, 2006), other functions include synthesis of essential molecules , structural role (in bone, cell membrane and chromosomes), ion transport across cell membrane, cell signaling etc.

2.3 Liver

The liver is situated on the upper right side of the abdomen, just below the diaphragm. It is The largest internal organ of mammalian body and in human body weighed around 1.5kg average adult (Ronzio, 2003).

2.3.1 Functions of the liver

The liver regulates most chemical levels in the blood, which helps carry away waste products from the liver. All the blood leaving the stomach and intestines passes through the liver. The liver processes the blood and breaks down the nutrients and drugs into forms that are easier to use for the rest of the body. More than 500 vital functions have been ascribedto the liver.

When the liver has broken down harmful substances, its by-products are excreted into the bile or blood. Bile by-products enter the intestine and ultimately leave the body in the form of feces. Blood by-products are filtered out by the kidneys, and leave the body in the form of urine (Tanaka*et al.*, 1978).

2.3.2 Anatomy of liver

The liver is roughly triangular organ that extends across the entire abdominal cavity just inferior to the diaphragm. Most of the liver's mass is located on the right side of the body where it descends inferiorly toward the right kidney. The liver is made of very soft pinkish-brown tissues encapsulated by a connective tissue capsule. This capsule is further covered and reinforced by the peritoneum of the abdominal cavity, which protects the liver and holds it in place within the abdomen. The peritoneum connects the liver in four locations: the coronary ligament, the left and right triangular ligaments, and the falciform ligament. These connections are not true ligaments in the anatomical sense; rather, they are condensed regions of peritoneal membrane that support the liver.The white coronary ligament connects the central superior portion of the liver to the diaphragm. Located on the lateral borders of the left and right lobes, respectively, the left and right triangular ligaments connect the superior ends of the liver, to the diaphragm.The falciform ligament runs inferiorly from the diaphragm across anterior edge of the liver to its inferior border. At the inferior end of the liver, the falciform ligament forms the round ligament ligamentumteres) of the liver and connects the liver to the umbilicus. The round ligament is a remnant of the umbilical vein that carries blood in to the body during fetal development (Taylor, 2013).

The liver consists of four distinct lobes- the left, right, caudate, and quadrate lobes (Taylor, 2013).

- The left and right lobes are the largest lobes and are separated by the falciform ligament

- The right lobe is about 5 to 6 larger than the tapered left lobe.
- The small caudate lobes extend from the posterior side of the right lobe and wraps around the inferior vena cava.
- The small quadrate lobe is inferior to the caudate lobe and extends from the posterior side of Right lobe and wraps around the gallbladder.

2.3.3 Bile duct, blood vessels and lobules

The tubule that carry bile through the liver and gall bladder are known as bile ducts and form a branched structure known as bile canaliculi. The countless bile canaliculi join together in to many larger bile ducts found throughout the liver. These bile ducts next join to form the larger left and right hepatic ducts, Which carry bile from the left and right lobes of the liver. Those two hepatic ducts joint to form the common hepatic duct that drains all bile away from the liver. The common hepatic duct finally joins with the cystic duct from the gallbladder to form the common bile duct, carrying bile to the duodenum of the small intestine. Most of the bile produced by the liver is pushed back up the cystic duct by peristalsis to arrive in the gallbladder for storage, until it is needed for digestion (Paul, 2012).

The blood supply of the liver is unique among all organs of the body due to the hepatic portal vein system. Blood travelling to the spleen, stomach, pancreas, gallbladder, and intestines passes through capillaries in these organs and is collected in to the hepatic portal vein. The hepatic portal veins then delivers this blood to the tissues of the liver where the contents of the blood are divided up in to smaller vessels and processed before being passed on the rest of the body. Blood leaving the tissues of the liver collects in to the

hepatic veins that lead to the vena cava and return to the heart. The liver also has its own system of arteries and arterioles that provide oxygenated blood to its tissues just like any other organs(Tortora and Derrickson, 2008).

The internal structure of the liver is made up of around 100,000 small hexagonal functional units known as lobules. Each lobule consists of a central vein surrounded by 6 hepatic portal veins and 6 hepatic arteries. These blood vessels are connected by many capillary-like tubes called sinusoids, which extend from the portal veins and arteries to meet central vein like spokes on a wheel (Kleinsek and Soto, 2010).

Each sinusoid passes through liver tissue containing two main cell types: Kupffer cell and hepatocytes.

- *Kupffer cells* are a type of macrophages that capture and breakdown old, worn out red blood cells passing through the sinusoids.
- *Hepatocytes* are cuboidal epithelial cell that line the sinusoids and make up the majority of cells

In the liver Hepatocytes perform most of the liver's function- metabolism, storage, digestion, and bile production. Tiny bile collection vessels known as canaliculi run parallel to the sinusoids on the other side of the hepatocytes and drain in to the bile ducts of the liver (Kleinsek and Soto, 2010).

2.3.4 Physiology of the liver

2.3.5 Detoxification

As blood from the digestive organs passes through the hepatic portal circulation the hepatocytes of the liver monitor the contents of the blood and remove many potential toxic substances before they can reach the rest of the body. Enzymes in hepatocytes metabolize many of these toxins such as alcohol and drugs into their inactive metabolites. And in order to keep hormone levels within homeostatic limits, the liver also metabolizes and remove from circulation hormones produced by the body own glands (Wicks, 1998).

2.4 Stages of Liver Toxicity

2.4.1 Fatty liver and inflammation

Fatty liver, also known as steatorrhoeichepatosis, is the build-up of excess fat in the liver cells. It is normal for the liver to contain some fat. But, if fat accounts for more than 10% of the liver's weight, the individual has fatty liver. In countries where obesity is becoming a serious health issue, fatty liver is predicted to affect approximately 25% of the general population. Fatty liver occurs before inflammation is present. Sometimes, inflammation from a fatty liver is linked to alcohol abuse, known as alcoholic steatohepatitis. Otherwise the condition is called nonalcoholic steatohepatitis, or NASH. NASH is very common in overweight persons over the age of 30. The liver is invaded by an excessive amount of fat and a normal healthy liver tissue is partially replaced with areas of unhealthy fats. In such a liver, the liver cells and the spaces in the liver are filled with fat so that the liver becomes slightly enlarged and heavier (James, 2013).

Hepatitis is an inflammation of the liver that can be caused by viruses, chemicals, drugs, alcohol, inherited diseases, or the individual's own immune system. This inflammation can be acute (short-term), flaring up and then resolving within a few weeks to months, or chronic (long-term), lasting many years. Chronic hepatitis may begin to damage the liver for 20 years or more before causing significant symptoms related to progressive liver damage such as cirrhosis (scarring and loss of function), liver cancer, or death. In the early stage of any liver disease, the liver may become inflamed, tender, and enlarged. However, an inflamed liver may cause no discomfort at all (Schiff *et al.*, 2007).

2.4.2 Fibrosis

If left untreated, the inflamed liver will start to scar. As excess scar tissue (a type of fibrous tissue) grows, it replaces healthy liver tissue. This process is called fibrosis. Scar tissue cannot function as healthy liver tissue can. Scar tissue may keep blood from flowing through the liver. The healthy part of the liver now has to work harder. The liver can regenerate, however, and may heal itself from fibrosis (Pietrangelo, 2004).

2.4.3 Cirrhosis

The liver may become so seriously scarred that it can no longer heal itself if left untreated. This stage, when the damage cannot be reversed, is called cirrhosis. Cirrhosis can lead to a number of complications, including liver cancer. In some individuals, the symptoms of cirrhosis may be the first signs of liver disease. Symptoms of cirrhosis include: easy bruising; fluid buildup in the legs and/or abdomen; the skin and eyes may take on a yellow color, a condition called jaundice; the skin may itch intensely; blood may back up in

vessels leading to the liver because of blockage and may burst; increased sensitivity to medications and their side effects; developing insulin resistance and type-2 diabetes; or buildup of toxins in the brain, causing problems with concentration, memory, sleeping, or other mental functions(James, 2013).

2.4.4 Liver failure

Liver failure means that the liver is losing or has lost all of its function. It is a life-threatening condition that demands urgent medical care. The first symptoms of liver failure are often nausea, loss of appetite, fatigue, and diarrhea. Because these symptoms can have any number of causes, it may be hard to tell that the liver is failing. As liver failure progresses, the symptoms become more serious. The individual may become confused and disoriented, and extremely sleepy. There is a risk of coma and death. Immediate treatment is needed. The medical team will try to save whatever part of the liver that still works. If this is not possible, the only option may be a liver transplant (Ala*et al.*, 2007).

2.5 Types and Causes of Liver Toxicity

2.5.1 Hepatitis

Hepatitis is a condition that impairs liver function either temporarily or permanently, sometimes leading to death. It can be initiated by a host of factors but primarily by viruses. Drugs also can cause hepatitis. However, when the specific drug is discontinued, the liver usually returns to normal(Schiff *et al.*, 2007).

2.5.2 Effects of drug

The liver is responsible for the metabolism of alcohol, drugs, and environmental toxins. It breaks them down into substances that can be used and then excreted by the body. Some

drugs may cause serious injuries to the livers of patients who take them. Injuries can lead to a loss of function leading to illness, disability, hospitalization, and even life threatening liver failure and death(Kalant, 2001).

Many prescription and non-prescription drugs have the potential to cause hepatitis in people, in a seemingly random fashion. The effect of drugs cannot be foreseen and the causes are unknown, although drug-induced hepatitis rarely appears to be related to an allergic reaction to the medication. Drugs that have had this effect in some people include anesthetics, antibiotics, anabolic steroids, and seizure medications. In the United States, drug-induced liver injury (DILI) is now the leading cause of acute liver failure (ALF), exceeding all other causes combined (Charmaz, 1991).

Acetaminophen, which is found in many over-the-counter (OTC) and prescription medications, is an example of this. In therapeutic doses, acetaminophen is a useful pain reliever, but in very high dosages or in combination with alcohol, it has the potential to cause life-threatening acute liver failure. Acetaminophen produces toxic byproducts that the liver usually detoxifies by coupling them with other compounds and flushing them out through the bileAn estimated 500 deaths per year are attributed to suicidal or unintentional overdoses of acetaminophen (Tylenol©) as well as more than 50,000 emergency room visits. This is the most common form of acute liver failure observed in the United States. While some are intentional, at least 50% of these are unintentional; the individual is consuming more than one product containing acetaminophen or simply using doses more than suggested by the package insert (Pitt and Hocking, 1997).

2.5.3 Alcohol

The liver can metabolize only a certain amount of alcohol per hour, regardless of the amount that has been consumed. The rate of alcohol metabolism depends, in part, on the amount of metabolizing enzymes in the liver, which varies among individuals. In general, after the consumption of one standard drink, the amount of alcohol in the drinker's blood peaks within 30-45 minutes. A standard drink is defined as 12 ounces of beer, 5 ounces of wine, or 1.5 ounces of 80-proof distilled spirits, all of which contain the same amount of alcohol. Alcohol is metabolized more slowly than it is absorbed. Since the metabolism of alcohol is slow, consumption needs to be controlled to prevent accumulation in the body and further intoxication. Excessive consumption of alcohol is toxic to the liver and is one of the most common causes of chemical hepatitis. Alcohol intake causes the body to overproduce an enzyme that boosts these byproducts further, while compromising the detoxification. Cirrhosis (replacement of normal tissue with scar tissue) of the liver, pancreatitis (inflammation of the pancreas), and damage to the brain and heart occur after years of heavy alcohol abuse. Heavy drinkers also are at risk of malnutrition because alcohol contains calories that may substitute for those in nutritious foods(Lieber, 1985).

2.6 Carbon tetrachloride

Carbon tetrachloride is a clear heavy organic liquid with a sweet aromatic odor similar to chloroform (Hall, 1996).

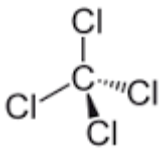

2.6.1 Metabolism

Carbon tetrachloride is readily absorbed after ingestion and inhalation, but more slowly through the skin (Spero*et al.*, 2000). Following systemic absorption in animals, carbon tetrachloride is distributed to the major organs with highest concentrations measured in the fat, liver, brain, spinal cord, blood, bone marrow, adrenals and kidney. No studies on distribution were carried out in humans (Shahjahan*et al.*, 2004). Absorbed carbon tetrachloride can be metabolised by cytochrome P450 enzymes leading to the formation of the reactive trichloromethyl radical. This undergoes oxidative biotransformation to form the highly reactive trichloromethylperoxy radical which may decompose to form phosgene. Phosgene may be detoxified by reacting with water, to form carbon dioxide, or with glutathione or cysteine (Shahjahan*et al.*, 2004; Spero*et al.*, 2000). Few data on the elimination of carbon tetrachloride in humans were identified. Animal studies have shown that around 34-75% of absorbed carbon tetrachloride leaves the body in expired air; 20-60% leaves the body in faeces and relatively low amounts in the urine (Shahjahan*et al.*, 2004). Animal studies have also suggested that it may take weeks for the remainder of the chemical to be eliminated, especially the fraction that has entered body fat (Shahjahan*et al.*, 2004).

The first report about hepatotoxic effects by CCl_4 is lipid peroxidation origin, and is largely due to its active metabolite CCl_3 (this metabolite can abstract hydrogen from fatty acids, initiating the lipid peroxidation) lead to cell injury and eventually liver damage (Mahajan, 2006). The hepatocytes of the liver are the main components that regulate various metabolic activities that support body cell. Damage of this organ will result in

disorder of body metabolism (Reece, 2009). Induced carbon tetrachloride can be metabolized by cytochrome CYP450 enzymes leading to the formation of the reactive trichloromethyl radical. This undergoes oxidative biotransformation to form the highly reactive trichloromethylperoxy radical which may decompose to form phosgene. Phosgene may be detoxified by reacting with water, to form carbon dioxide, or with glutathione or cysteine (Spero*et al.*, 2000). Reacting with glutathione will lead to its depletion in the liver and the blood; this process can result into mitochondrion dysfunction, increase of lipid peroxidation, and development of acute hepatic necrosis. Hepatocellular necrosis releases the enzymes such as AST and ALT into the circulation (Shnoy, 2002) and hence it can be measured in serum (Rajkapoor, 2008).

2.6.2 General toxicity

Acute exposure to carbon tetrachloride via any route of exposure can cause gastrointestinal and neurological effects in the first 24 hours, such as, vomiting, diarrhoea, headache, dizziness, depression of conscious level and dyspnoea. The liver and kidney are the major target organs for toxicity following acute inhalation or ingestion exposure to carbon tetrachloride (Spero*et al.*,2000; Proctor *et al.*,2004). Liver damage can occur after 24 hours and in serious cases this can result in painful swollen liver, haemorrage, hepatic coma and death (Shahjahan*et al.*, 2004). Kidney damage with impairment in function normally occurs 2-3 weeks after exposure (Spero*et al.*, 2000), but in severe cases this can occur within 1-6 days in association with liver failure (Shahjahan*et al.*, 2004). Adverse effects on the liver can be markedly increased by the co-ingestion of alcohol (Borak and Diller,

2001), due to hepatic enzyme induction which results in increased production of toxic metabolites (Shahjahan*et al.*, 2004).

In mice given carbon tetrachloride in corn oil 5 days a week for 90 days, changes in serum levels of liver enzymes were seen at 12mg/kgbw/day and above, together with histopathological evidence of liver damage (fatty infiltration and necrosis). Similar to the previous study, no effects were seen at 1.2mg/kgbw/day (Bruckner *et al.*, 1986).

Carbon tetrachloride caused tumors in several species of experimental animals, at two different tissue sites, and by several different routes of exposure. It caused benign or malignant liver tumors when administered orally in mice and rats of both sexes, in hamsters, and in trout, by subcutaneous injection in male rats, and by inhalation in rats (of unspecified sex) (Huff, 1999). Subcutaneous injection of carbon tetrachloride caused benign and malignant mammary-gland tumors (fibroadenoma and adenocarcinoma) in female rats (Rudel*et al.*, 2007).

2.7 Acute toxicity

Acute toxicity is usually defined as the adverse change(s) occurring immediately or a short time following a single or shortperiod of exposure to a substance or substances or as adverse effects occurring within a short time of administration of a single dose of a substance or multiple doses given within 24hrs. An adverse effect is "any effect that results in functional impairment and/or biochemical lesions that may affect the performance of the whole organism or that reduce the organ'sability to respond to an additional challenge" (Rodes and Thomas, 1993). Consequently, a chemical that enters the organism via the oral

route during a restricted time and produces anyadverse effect with little delay is orally and acutely toxic. However, the term acute oral toxicity is most often used in connection to lethality and LD_{50} determinations.

The purposes of acute toxicity testing are to obtain information on the biologicactivity of a chemical and gain insight into its mechanism of action. Long-term studies usually start with a dose-finding exercise under acute conditions. Furthermore, the information on acute systemic toxicity generated by the test is used in hazard identification and risk management in the context of production, handling, and use of chemicals (Walum, 1998).

CHAPTER THREE

3.0 MATERIALS AND METHODS

3.1 Sample Collection and Identification

White grubs (Plate II) were collected by hand picking at fenced animal herd in KukaBiyar village, Katsina Local Government, Katsina state. The grubs were identified by the presence of Y-shaped anal slit and parallel row of spines raster pattern (Hogson, 2007).

3.2 Extract Preparation

The samples were weighed using a digital balance (Metler). The Posterior(darker) Portion of the abdomen of each grub was incised to obtain the exudates into 250ml of methanol. Similarly, the anterior part of the abdomen fluid was carefully squeezed out into 125ml of methanol.The mixtures were kept for 24 hours (Maceration method). Each mixture was stirred thoroughly and filtered before heatingto dryness in a water bath at 45ºC to obtain the Posterior Methanol Extract (PME) and the Anterior Methanol Extract (AME). Each extract was preserved in airtight container and kept in desiccator at room temperature.

3.3 Experimental Animals

Albino rats weighing between 150g-200gwere obtained from the Animal house in the Department of Pharmacology and Therapeutics,Ahmadu Bello University, Zaria.The animals were kept in cleaned aluminum cages with litter removed every week. A standard procedure was observed in line with the Good Laboratory Practice (GLP) Regulations of the WHO (2008).Animals were allowed free access to food and water *ad libitum*.



Plate II: White Grubs (*Phyllophagaephilida*)

3.4 Toxicity Studies

Nine (9) Swiss albino rats weighing 150g-200g were acclimatized for a week in Pharmacology laboratory and randomly divided into 3 groups of 3 animals each. Groups 1, 2 and 3 were orally administered with 10, 100 and 1000 mg/kg body weight of theWhite grub extracts (PME or AME) (Lorke,1983), respectively. The animals were observed frequently from the day of treatment for any changes up to 14 days. Each animal was weighed, euthanized in a chloroform chamber and dissected for observation of gross pathologic changes. Organs such as the lung, kidney, spleen, liver, and heart were obtained for histopathological studies.

Based on the result of the acute toxicity test, four (4) Swiss albino ratsweighing 150-200g were divided into 4 groups of one animal each. White grubs (PME or AME) extract was orally administered at a dose of 1200, 1600, 2900 and 5000 mg/kg body weight after reconstituting the dry extract in to liquid form using distilled water. This was done by diluting 1g of the extracts in to 10ml of distilled water to form 100mg (stock solution). Mortality was monitored over a period of 24hrs. The lethal dose (LD_{50})was determined as the geometric mean of the dose that resulted in 100% mortality and that which caused no mortality at all (Lorke, 1983). The animals were observed for two weeks before they were sacrificed through cervical decapitation. The liver, heart, lungs and spleen were removed for weighing

3.5 Experimental Design

3.5.1 Administration of extracts

Experiment 1: thirty (30) albino rats were divided into five groups of six animals each. Group 1, was given 100mg/kg body weight of the posterior methanol extract (PME). Group 2, was given 50mg/kg body weight of PME. While Group 3 served as standard control in which 10mg/kg body weight of Silymarin was given. Group 4 was the toxicity control group (negative control), normal saline was given. Group 5 served as normal control and received normal saline only. All administrations were done orally.

Experiment 2: In this study the same procedure as in experiment 1 was followed with the administration of the AME.

3.5.2 Administration of carbon tetrachloride

Animals in groups 1-4 and 6-9 were given injection of 1.4 ml/kg body weight of CCl_4(1:1 in olive oil)intraperitoneally on day 2 and 3 of the experiment. On day 5 all the animals were sacrificed through cervical decapitation(Recknagel, 1983).

3.6 Estimation of Biochemical Parameters

The blood collected from the jugular veinof euthanized animals using test tube and was allowed to coagulate at 37^oC for 30 minutes. The serum was separated by centrifugation at 2,500 rpm (g) for biochemical analysis. Liver marker enzymesnamely Aspartate amino transferase (AST), Alanine amino transferase (ALT), and Alkaline phosphatase (ALP)were determined by using standard kits (ReckonDiagnosticLtd., India)

3.6.1 Aspartate aminotransferase (AST)

In this reaction, L-Aspartate and α-Ketoglutarate react in the presence of aspartate amino transferase (AST) also known as Glutamic oxaloacetatetransaminase (GOT) in the sample to yield oxaloacetate and L-glutamate. The oxaloacetate is reduced by malate dehydrogenase (MDH) to yield L-malate with the oxidation of Nicotinamide Adenine Dinucleotide phosphate (NADH) to Nicotinamide Adenine Dinucleotide (NAD). The reaction was monitored by measurement of the decrease in the absorbance of NADH at 340nm. The rate of reduction in absorbance is proportional to GOT activity in the sample. The working reagent was prepared according to Reckon diagnostics (India) procedure and is stabilized for 4months at 2-8ºC. 1.0ml of the reagent was mixed with 0.05ml of serum immediately and first absorbance was recorded at exactly 1 minute and thereafter at 30, 60, 90 and 120secs at 340nm. The test results were calculated by using the following formula (Reckon, 2013):

Serum GOT activity (IU/L) = $\Delta A/min. \times F$

Where $\Delta A/min.$ = Mean change in absorbance per minute

F = 3376 (based on the millimolar extinction coefficient of NADH at 340nm).

3.6.2 Alanine aminotransferase (ALT)

In this reaction, L-Alanine and α-Ketoglutarate react in the presence of alanine amino transferase (ALT) also known as Glutamic Pyruvic Transaminase(GPT) in the sample to yield pyruvate and L-glutamate. Pyruvate was reduced by lactate dehydrogenase to yield lactate with oxidation of NADH to NAD. The reaction was monitored by measurement of

the absorbance of NADH at 340nm. The rate of reduction is proportional to GPT activity in the sample.The working reagent was prepared according to Reckon Diagnostics procedure and is stable for 4-months at 2-8ºC. 1.0ml of the reagent was mixed with 0.05ml of serum immediately and first absorbance was recorded at exactly 1 minute and thereafter at 30, 60, 90 and 120secs at 340nm. The test results were calculated by using the following formula:

Serum GPT activity (IU/L) = ΔA/min. × F (Reckon, 2013).

Where ΔA/min. = Mean change in absorbance per minute

F = 3376 (based on the millimolar extinction coefficient of NADH at 340nm).

3.6.3 Alkaline phosphatase (ALP)

Alkaline phosphatase is a sample hydrolysis paranitrophenyl phosphate into paranitrophenol and phosphate, in the presence of magnesium ions. The rate of the increase in absorbance of the reaction mixture at 405nm due to liberation of paranitrophenol is proportional to the alkaline phosphatase activity. The working reagent was prepared according to Reckon diagnostics procedure and is stable for 21 days at 2-8ºC. 1.0ml of the reagent was mixed with 0.02ml of serum immediately and first absorbance was recorded at exactly 1 minute and thereafter at 30, 60, 90 and 120 secs at 405nm. The test results were calculated by using the following formula:

Serum ALP activity (IU/L) = ΔA/min. × F

Where ΔA/min. = Mean change in absorbance per minute

F = 2713 (Calculated on the basis of molar extinction coefficient for paranitrophenol and ratio of total assay volume to sample volume)(Reckon, 2013).

3.7 Histopathological Examination of the Liver

2-4 mm thick sections of the liver were cut and fixed in 10% formal saline for 48hrs and processed in paraffin. 5µ thick section of the paraffin-embedded liver was sectioned using a microtome. Haematoxylin and eosin was used for staining the liver sections in the following order: deparaffinized sections (slides) were downgraded through various grades of alcohol to water. The sections in haematoxylin were stained for 30 minutes, rinsed in water and differentiated in acid water until the nuclei turned pink. At this stage, the slides were dipped in the ammonia water to stain the nuclei blue. The stained sections were examined under the light microscope and photographs of the sections were taken using suitable macro-lens for histopathological examination (Galigher, 1971).

3.8DPPH Radical-Scavenging Activity

The antioxidant activity of PME of white grubs was evaluated through free radical scavenging ability of 2, 2, diphenyl-1-picrylhydrazyl (DPPH) radical (Sigma-Aldrich Co. 2013). 1.0ml of DPPH methanolic solution was added in to 2.5mls of the sample (PME and Ascorbic acid) and Ethanol (control) at various concentrations (280, 125, 50, 25, 10 and 5ug/ml). 1.0ml of ethanol was added in to 2.5mls of the extract (blank). The mixtures were mixed thoroughly and kept in dark for 30 minutes. The absorbance was measured at 518nm using spectrophotometer. Samples were measured in three replicates(Talukder, 2013).

Percentage of DPPH scavenging activity was calculated as % inhibition of DPPH = 100 – [(As – Ab/Ac) 100]. Where As is absorbance of sample; Ab is absorbance of blank; Ac is absorbance of control.

3.9 Statistical Analysis

Results were expressed in mean ± S.E.One-wayANOVA was used to determine significant difference between groups treated with different white grubs extractsthe mean separation was done using LSD at 95% confidence level.Linear regression was also used in the analysis of antioxidant activity.

CHAPTER FOUR

4.0 RESULTS

4.1 Toxicity Studies in Rats (LD_{50})

The posterior methanol extract (PME) shows the LD_{50}>5000mg/kg body weight in rats because no mortality was recorded throughout the period of the study (Table 1). Clinical signs of toxicity (initial excitement, restlessness, difficulty in breathing, loss of appetite, general weakness and depression) were not observed within the two weeks of the experiment. But there were slight changes in organs-weight ratio within columns. There was no significance difference (P □ 0.05) between organs (liver, kidneys, heart, spleen and lungs) weights in treated and control rats.

The acute lethal study of white grubs anterior methanol extract (AME) (Table 2) shows no mortality recorded within 24 hours and throughout the two weeks of the experiment. No signs of toxicity were recorded and there is no significance different in organ-weight ratio compared to the control. The lethal dose (LD_{50}) of AME was greater than 5000mg/kg body weight.

There were no significant variations between the weights of kidneys, heart, spleen and lungs of animals that received PME at different doses and their respective control groups as shown in Table 3.In Table 4, the liver weight of the control group differed significantly from the other groups even though the histopathology of the liver sections did not show any tissues damaged (Appendix I). However, there was no significant increase in weights of kidney, heart, spleen and lungs among different doses of AME and their control groups.

Table 1: Toxicity of posterior methanolicextract administered orally to rats.

Experiment	PME Doses(mg/kg)	Mortality after 24hrs	Mortality after two weeks
Phase 1	10	0/3	0/3
	100	0/3	0/3
	1000	0/3	0/3
Control	0	0/3	0/3
Phase 2	1200	0/1	0/1
	1600	0/1	0/1
	2900	0/1	0/1
	5000	0/1	0/1

The experiment was carried out in two phases. Each dose group in phase 1 comprised of three animals while phase 2 comprised 1 rat per dose group.

Table 2: Toxicity ofanterior methanolic extract administered orally to rats.

Experiment	AME Doses(mg/kg)	Mortality after 24hrs	Mortality after two weeks
Phase 1	10	0/3	0/3
	100	0/3	0/3
	1000	0/3	0/3
Control	0	0/3	0/3
Phase 2	1200	0/1	0/1
	1600	0/1	0/1
	2900	0/1	0/1
	5000	0/1	0/1

The experiment was carried out in two phases. Each dose group in phase 1 comprised of three animals while phase 2 comprised 1 rat per dose group.

Table 3: Effect of posterior methanolic extract (PME) on weight of organs of rats.

PME Dose (mg/kg)	Weight of Liver (g)	Weight of Kidneys (g)	Weight of Heart (g)	Weight of Spleen (g)	Weight of Lungs (g)
10	6.68 ± 0.62[a]	1.21 ± 0.08[a]	0.65 ± 0.07[a]	1.08 ± 0.12[a]	1.80 ± 0.30[a]
100	6.36 ± 0.66[a]	1.08 ± 0.14[a]	0.62 ± 0.04[a]	0.85 ± 0.16[a]	1.22 ± 0.26[a]
1000	6.99 ± 0.60[a]	1.19 ± 0.13[a]	0.67 ± 0.05[a]	0.84 ± 0.17[a]	1.54 ± 0.45[a]
Control	8.29 ± 0.43[a]	1.31 ± 0.08[a]	0.65 ± 0.03[a]	1.29 ± 0.19[a]	2.03 ± 0.08[a]
1200	7.91	1.31	0.73	0.55	0.70
1600	5.39	0.87	0.53	0.55	0.71
2900	6.96	0.94	0.61	0.56	0.74
5000	7.06	1.11	0.65	0.77	0.99

Values are in mean ± standard error. Groups with one rat (n < 3) were not compared.

[a]Not significantdifference ($P \leq 0.05$) when compared tocontrol within the respective column using analysis of variance.

Table 4: Effect of anterior methanolic extract onweight of organs of rats.

AME Dose (mg/kg)	Weight of Liver (g)	Weight of Kidneys (g)	Weight of Heart (g)	Weight of Spleen (g)	Weight of Lungs (g)
10	6.75 ± 0.55^{a}	1.22 ± 0.07^{ab}	0.59 ± 0.04^{a}	1.09 ± 0.11^{ab}	2.08 ± 0.08^{a}
100	6.50 ± 0.29^{a}	1.14 ± 0.05^{a}	0.68 ± 0.02^{a}	0.93 ± 0.10^{a}	1.82 ± 0.45^{a}
1000	7.31 ± 0.31^{a}	1.32 ± 0.00^{ab}	0.71 ± 0.01^{b}	0.83 ± 0.17^{a}	1.53 ± 0.45^{a}
Control	8.68 ± 0.07^{b}	1.40 ± 0.02^{b}	0.68 ± 0.02^{ab}	1.51 ± 0.04^{b}	2.08 ± 0.06^{a}
1200	5.52	0.91	0.58	0.60	0.76
1600	7.02	0.97	0.68	0.59	0.78
2900	7.01	1.08	0.62	0.74	0.96
5000	7.75	1.12	0.77	0.87	1.21

Values are in mean ± standard error. Groups with 1 rat ($n < 3$) were not compared.

4.2 Biochemical studies

In Table 5, (Group 1) (100mg/kg PME + CCl_4) treated animals show a significant elevation in levels of all serum marker enzymes tested compared to normal control (Group 5) and positive control (Group 3). Group 2 (PME 50mg/kg + CCl_4), the AST, ALT and ALP levels were not significantly elevated compared to the Silymarin group (Group 3) and Group 5 (normal control Group). Similarly, the positive control group shows no significant increase in serum AST, ALT and ALP activities. However, CCl_4 treated rats (Group 4) indicate significant increase in the level of the enzymes tested.

Similarly,in Table 6, the oral administration of high dose of AME (100mg/kg) and silymarin (10mg/kg) exhibited an ability to counter the toxic effect of CCl_4 by decreasing the levels of ALT, AST and ALP. However, the significant elevation of these enzymes were recorded in low dose (AME 50mg/kg) and CCl_4 control (Group 9). Group 10 (normal control) shows no significant elevation of the serum markers (AST, ALT and ALP).

Table 7, shows PME at a dose of 50 mg/kg b. wt. and AME at a dose of 100 mg/kg b. wt. differed significantly ($P \leq 0.05$) with CCl_4 group

4.3 Histopathological Studies

In Plate III(a), the liver section of rat treated with PME (100mg/kg b. wt.)(Group 1) shows intense vacoulation with hepatic necrosis and haemorrhage. In group 2 (50mg/kg b. wt.) the liver section shows mild vacuolation and no hepatic necrosis (Plate III(b)). The positive control (Group 3) shows section of the liver which revealed normal hepatocytes with no necrosis, no haemorrhage (Plate III(c)).

Table 5: Effect of posterior methanolic extract on enzyme activities

Treatment	Dose(mg/kg)	AST(U/L)	ALT(U/L)	ALP(U/L)
PME + CCL_4	100	92.40 ± 10.87[b]	116.80 ± 12.82[b]	116.20 ± 12.72[b]
	50	22.00 ± 5.22[a]	33.60 ± 6.70[a]	52.20 ± 3.02[a]
Silymarin (pos.)	10	22.40 ± 7.28[a]	29.80 ± 3.57[ab]	66.80 ± 5.54[a]
CCL_4 control (neg.)		100.00 ± 6.80[b]	112.00 ± 4.14[b]	130.00 ± 9.51[b]
Control	-	47.00 ± 3.08[a]	52.80 ± 4.96[a]	74.00 ± 2.92[a]

[a] differed significantly ($P \leq 0.05$) when compared tonegative control within the respective column .
[b] differed significantly ($P \leq 0.05$) when compared to normal control within the respective column

Data were analysed using one way analysis of variance and least significant difference was used for comparison of means

Normal liver enzymes range:

ALT 7-55 (U/L)

AST 8-45 (U/L)

ALP 45-115 (U/L)

Table 6: Effect of anterior methanolic extract on enzyme activities

Treatment	Dose(mg/kg)	AST(U/L)	ALT(U/L)	ALP(U/L)
AME + CCL_4	100	21.40 ± 10.67[a]	29.80 ± 10.07[a]	58.40 ± 7.77[a]
	50	82.80 ± 9.03[b]	95.20 ± 6.79[b]	96.40 ± 12.63[b]
Silymarin (pos.)	10	38.00 ± 5.97[a]	51.20 ± 7.30[a]	65.60 ± 2.42[a]
CCL_4 control (neg.)		96.20 ± 5.51[b]	110.20 ± 3.37[b]	127.00 ± 9.02[b]
Control	-	41.80 ± 9.25[a]	49.20 ± 7.44[a]	83.80 ± 8.86[a]

[a] Data significantly differed($P \leq 0.05$) from negative control group.
[b]Data significantly differed($P \leq 0.05$) from normal control group.

Data were analysed using one way analysis of variance and least significant difference was used for comparison of means

Normal liver enzymes range:

ALT 7-55 (U/L)

AST 8-45 (U/L)

ALP 45-115 (U/L)

Table 7: Effect of anterior and posterior methanolic extracts on enzymes activities

Treatment	Dose(mg/kg)	AST(U/L)	ALT(U/L)	ALP(U/L)
AME + CCL_4	100	21.40 ± 10.67[a]	29.80 ± 10.07[a]	58.40 ± 7.77[a]
	50	82.80 ± 9.03[b]	95.20 ± 6.79[b]	96.40 ± 12.63[b]
PME + CCL_4	100	92.40 ± 10.87[b]	116.80 ± 12.82[b]	116.20 ± 12.72[b]
	50	22.00 ± 5.22[a]	33.60 ± 6.70[a]	52.20 ± 3.02[a]
CCL_4 control (neg.)		96.20 ± 5.51[b]	110.20 ± 3.37[b]	127.00 ± 9.02[b]

[a] Data significantly differed($P \leq 0.05$) from negative control group.

Data were analysed using one way analysis of variance and least significant difference was used for comparison of means

Normal liver enzymes range:

ALT 7-55 (U/L)

AST 8-45 (U/L)

ALP 45-115 (U/L)

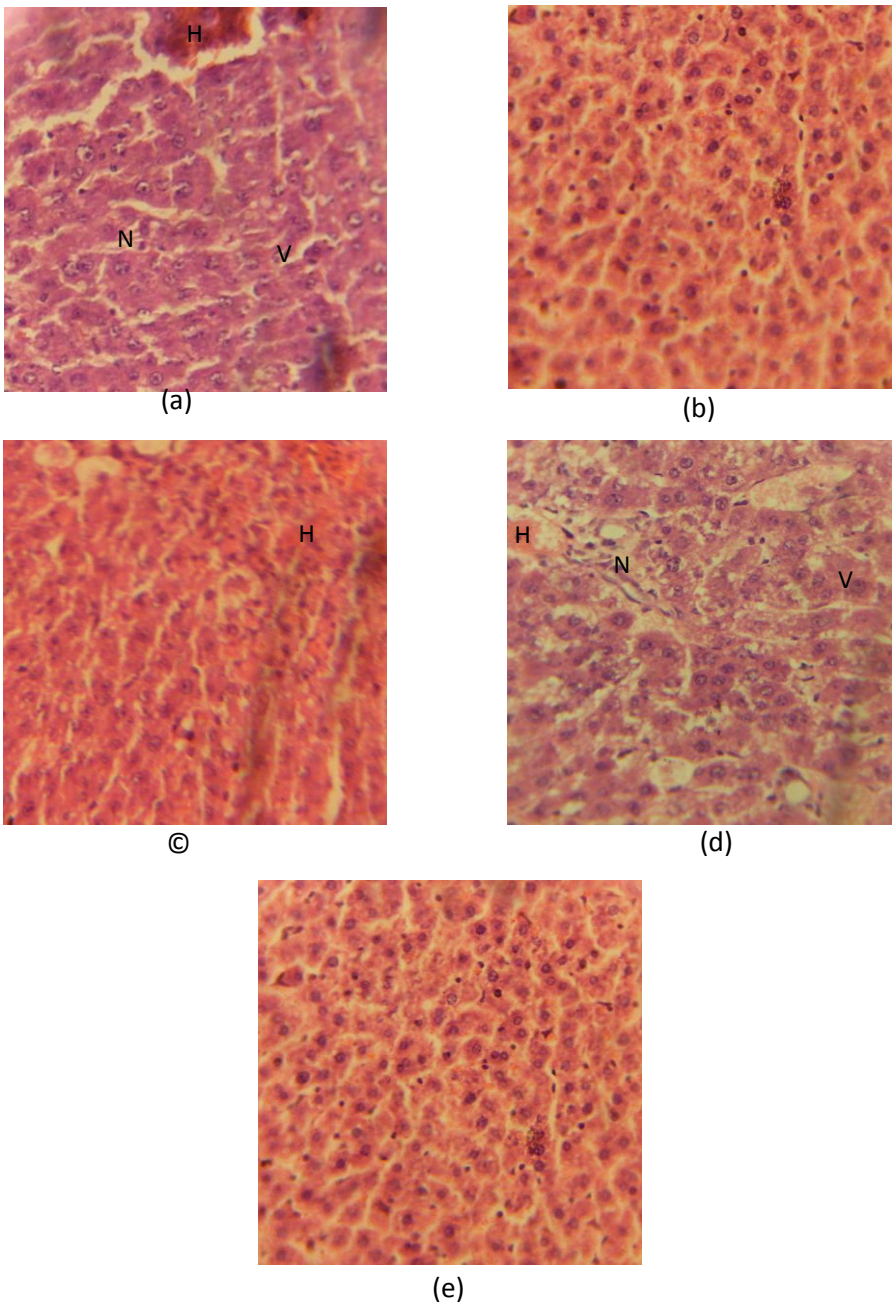

Plate III:(a) Liver section of rats pretreated with PME (100mg/kg b. wt.) + CCl_4 showing intense vacoulation, hepatic necrosis and haemorrhage (b) Liver section of rats pretreated with PME (50mg/kg b. wt.) + CCl_4 showing normal hepatocytes (c)Liver section of rats pretreated with silymarin (10mg/kg b. wt.) + CCl_4 showing normal hepatocytes and mild haemorrhage (d)Liver section of rats intoxicated with CCl_4 showing intense vacoulation with hepatic necrosis and haemorrhage (e)Liver section of normal control rat with normal histology
(. H: Haemorrhage. N: Necrosis. V: Vacuolation)

(haemotoxylin and eosin, ×40)

Intense vacoulation, lymphocytes hyperplasia and hepatic necrosis were observed (Plate III (d)) (CCl_4-induced group). In Plate III(e), the liver section of normal control rat, had normal hepatocytes clearly visible (Group 5).In Plate IV(a), liver of rats treated with high dose of AME exhibited clear hepatic recovery, with no hepatic necrosis and hepatic cells appeared normal (Group 6). But in Group 7, intense vacoulation with haemorrhage and hepatic necrosis were observed in section of rats liver treated with CCl_4 + low dose of AME (Plate IV(b)). However, the section of liver in Plate IV(c) shows normal architecture of hepatocytes with no necrosis or vacoulation (Group 8). The section of the liver intoxicated with CCl_4 (Group 9) shows intense vacoulation with hepatic necrosis and haemorrhage (Plate IV(d)). Moreover, the section of liver in Group 10 revealed the structure of hepatocytes appeared normal (Plate VI(e)).

4.4 DPPH Radical-Scavenging Activity

The radical scavenging effects of PME and Ascorbic acid are presented in Figure 2 and 3. The effective concentration (EC_{50}) of the sample was calculated by using equation of regression from the dose dependent curve. The EC_{50}values of white grub posterior methanol extract and ascorbic acid were 67.589µg/ml and 31.131µg/ml, respectively.

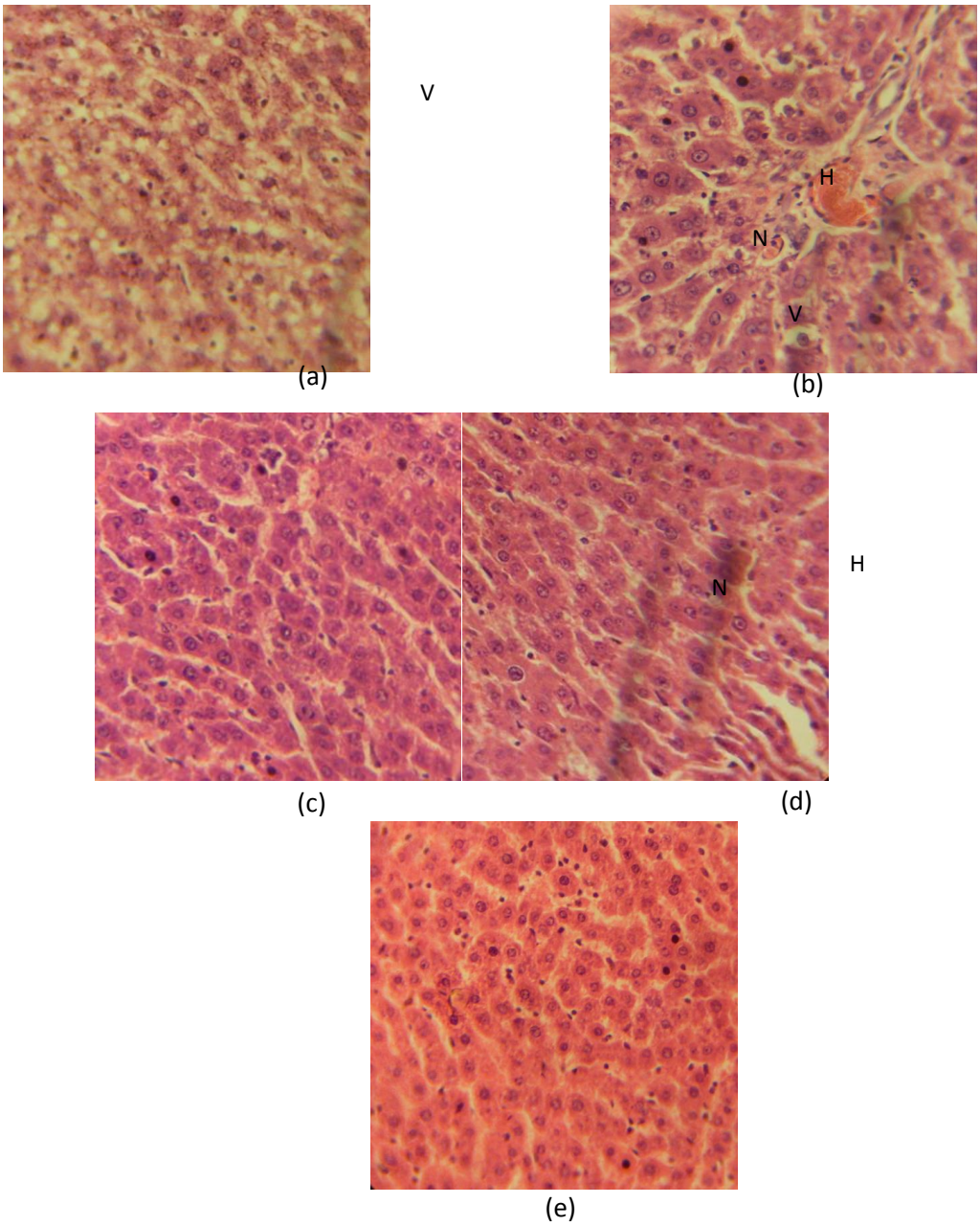

Plate IV: (a) Liver section of rats treated with AME (100mg/kg b. wt.)showing hepatic recovery, with no hepatic necrosis and hepatic cells appeared normal. (b)Liver section of rats treated with AME (50mg/kg b. wt.) + CCl_4 showing intense vacoulation with haemorrhage, and hepatic necrosis (c)Liver section of rats treated with silymarin (10mg/kg b. wt) + CCl_4 showing normal architecture of hepatocytes, with no necrosis or vacoulation (d)Liver section of rats showing intense vacoulation, haemorrhage and hepatic necrosis (CCl_4 induced group) (e) Liver section of rats (control) revealed normal hepatocytes.
H: Haemorrhage. N: Necrosis.V: Vacuolation)

(haemotoxylin and eosin, ×40)

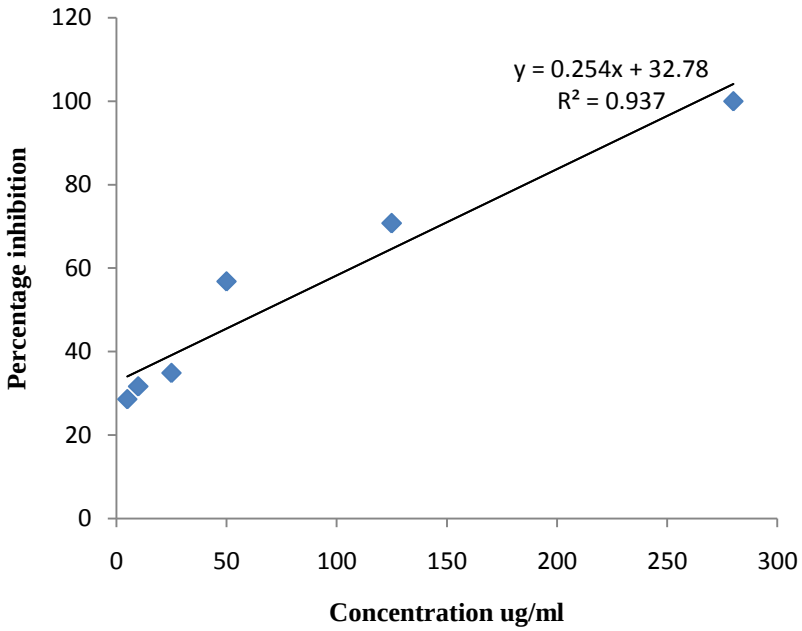

Figure 2: In-vitro free radical scavenging pattern of posterior methanolic extract with 2, 2-Diphenyl-1-picrylhydrazyl.

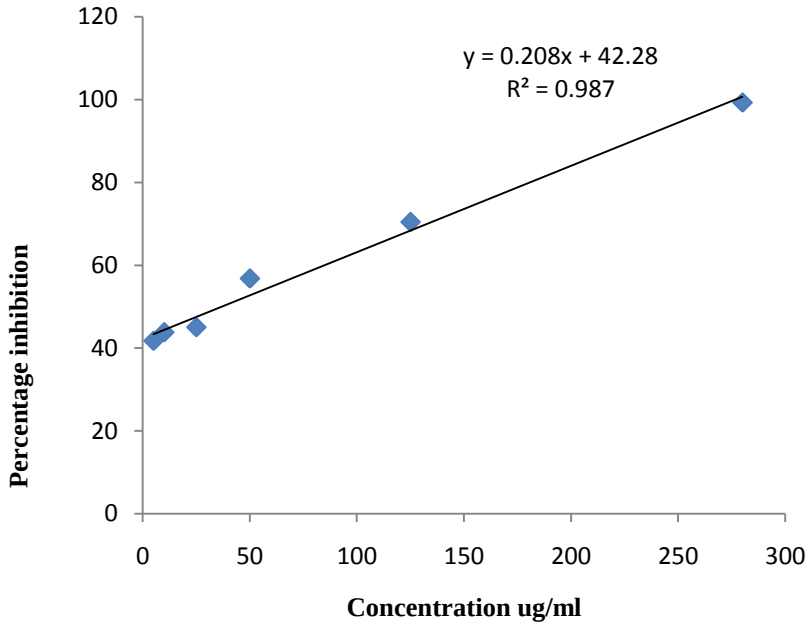

Figure 3: In vitro free radical scavenging pattern of ascorbic acid with 2, 2-Diphenyl-1-picrylhydrazyl.

CHAPTER FIVE

5.0 DISCUSSION

5.1 Discussion

The results of acute toxicity of methanol extracts of white grubs posterior (PME), white grubs anterior part (AME) showed LD_{50} greater than 5000mg/kg body weight in rats and therefore, these extracts are considered to be relatively safe as suggested by Lorke (1983). This is more so when no mortality was recorded throughout the time of the studies.

In PME toxicity studies, the organs weights were not significantly different from the control groups. However, in AME toxicity groups the liver weight of the control group differ significantly from other groups. This could be as a result of some differences between the weights (150g-200g) of the animals used, because the histopathology results of the liver did not show any sign of infections in both the doses and control groups. These results of acute toxicity of different white grubs extracts did not come as a surprise because Alhassan and Sule (2011) reported the use of white grubs among Hausa-Fulani in the treatment of jaundice, fever and general body weakness, and as a food ingredient by various communities in Northern Nigeria.

The damage of the liver caused by CCl_4 was evident by the alteration in serum marker enzymes concentration because the enzymes are placed in cytoplasmic area of the cell and are released into circulation in case of cellular damage (Rechnagel*et al.*, 1989; Bremt and Rumack 1993). However, the pretreatment of rats with methanolic extract of posterior part (50 mg/kg) was found to suppress ($P \leq 0.05$) the release of aspartate

aminotransferase (AST), alanine aminotransferase (ALT), and alkaline phosphatase (ALP) levels by the liver. The mechanism of the hepatoprotective action of the extract could be the ability of the extract to inhibit lipid peroxidation in the liver. In other words, the normal serum enzymes may be due to the prevention of leakages of intracellular enzymes by its membrane stabilizing activity. This can be compared with the view of Thabrew*et al.* (1987) that serum levels of transaminases return to normal with the healing of hepatic parenchyma and the regeneration of hepatocytes. Similarly the high dose (100mg/kg body weight) of methanol extract of anterior part (AME) and low dose (50 mg/kg body weight) of posterior extract show remarkable decreased ($P \leq 0.05$) of serum enzymes. These findings show that methanol extracts of both PME (low dose) and AME (high dose) have hepatoprotective activities against liver injury induced by CCl_4 in rats. This is in agreement with the findings of Murtala*et al.* (2011) which reported the hepatoprotective effects of aqueous white grubs extract on some markers of liver injury in Guinea pigs. Moreover, these findings supported the claim of using white grubs in the treatment of Juandice, fever and body weaknesses by various communities in Northern Nigeria.

The efficacy of any hepatoprotective drug is depending on its capacity of either reducing the harmful effect or restoring the normal hepatic physiology that has been distributed by a hepatotoxin. White grubs methanol extracts prevent the expected increase levels of liver enzymes induced by CCl_4 atlow dose (50 mg/kg b. wt.of PME) and high dose (100 mg/kg b. wt.of AME) groups indicating the protection of structural integrity of hepatocytic cell membrane or regeneration of damage liver cells (Palanivel*et al.*, 2008).

The potential therapeutics contents of white grub are posterior content (dark colour) and anterior (whitish colour). The posterior content is hydrophilic (dissolve completely in water and other polar solvents) while the anterior content is amphiphilic or amphipathic (dissolve partially in water and other polar solvents). The hepatoprotective ability of posterior methanolic extract at 50 mg/kg body weight (lower dose) could be because of its hydrophilic properties while high dose (100 mg/kg body weight) of anterior methanolic extract protected liver from damage this could be as a result of its amphipathic nature.

Carbon tetrachloride is widely used for the experimental induction of liver damage. CCl_4 at a dose of 1.4mg/kg body weight (into olive oil 1:1) used in the induction of liver injury in rats showed remarkable elevation of liver enzymes. Histopathological examination showed hepatic necrosis, hemorrhage and intense vacoulation. But administration of the extracts showed its ability to reserve the normal structure of hepatocytes. This revealed almost same results compared to silymarin group. Studies using CYP450 inhibitors (example Colchine, Silymarin and Allylisopropylacetamide) have shown that these compounds inhibit activity of CYP450 enzymes and consequently prevent metabolism of carbon tetrachloride-induced liver damage (Martinez *et al*, 1995). Therefore, the hepatoprotective ability of posterior methanolic extract (50 mg/kg b. wt) and anterior methanolic extract (100 mg/kg b. wt.) of white grubs may be due to its capacity to inhibit the activity of CYP450.Numerous studies show that metabolism of carbon tetrachloride is

required for toxicity. The initial step of carbon tetrachloride metabolism is reductive dehalogenation by CYP450, primarily CYP2EI.

Alhassan and Sule (2011) reported the percentage of humic substances (fulvic acid, humic acid and humin) in white grubs (WG). WG contains 16.05 ± 4.28% fulvic acid, 9.50 ± 2.06% humic acid and 74. 65 ± 11.31% humin.Humin has the highest percentage followed by fulvic acid and humic acid. Similarly the presence of mineral elements (Pb, Zn, Fe, Cu, Cr, Na, K, Ca, Co, Mn, and Mg) from white grubs was confirmed by Alhassan and Sule (2011). White grubs obtain these humic substances and mineral elements from the environmental waste. The hepatoprotective effects of white grubs extracts on liver injury in CCl_4 induced rats could be associated with the humic substances (fulvic acids, humic acids and humin) it contains. Humic substances are group of organic compounds formed by the association of high-molecular-mass substances from microbiological, vegetative and animal origin; they are organic macromolecules with multiple properties and higher structural complexity (Eladia*et.al.*, 2005). Humic substance has the ability to prevent the formation of genotoxic compounds that would affect the DNA of the cell (Aiken *et al*,. 1985) by adsorbing mutagens (Sato, 1987). They scavenge free radicals and thereby decreasing blood clotting activity and potential cardio-protective role (Kloocking, 1991; Ferdinandy, 1997). Humic extracts, especially fulvic acids, when administered both topically and orally are proven to regulate the immune system as powerful immuno modulators, and to work as potent antioxidants and anti-inflammatory agents (Yuan, 1998). Moreover hospital studies shows that patients normally with incurable epidemic hemorrhagic fever were able to be successfully treated

with humic extracts, which stopped bleeding, restored circulation, removed clots, was anti-viral and significantly blustered and regulated the immune system (Yin zhang, 1991). The two most important groups of potentially therapeutic are humin and fulvic acids (Elek, 1999) and have chelating property, metabolic effects, scavenge free radicals, as antioxidants, due to their complex chemical structure just like humic acids, fulvic acids have been shown to be effective chelators of both mineral ions and heavy metals, as well as stimulators of oxidative phosphorylation and energy production (Elek, 1999). Alhassan and Sule (2011) suggested that white grubs may be encouraged by cardiovascular disease patients because coronary blood flow, aortic blood flow and left ventricular and diastolic pressure were found to improve in the heart of rats, subjected to ischaemic insult and treated with humic substances (Ferdinandy, 1997).

The free radical scavenging activity of PME using 2, 2-Diphenyl-1-picrylhydrazyl (DPPH) could be due to its ability inhibits the activity of CYP450 and unintentionally triggers non enzymatic antioxidant like glutathione (biological antioxidant present in liver). Because CCl_4 metabolism leads to formation of phosgene and phosgene when react with glutathione it depletes into liver and blood consequently increases lipid peroxidation and development of hepatic necrosis 2, 2-Diphenyl-1-picrylhydrazyl (DPPH) is a stable free radical used to determine the proton-radical scavenging action of the extracts, since it possess a proton free-radical and show characteristic absorption at 517nm (Talukder*et al.*, 2013). DPPH is commercially available and widely used to evaluate the antioxidant capacity of extracts. The purple colour of the DPPH solution turned to yellow once it encounters proton-radical scavengers. The intensity of the radical

scavenging effect was measured by the calculated effective concentration (EC_{50}). The EC_{50} expresses the amount of extract necessary to decrease the absorbance of DPPH by 50% (Antolovich*et al.*, 2002). The antioxidant activity in terms of radical scavenging of DPPH of PME was determined and compared with ascorbic acid. The effective concentration required for decreasing DPPH concentration by 50% was obtained from least linear regression analysis. The effective concentration values of ascorbic acid and anterior methanolic extract were 37.01µg/ml and 69.59 µg/ml respectively the result showed that ascorbic acid had stronger antioxidant than posterior methanolic extract. However, PME antioxidant potential was also good because the cutoff value for antioxidant power is 1000 µg/ml. any extract value higher than this is not effective antioxidant. The interpolation of the linear regression revealed that the EC_{50} values increased with the increase of the concentration and the antioxidant activity of the extract decreased with the increasing of the concentration.

The *in vitro* antioxidant activity of PME showed promising radical scavenging effect. Therefore the hepatoprotective activity of PME maybe due to its antioxidant effects.

CHAPTER SIX

6.0 SUMMARY, CONCLUSION AND RECOMMENDATIONS

6.1 Summary

The result of acute toxicity study of PME and AME showed LD_{50} greater than 5000mg/kg body weight as no death was recorded. PME and AME were found to have hepatoprotective activity on liver injury in rats at 50mg/kg b. wt. and 100mg/kg b. wt. respectively; this could be associated with its contents (humis acids, fulvic acids and humin) as well as mineral elements. The biochemical analysis showed significant decreased ($p \leq 0.05$) of ALT, AST, and ALP level and maintaining the hepatic structure of liver in groups treated with PME and AME (dose dependent) and silymarin group.

However, the effective concentration ($EC_{50)}$ values of ascorbic acid and PME extract were found to be 37.01µg/ml and 67.59µg/ml.

6.2 Conclusion

The result of this study shows that posterior methanolic extract at lower dose (50 mg/kg b. wt.) and anterior methanolic extract at high dose (100 mg/kg b. wt.) exhibit hepatoprotective effect against carbon tetrachloride induced liver damage in rats. Similarly, there were significant differences in the levels of Aspartate aminotransferase, Alanine aminotransferase and alkaline phosphatase at certain doses. Moreover, the administration of white grubs extracts (50 mg/kg b. wt. of PME and 100 mg/kg b. wt. of AME) prevented CCl_4 –induced liver injury in rats. Therefore, PME prevented liver injury induced by CCl_4 better than AME

However, the results of the in vitro antioxidant assay, PME possess good antioxidant property and the data obtained clearly established the antioxidant potency of PME using DPPH radicals.

6.3 Recommendations

- Effort should be made to isolate the bioactive compounds from the grubs' extract that could be used to produce standard drugs.
- The value of many other traditional medicines should be fully evaluated towards establishing their value.

REFERENCES

Adeola M .O. (1992).Importance of wild animals and their parts in the culture, religious festivals, and traditional medicine, of Nigeria**.***Environmental Conservation*, 19(2):125-134.

Adesina, S. K. (2013). Traditional medical care in Nigeria.*Online Nigeria Daily news.*Retrieved fromhttp://www.onlinenigeria.com/health/?blurb=574

Agrawal, A. (1995). Dismantling the divide between indigenous and scientific knowledge.*Development and Change*, 26(3): 413-439.

Aiken, G. R., McKnight, D. M. and VacCarthy, P. (1985).*Humic Substances of Soil, Sediment and Water*, New York: Wildyinterscience, pp. 40-47.

Ala, A., Walker, A. P., Ashkan, K., Dooley, J. S. andSchilsky, M. L. (2007).Wilson's disease.*The Lancet*, 369(9559): 397-408.

Alhassan, A .J.,Sule, M. S., Aliyu, S. A. and Aliyu, M .D. (2009). Ideal hepatotoxicity model in rats using CCl_4. *Bayero Journal of Pure and Applied Sciences,* 2 (2): 185 – 187.

Alhassan, A. J. and Sule, M. S. (2011). Humic substances and mineral elements contents of white grubs and waste deposit.*Nigerian Journal of Basic and Applied Sciences*, 19(1): 43-48.

Alves, R. R. N. and Rosa I. L.(2005). Why study the use of animal products intraditional medicines? *Journal of Ethnobiology and Ethnomedicine*, 1(1):5. .

Amacher, D. E. (1998).Serum transaminase elevations as indicators of hepatic injury following the administration of drugs, *RegulatoryToxicology and Pharmacology*,27(2): 119–130.

Anageletti, L. R., Agrimi U., Curia, C., French, D. and Mariani-Costantini R. (1992).Healing rituals and sacred serpents.*Lancet*, 340:223-225.

Antolovic, M., Prenzler, P.D., Patsalides, E., McDonald, S. and Robards, K. (2002).Methods for testing antioxidant activity.*Analyst*, 127: 183–198.

Balch, P. A. (2006). Prescription for nutritional healing.*Penguin*, pp. 13-19

Bang, A. T., Bang, R. A., Baitule, S. B., Reddy, M. H. and Deshmukh, M. D. (1999). Effect of home-based neonatal care and management of sepsis on neonatal mortality: field trial in rural India. *The Lancet*, 354(9194): 1955-1961.

Borak, J., and Diller, W. F. (2001). Phosgene exposure: mechanisms of injury and treatment strategies. *Journal of Occupational and Environmvcental Medicine*, 43(2): 110-119.

Brent, J. A., Rumack, B. H. (1993).Role of free radicals in toxic hepatic injury II.*Clinical Toxicology*,31:173–196.

Brian, C. (2013).*Screening Cabbage Seed Beds*.US Department of Agriculture, pp. 245-267.

Bruckner, J. V., MacKenzie, W. F., Muralidhara, S., Luthra, R., Kyle, G. M. and Acosta, D. (1986). Oral Toxicity of carbon tetrachioride: Acute, subacute, and subchronic studies in rats. *Toxicological Sciences*, 6(1): 16-34.

Brussard, L. and Hijdrin, R. D. W. (1986). Some effects of Scarab beetles izxn Sandy Soils of the Neitherlands. *Geoderma*,37(4):325 –330.

Brzozowski, T., Dembinski, A. andKonturek, S. (1994): Influence of tolpa peat preparation on gastroprotection and on gastric and duodenal ulcers. *ActaPoloniae. Pharmaceutical Journal*,51:103-107.

Cambray, J. A. (2003). Impact on indigenous species biodiversity caused by the globalisation of alien recreational freshwater fisheries.*Aquatic Biodiversity*.Springer Netherlands. pp. 217-230.

Capinera, J. L. (2005). Relationships between insect pests and weeds: an evolutionary perspective. *Weed Sscience*, 53(6): 892-901.

Charmaz, K. (1991). *Good days, bad days:* The Self in Chronic Illness and Time. *The Sociological Quarterly*, 36(4), 657-680.

Chin, J. (2000). *Control of Communicable Diseases Manual*. Retrieved from http://www.ciphi.ca/hamilton/Content/documents/ccdm.pdf

Costa-Neto, E. M. (2004).Implications and applications of folk zootherapy in the State of Bahia, Northeastern Brazil.*Sustainable Development*, 12:161-174.

Costa-Neto, E. M.(2005). Animal-based medicines, biological prospection and the sustainable use of zootherapeutic resources.*An Academic Brascience*, 77(1):33-4.

Crocker, L. R., Nailon Jr. T. W. and A. J. Reinert.(1995). *May and June beetles*, Handbook of turfgrass insect pests, pp. 72-75.

Dalton, H. R., Bendall, R., Ijaz, S., and Banks, M. (2008). Hepatitis E: an emerging infection in developed countries. *The Lancet Infectious Diseases*, 8(11): 698-709.

Eladia, M., Pena-Mandez, Joseph, H. and Jiri, P. (2005).Humic substances compounds of still unknown Structure: Apllication in agriculutre, industry, environment and biomedicine. *Journal of Applied Biomedicine,*3: 13-14.

Elek, C. (1999). *Humet Product Documentation and Technical Information*.Horizon Multiplan LTD. Budapest.pp. 1-70.

Elson, H. M. (2011). *FITDAY*: Role of potassium in maintaining Health. Retrieved fromhttp://hkpp.org/patients/potassium-health Retrieved on 5/04/2013

Ferdinándy, P. (1997). *Cardioprotective effects of SHA and HA preparations in the Isolated working rat heart subjected to ischaemia/reperfusion,* (unpublished).

Fisher, R. T., Von Schrenk, H. and Hopkins, A. D. (1903).*The redwood: 1. A study of the redwood* (No. 38). Govt. Print. Off.

Flanders, K. L., DeLamar, D. Z. and Lago, K. P. (2000).Phyllophaga and related species (Coleoptera: Scarabaeidae) collected in black light traps in Alabama pastures. *Journal of Entomological Science*, 35: 311-325.

Galigher, A. E. and Kozloff, E. N.(1971).Essentials of practical microtechnique (2nd ed.), Lea and Febiger, *Philadelphia*, pp. 77 and 210.

Gitay, H. and Nobel, I. R. (1997). What are functional types and how should we seek them? In: Smith, T. M.., Shugart, H. H. and Woodward, F. I.(Eds.). *PlantFunctional Types. TheirRelevance toEcosystem Properties and Global Change*. Cambridge University Press, Cambridge,pp. 3-19.

Gums, J. G. (2004).Magnesium in cardiovascular and other disorders.*American Journal of Health-System Pharmacy*, 61(15): 1569-1576.

Hall, S. K. (1996). Solvent exposure and toxic responses.*Chemical Exposure and Toxic Responses*, 39: 23-31.

Hebda, A.(2010) *White Grubs Prevention and Control*, Nova Scotia Museum of Natural History In:Horton, S. M. (2011). Identifying the locations, movement and habitat of the European fire ant, Myrmicarubra: an invasive species in the urban/suburban environment of Halifax, Nova Scotia.

Helwig, D. (2010).Traditional African medicine.*Encyclopedia of Alternative Medicine*.

Hill, D.S. (2008). *Pests of crops in warmer climates and their control*.Springer Science and Business Media BV.US.

Hodgson, E. (2007). Utah Pests fact sheet, white grubs. *Entomology*,104: 07.

Holliday, I. (2003). Traditional medicines in modern societies: an exploration of integrationist options through East Asian experience. *Journal of Medicine and Philosophy*, 28(3): 373-389.

Huff, J. (1999). Long-term chemical carcinogenesis bioassays predict human cancer hazards: Issues, controversies, and uncertainties. *Annals of the New York Academy of Sciences*, 895(1): 56-79.

Jackson, W. R. and Jackson, W. R. (1993).Humic, fulvic and microbial balance: organic soil conditioning. *Evergreen, Colorado: Jackson Research Center*.

James, J. and Nabzdyk, D. C. (2013).*Fiama Holistic Physician*, 3524 Caton Farm Rood.pp. 815-909.

Jiangxi, G. T. (1993). *Humic acid*: Application of Fulvic acid and its derivatives in the fields of agriculture and medicine: Chapter 26 1st edition.

Kalant, H. (2001). The pharmacology and toxicology of "ecstasy"(MDMA) and related drugs. *Canadian Medical Association Journal*, 165(7): 917-928.

Kang, S. and Phipps, M. (2003).*A question of attitude:* South Korea's Traditional Medicine Practitioners and Wildlife Conservation. Traffic East Asia, Hong Kong, pp. 1-6.

King, J. C. and Cousins R. J. (2006).Zinc.*Modern Nutrition in Health and Disease.10th edition*. Baltimore: Lippincott Williams and Wilkins.pp. 271-285.

King, A. B. S. (1984). Biology and identification of white grubs (Phyllophaga) of economic importance in Central America.*International Journal of Pest Management*, 30(1): 36-50.

Kleinsek, D. and Soto, A. (2010).*U.S. Patent Application* 12/924, 052.

Klocking, R. (1989). Interaction of Humic Acids and Humic-Acid-Like Polymers with Herpes Simplex Virus Type 1*HumicSubstances in the Aquatic and Terrestrial Environment* New York; Springer-Verlag, pp: 407-412.

Labadie, R. P. (1986). Problems and possibilities in the use of traditional drugs.*Journal of Ethno Pharmacology*, 15:221-230.

Last, M. and Chavunduka, G. L. (Eds.). (1986). *Theprofessionalisation of African Medicine* (No. 1). Manchester University Press, pp. 22-34.

Lev, E. (2003).Traditional healing with animals (zootherapy): medieval to present-day Levantine practice.*Journal of Ethno Pharmacology*,86:107-118.

Lieber, C. S. (1985). Alcohol and the liver: metabolism of ethanol, metabolic effects and pathogenesis of injury. *ActaMedicaScandinavica*, 218(S703): 11-55.

Liskey, E. (1995). Identify white grubs. *Grounds Maintenance*.30: 48.

Lorke, D. (1983). A new approach to practica acute toxicity testing .*Archives of Toxicology*,54:275-287

Luginbill, Sr P. and Painter, H. R. (1953).*May beetles of the United States and Canada*. USDA, Washington, D.C. Technical Bulletin. No.1060. pp. 102.

Mahajan, S. (2006).Phytochemical investigation and hepatoprotective activity of leaves of jatrophacurcaslinn.*Carbon*, 54: 52.

Mahawar, M. M. and Jaroli, D. P.(2007). Traditional knowledge on zootherapeutic uses by the Saharia tribe of Rajasthan, India.*Journal of Ethnobiology and Ethnomedicine*,3:25.

Marques, J. G. W. (1994): A fauna medicinal dos índios Kuna de San Blas (Panamá) e a hipótese da universalidade,*Zooterápica***.** pp. 324.

Martinez, M., Mourelle, M. and Muriel, P. (1995).Protective effect of colchicine on acute liver damage induced by CCl_4. Role of cytochrome P-450.*Journal of Applied Toxicology*,15:49–52.

McCall, K. A., Huang, C. and Fierke, C. A. (2000). Function and mechanism of zincmetallo-enzymes, *Journal of Nutrition*, 13:1437S-1446S.

McLeod, P. and Studebaker, G. (2003).Major insect pests of field corn in Arkansas and their management.*Cooperation ExtentionServices. MP*, 437, 29-44

Murtala, Y., Alhassan, A. J. Babandi, A. and Suleiman, K. (2011). Effects of aqueous white grubs extract on some markers of liver injury in guinea pigs.*Bayero Journal of Pure and Applied Sciences*, 5(1): 171–174.

Muszynska, A., Palka,J.andGorodkiewicz, E. (2000) The mechanism of daunorubicin-induced inhibition of prolidase activity in human skin fibroblasts and its implication to impaired collagen biosynthesis. *Experimental Toxicology and Pathology*, 52(2):149-155.

Nelson (2004).*Nelson Natural World*.www.nelsonsnaturalworld.com/en-gb/iron/role-of-iron-in-the-body. Retrieved on 3/08/2013

Nielsen FH. (1999). Ultratrace minerals.*Modern Nutrition in Health and Disease.9th edition.* Baltimore: Williams and Wilkins, pp. 283-303.

O'Dell, B. L. (2000). Role of zinc in plasma membrane function, *Journal of Nutrition*.130(5S Supplementary):1432S-1436S.

Ortega, A. (1987). *Insect pests of Maize*: A Guide for Field Identification. Mexico, D.F.: CIMMYT.

Padmanabhan, P. and Sujana, K. A.(2008). Animal products in traditional medicine from Attappady hills of Western Ghats.*Indian Journal of Traditional Knowledge*,7(2): 326-329.

Palanivel, M. G., Rajkapoor, B. and Kumar, R. S. (2008).Hepatoprotective and antioxidant effect of pisoniaaculeata L. Against CCl4- induced hepatic damage in rats. *Science Pharmaceutical*,76:203–215.

Paul, A. D. (2012). *Normal Liver Histology*.Royal College of Pathologists.London: UCL Medical School Royal Free Campus, pp.231-237.

Pflug, W. and Ziechman, W. (1982). Humic acids and the disruption of bacterial cell walls by lysozyme.soil biology. *Biochemistry*,14: 165-166.

Pieroni, A., Price, L. L. andVandebroek, I. (2005) Welcome to journal of ethnobiologyand ethnomedicine. *Journal of Ethnobiology and Ethnomedicine*, 1:1.

Pietrangelo, A. (2004). Hereditary hemochromatosis—a new look at an old disease. *New England Journal of Medicine*, 350(23): 2383-2397.

Pitt, J. I., and Hocking, A. D. (1997).Methods for isolation, enumeration and identification.In *Fungi and Food Spoilage*, Springer US.pp. 21-57

Potter, D. (1998). *Destructive turfgrass insects: biology, diagnosis and control.*Ann Arbor Press, Chelsea, Michigan.pp. 344.

Proctor, N. H., Hughes, J. P. and Hathaway, G. J. (2004).*Proctor and Hughes' Chemical Hazards of the Workplace*. John Wiley and Sons, pp. 11-20.

Rajkapoor, B. Venugopal, Y. Anbu, J. Harikrishnan, N. Gobinath, M. and Ravichandran, V. (2008). Protective effect of *Phyllanthuspolyphyllus*on acetaminophen induced hepatotoxicity in rats, *Pakistan Journal of Pharmaceutical Sciences*,21(1):57–62.

Ralph, E. B. (1998). *Insects and Mites of Economic Importance in the Northwest*.2nd Edition.221 p EENY045.Gainesville, FL: University of Florida, Instituteof Food and Agricultural Sciences, Entomologyand Nematology Department,pp. 4.

Recknagel, R. O. (1983). Carbon tetrachloride hepatotoxicity, *Trends in Pharmacological Sciences*,4: 129-131.

Recknagel, R. O., Glende, J. E. A. and Dolack J. A. (1989).Mechanisms of carbon tetrachloride toxicity.*Pharmacology*43:139–154

Reckon diagnostics(2013). Retrieved from www.reckondiagnostics.com

Reece I., Jane B. and Neil C.A., (2009).*Campbell biology*.9th edition.Revised.

Rhodes, C. and Thomas, M. (1993). Principles of testing for acute toxic effects, *General and Applied Toxicology*, 1: 49-87.

Richard, A. A. (2007) *Micronutrient Research for optimum Health*. Linus Pauling Institute

Richter, M. (2003).Traditional medicines and traditional healers in South Africa.*Treatment action campaign and AIDS law project*, 17: 4-29.

Riley, E. G. (1988).*The Phyllophaga of Louisiana (Coleoptera: Scarabaeidae)*. MS Thesis, Department of Entomology, Louisiana State University, Baton Rouge, LA, pp. 436.

Ronzio, R. A. (2003). *The encyclopedia of nutrition and good health*.Infobase Publishing.

Rude, R. K. and Shils, M. E. (2006).*Magnesium.Nutrition in Health and Disease.10th edition.* Baltimore: Lippincott Williams and Wilkins, pp. 223-247.

Rudel, R. A., Attfield, K. R., Schifano, J. N. and Brody, J. G. (2007). Chemicals causing mammary gland tumors in animals signal new directions for epidemiology, chemicals testing, and risk assessment for breast cancer prevention. *Cancer*, 109(S12): 2635-2666.

Sato, T. (1987) Mechanism of the desmutagenic effect of humic acid.*Mutation Ressearch*,176: 199-204.

Schiff, E. R., Sorrell, M. F. and Maddrey, W. C. (Eds.).(2007). *Schiff's Diseases of the Liver* Volume 1.Lippincott Williams and Wilkins.

Selman, H. L. (2008). White grubs, *Phyllophaga*and other species. In:Teshita, A. andGashaw, A. (2014). Corn-Root Boring White Grub and its Management, the Case of Ethiopia.*African Journal of Basic & Applied Sciences*, 6(3), 50-56.

Senesi, N. (1990). Molecular and quantitative aspects of the chemistry of fulvic acid and its interactions with metal ions and organic chemicals: Bari Italy Analytica chemical Amsterdam, The Netherlaands: Elsevier, *Acta*, 232: 5-75.

Shahjahan, M., Sabitha, K. E., Jainu, M. and Devi, C. S. (2004). Effect of Solanumtrilobatum against carbon tetra chloride induced hepatic damage in albino rats. *Indian Journal of Medical Research*, 120: 194-198.

Sharma, A., Chakraborti K.K. and Handa, S.S., (1991).Anti-hepatotoxic activity of some Indian herbal formulations as compared to silymarin.*Fitoterapia*62: 229-235.

Shetlar, D. J. (2012).Billbugs in turfgrass.*Ohio State University Extension*.

Shnoy, A. K. Somayaji, S. N. and Bairy, K. L. (2002)Hepatoprotective activity of ethanolic extract of *Ginkgo biloba*against carbon tetrachloride induced hepatic injury in rats,*Indian Journal Pharmacology*, 46: 167–174.

Solovan, A., Paulmurugan, R., Wilsanand, V. andRanjith Sing, A. (2004).Traditional therapeutic uses of animals among tribal population of Tamil Nadu.*Indian Journal of Traditional Knowledge*, 3(2):206-207.

Spero, J. M., DeVito, B., and Theodore, L. (Eds.).(2000). *Regulatory chemicals handbook*.CRC Press.

Subramonium, A. and Pushpangadan, P., (1999). Development of Phytomedicines for liver diseases. *Indian Journal of Pharmacology*,31:166-175.

Talukder, M. E. U., Aklima, J., Emran, T. B., Islam, S., Rahman, A. andBhuiyan, R. H. (2013). In vitro Antioxidant Potential of Momordicacharantia Fruit Extracts. *British Journal of Pharmaceutical Research*, 3(4): 963-971.

Tanaka, K., TOMITA, Y. and ICHIHARA, A. (1978). Biochemical studies on liver functions in primary cultured hepatocytes of adult rats I. Hormonal effects on cell viability and protein synthesis. *Journal of Biochemistry*, 84(4): 937-946.

Tashiro, H. (1987). *Turfgrass insects of the United States and Canad*a.Comstock Publishing Associates, London, Great Britain, pp. 391.

Thabrew, M., Joice, P. D. and Rajatissa, W. (1987) A comparative study of the efficacy of pavettaindica and osbeckiaoctandra in the treatment of liver dysfunction. *Planta Medicine*,53:239–241.

Taylor, T. (2013). *Anatomy and Physiology.* Inner body.com

Tortora, G. J.andDerrickson, B. H. (2008).*Principles of anatomy and physiology*.John Wiley and Sons.

Ubani, L. U. (2011). *Preventive Therapy in Complimentary Medicine: Volume I to Liberate Humankind from the Pain and Furffering of Synthetic and Chemicalized Medications*. Xlibris Corporation.

Uma, N. Fakurazi, S. and Hairuszah, I. (2010). *Moringaoleifera*enhances liver antioxidant status via elevation of antioxidantenzymes activity and counteracts

paracetamol-induced hepatotoxicity, *Malaysian Journal of Nutrition*, 16(2): 293–307.

Uriu-Adams, J. Y. and Keen, C. L. (2005). Copper, oxidative stress, and human health. *Molecular Aspects of Medicine*, 26(4): 268-298.

Walum, E. (1998). Acute Oral Toxicity, Cell and Molecular Biology.*Evirnmental Health Perspectives.*106, (Supplement 2): 497-503.

Watschke, L. T., Dernoeden, H. P. and Shetlar, D. J. (1995).*Managing Turfgrass Pests*. Lewis Publishers, Boca Raton, FL. pp. 361

WHO/IUCN/WWF (1993).*Guidelines on Conservation of MedicinalPlants.*Switzerland.

Wick, E. C. (1998). Transient receptor potential vanilloid (TRPV-1) promotes neurogenic inflammation in the pancreas via activation of the neurokinin-1 receptor (NK-1R). *Pancreas*, 30(3): 260-265.

Williams, I. (1999). Epidemiology of hepatitis C in the United States.*The American Journal of Medicine*, 107(6): 2-9.

World Health Organisation (2008).Traditional Medicine.*Fact sheet,* No. 134

World Health Organisation (WHO) (2013).*Traditional medicine*: General guidelines for methodologies on research and evaluation of traditional medicine. World Health Organization Geneva, Pp. 1.

Yin zang, C. (1991).Fouling of UF membrane by humic substance: Effects of molecular weight and powder-activated carbon (PAC) pre-treatment.*Desalination*, 170(1): 59-67.

Yuan, S. (1993). *Application of Fulvic Acid and its Derivatives in the Field of Medicine*; First edition,pp. 75-79.

Apendix I: Liver sections of toxicology studies of anterior methanolic extract.

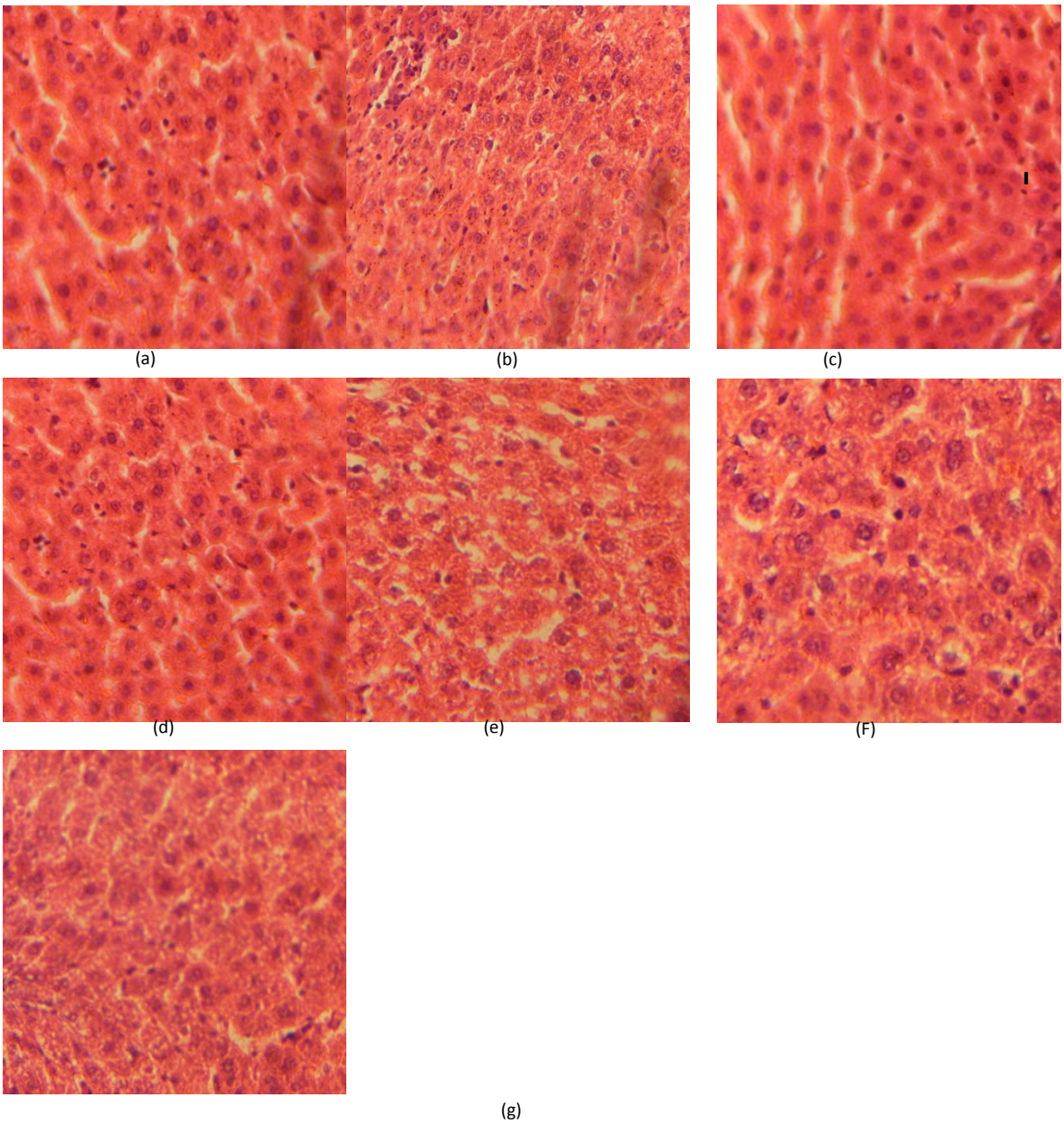

Plate V: Liver sections (a)10mg/kg of AME (b) 100mh/kg of AME (c) 1000mg/kg of AME showing mild inflammation (d) 1200mg/kg of AME (e) 1600mg/kg of AME (f) 2900mg/kg of AME (g) 5000mg/kg of AME. (I: Inflammation)

(haemotoxylin and eosin, ×40)

.