SONOGRAPHIC MEASUREMENTS OF SOME OCULAR PARAMETERS OF INDIGENOUS NIGERIAN DOGS IN ZARIA, NIGERIA

BY

HASSAN ABDULLAHI AUDU

DEPARTMENT OF VETERINARY SURGERY AND RADIOLOGY

FACULTY OF VETERINARY MEDICINE

AHMADU BELLO UNIVERSITY, ZARIA, NIGERIA

NOVEMBER, 2015

SONOGRAPHIC MEASUREMENTS OF SOME OCULAR PARAMETERS OF INDIGENOUS NIGERIAN DOGS IN ZARIA, NIGERIA

BY

Hassan Abdullahi AUDU, DVM (ABU 2011)

(M.Sc./Vet-Med/23500/2012-2013)

A DISSERTATION SUBMITTED TO THE SCHOOL OF POSTGRADUATE STUDIES, AHMADU BELLO UNIVERSITY ZARIA IN PARTIAL FULFILLMENT OF THE REQUIREMENTS FOR THE AWARD OF MASTER DEGREE IN VETERINARY RADIOLOGY

DEPARTMENT OF VETERINARY SURGERY AND RADIOLOGY

AHMADU BELLO UNIVERSITY, ZARIA,

NIGERIA

NOVEMBER, 2015

DECLARATION

I declare that the work in this Dissertation entitled **"Sonographic Measurements of Some Ocular Parameters of Indigenous Nigerian Dogs in Zaria, Nigeria"** has been carried out by me in the Department of Veterinary Surgery and Radiology, at the Veterinary Teaching Hospital, Ahmadu Bello University, Zaria under the supervision of Dr S. T. Fadason and Dr A. U. Hamidu.

The information derived from the literature has been duly acknowledged in the text and a list of references provided. No part of this Dissertation was previously presented for another degree or diploma at this or any other institution.

Hassan Abdullahi AUDU	_____	_____
Name of student	Signature	Date

CERTIFICATION

This dissertation entitled, **"SONOGRAPHIC MEASUREMENTS OF SOME OCULAR PARAMETERS OF INDIGENOUS NIGERIAN DOGS IN ZARIA, NIGERIA"** by Hassan Abdullahi AUDU, meets the regulations governing the award of degree of Master of Science in Veterinary Radiology of Ahmadu Bello University Zaria, and is approved for its contribution to knowledge and literary presentation.

Dr. S. T. Fadason Department of Veterinary Surgery and Radiology, A.B.U. Zaria Chairman, Supervisory Committee	_____ Signature	_____ Date
Dr. A. U. Hamidu Department of Radiology A.B.U., Zaria Member, Supervisory Committee	_____ Signature	_____ Date
Dr. S. T. Fadason Head of Department, Veterinary Surgery and Radiology, A.B.U. Zaria	_____ Signature	_____ Date
Prof. Kabir Bala Dean, School of Postgraduate Studies, A.B.U Zaria	_____ Signature	_____ Date

ACKNOWLEDGEMENTS

I am thankful to Almighty Allah for granting me and my team of supervisors the will and might to carry out this research work.

My sincere gratitude goes to my team of supervisors: Dr. S. T. Fadason and Dr A. U. Hamidu for giving me the courage, support, assistance and kindness to carry out the research work. I am most thankful to them for their constructive criticisms, patience and guidance all through the work.

To the former Head of department of Veterinary Surgery and Radiology, ABU Zaria, Prof. A. Z. Hassan, Unit Head Radiology, Department of Veterinary Surgery and Radiology, Dr Lawal Maruf and the Director ABUVTH Prof. Lawal Saidu, I thank you all profoundly for graciously granting me all the necessary support, tools, facilities and machine needed to carry out this work. I am grateful to all clinicians, colleagues, surgeons, teachers and technicians who in one way or the other played significant roles in bringing this work to limelight.

I appreciate the assistance of the dog owners in Sabo LGA, Hayin Dogo, Dog market in Zaria and a host of other dog owners for assenting to allow me use their dogs for this work. I wish to particularly acknowledge Dr Usman Ismaila Jimoh for his brotherly supports and assistance with transportation and other logistics; and Mallam Ya'u Hamza of the Department of Vet. Surgery and Radiology, for the active roles and concious efforts offered interms of identifying dog owners location and convincing them to assist in the actualization of the study.

Last but not the least, my profound appreciation goes to my Mother and siblings for their unflinching care, love, support and prayers they showered upon me. I am forever indebted to you all, may Almighty Allah pay and reward you all with good in this world and paradise in the hereafter.

May Almighty God's abundant blessings never cease from your lives. Amen

ABSTRACT

Ultrasound imaging is a successful imaging modality with a broad variety of diagnostic applications including detection of ocular pathologies. This study was aimed to conduct ophthalmic sonographic examination using B-scan and to provide baseline information from the ultrasonographic examination of clinically healthy eyes of the indigenous dogs; and to determine pachymetry of the clinically healthy indigenous dog eyes based on age, sex, weight and Intraocular pressure (IOP) readings. Eighty (80) indigenous Nigerian dogs were selected and distributed into three groups according to age; thus, group 1 (G1) was composed of puppy-young dogs (≤ 1 - year - old), group 2 (G2) was composed of adult dogs (□ 1 ≤ 4– years - old) and group 3 (G3) was composed of older-senior dogs (□ 4 – years - old). Ultrasonographic examination was performed using a B-mode ocular ultrasound unit (Medison S600) equiped with a 7.5 MHz curvilinear probe with the dogs adequately restrained by physical technique, and the structures of the ocular globe was evaluated at a depth of 4-6 cm. For each group, baseline data were obtained for corneal thickness (D1), anterior chamber depth (D2), lens thickness (D3), vitreous chamber depth (D4), and the axial length of the eye (D5). Similarly, the baseline data were obtained for anterior chamber area (A1), lens area (A2), vitreous chamber area (A3) and ocular globe area (A4). Our result revealed that the ocular parameters of the Indigenous Nigerian dogs' varied in two patterns: corneal thickness (D1), lens thickness and area (D3 and A2) and axial length and area (D5 and A4) increased with age from puppy to the adult and the older dogs' group in both sexes. However, the anterior chamber depth and area (D2 and A1) and vitrous depth and area (D4 and A3) increased initially with age from puppy to the adult dogs' group and then decreased slightly in the older dogs' group. No differences were observed when comparing pachymetry of the left and right eyes of dogs within the same age conformation group ($p > 0.05$).

Similarly, no statistically significant relationship was observed between the ocular parameters of the male and female ($P > 0.05$), within the groups. The intraocular pressure (IOP) of the studied dogs' eye varied in a similar pattern as the weight when we compared both variables with the ocular parameters measured. No correlation using Pearson's test was observed between corneal thickness and the weight of the dogs, as well as the between the corneal thickness and the IOP in all the groups ($P > 0.05$). However, a positive correlation was observed between weight and the other ocular parameters in all groups, and as well as between IOP and all ocular parameter that were considered ($P < 0.05$). The three (3) major ocular segments- anterior chamber, lens capsule and vitreous chamber was demonstrated in this study to represent approximately 2%, 17% and 76% respectively of the entire ocular globe area. The ciliary body and muscles, suspensory ligament and posterior chamber makes up the remainder 5%. Our findings, although preliminary, are relevant for a complete diagnosis of certain ocular conditions. Based on the results obtained, it is possible to conclude that ophthalmic ultrasound in B-mode, is an effective method in determining the anatomical relation necessary to perform biometry of intraocular structures of indigenous Nigerian dogs and to obtain ocular parameters in Indigenous Nigerian dogs.

TABLE OF CONTENTS

Cover page……..……...…….. *i*

Title page…...……..…..…….…… *ii*

Declaration ……...…..……..……. *iii*

Certification ..……..……..….……...……. *iv*

Acknowledgement ….……...……..….…….……..….. *v*

Abstract ……....…….……..... *vi*

Table of contents …….…….……..……. *viii*

List of figures ……..……..…….……..… xii

List of Plates …….…….…….…….……xiii

List of Tables ……..…….……... xiv

List of Appendices…….……..……..……xv

CHAPTER ONE: INTRODUCTION……..…….……..…1

1.1 Preamble…….…..……..…..1

1.2 Statement of Research Problem……..…….……..……7

1.3 Justification for the Study …….…..……..…….....…7

1.4 Aim of the Study……...……...8

1.5 Objectives of the Study.……....……...……9

1.6 Research Hypotheses……..……...……..9

CHAPTER TWO: LITERATURE REVIEW……..……..…10

2.1: Ocular Anatomy of a Dog……...…….10

2.1.1 Compartments of the Ocular Globe……..……10

2.1.2 Ocular Structures……..……...…….....14

2.2 Ophthalmic Examination……...…21

2.2.1 Special Ophthalmic Techniques**…...……....21**

2.3 Tonometry…….……24

2.4 Ophthalmoscopy……...…….27

2.5 Ocular Ultrasonography……..…….……...…..27

2.5.1 Historical Reviews on Diagnostic Ocular Ultrasonography……...……..……..…..29

2.5.2 Indications for Ocular Ultrasound…….…….…..30

2.5.3 Importance of Diagnostic Ocular Ultrasonography……..…….....30

2.5.4 Principles of ultrasound……...…….……35

2.5.5 Instruments in ocular ultrasound…….……..37

2.5.6 Probe positioning……..……..…….….38

2.5.7 Ocular Imaging Techniques…….…….....40

2.5.8 Ocular Biometry……..……..41

2.6 Diagnostic Ultrasound……...…42

2.7 Echodescription of Common Intraocular Conditions……...51

2.8 Artifacts in Ocular Ultrasonography .....……...……..……..…57

2.9 Uses of Diagnostic Ocular Ultrasound……..…….……..….60

CHAPTER THREE: MATERIAL AND METHODS…….....….62

3.1 Material/Equipments……...……..62

3.1.1 Source of Animals……..……...62

3.1.2 Diagnostic preparations……..……..…..…..63

3.2 Methodology……..…….63

3.2.1 Study area…….……...…….63

3.2.2 Study Animal and design…….…..……...…63

3.2.3 Study Animal Screening and Distribution……..……..64

3.2.4 Pre-ultrasound scanning consideration…….……....……64

3.2.5 Ultrasound procedure/technique……...69

3.2.6 Data recording and Statistical Analysis……..…….……72

CHAPTER FOUR: RESULTS… …….…….……75

4.1 Pre Ultrasound Findings……...……...…….75

4.2 Ultrasound Findings……...…75

4.2.1 Identification of Ocular structures on the Ultrasonogram……..…….75

4.2.2 Ocular biometry results……...…….….77

4.2.3 Variability of Ocular parameters according to age group in the study dogs……79

4.2.4 Ocular parameters of right and left eyes of study dogs…….……...94

4.2.5 Ocular parameter and weight (size) of dogs…….97

4.2.6 Ocular parameters variables in Male and Female dogs……..…….....97

4.2.7 Percentage Area compartmentalization of Ocular Segments……..…….....100

CHAPTER FIVE: DISCUSSION…..…….....101

CHAPTER SIX: CONCLUSION AND RECOMMENDATION……...……...…106

6.1 Conclusion…….……...…106

6.2 Recommendation……...……107

REFERENCES……...…108

APPENDICES……118

LIST OF FIGURES

Figure	Title	Page
1	Gross Anatomy of the Eye of a Dog	3
2.1a	Ultrastructure of Dog's eye	12
2.1b	Ocular Sonograph depicting intraocular structure	13
2.2	Components of the Nasolacrimal Apparatus of the Dog	17
2.3	Normal sonographic appearance of the ocular globe	43
3.1	Schematic illustration of Intraocular biometric measurements of ocular parameters	73
4.1	Variability of corneal thickness values in the puppy, adult and older dogs	80
4.2	Variability of anterior chamber depth values in the puppy, adult and older dogs	81
4.3	Variability of lens thickness values in the puppy, adult and older dogs	82
4.4	Variability of vitreous chamber depth values in the puppy, adult and older dogs	84
4.5	Variability of axial globe length values in the puppy,adult and older dogs	85
4.6	Variability of anterior chamber area values in the puppy, adult and older dog	86
4.7	Variability of lens area values in the puppy, adult and older dogs	87
4.8	Variability of vitreous chamber area values in the puppy, adult and older dogs	88
4.9	Variability of ocular globe area values in the puppy, adult and older dogs	90
4.10	Percentage Area occupied by ocular chambers	100

LIST OF PLATES

Plate	Title	Page
I	Conduction of pre-ultrasound ophthalmoscopy	66
II	Tonometry procedure using iCare tonometer	68
III	Field set up for pre-ultrasound and ultrasound ophthalmology	71
IV	Trasncorneal B-mode from a clinically normal dog's eye	76
V	Ocular biometry of a clinically normal indigenous dog's eye	77
VI	Sonogram of an indigenous Nigerian dog's eye depicting area measurement	78
VII	Sonogram of ocular biometry of one of the dogs in the puppy group (G1) of the indigenous dogs studied	91
VIII	Sonogram of ocular biometry of one of the dogs in the adult group (G2) of the indigenous dogs studied	92
IX	Sonogram of ocular biometry in the older group (G3) of the indigenous dogs that were studied	93

LIST OF TABLES

Table	Title	Page
3.1	Measurement of the intraocular parameters in dogs of different age (mm)	74
4.1	Mean and ±SD (mm) values for left and right intraocular structure measurements (lenght biometrics) comparing groups of dogs according to their age difference	95
4.2	Mean and ± SD (mm^2) values for left and right intraocular structure measurements (area biometrics) comparing groups of dogs according to their age difference	96
4.3	Relationships between mean (± SD) values of intraocular structures and gender using T-Test	98
4.4	Mean and ±SD (mm) values for intraocular structure measurements comparing groups of dogs according to their IOP readings	99

LIST OF APPENDICES

Appendix	Title	page
Ia	Grouping of indigenous dogs that underwent ophthalmic examinations pre-ocular ultrasonography (group one)	118
Ib	Grouping of indigenous dogs that underwent ophthalmic examinations pre-ocular ultrasonography (group two)	119
Ic	Grouping of indigenous dogs that underwent ophthalmic examinations pre-ocular ultrasonography (group three)	120
IIa	Sonographic measurement of ocular parameters of length in indidgenous dogs (group one)	121
IIb	Sonographic measurement of ocular parameters of length in indidgenous dogs (group two)	123
IIc	Sonographic measurement of ocular parameters of length in indidgenous dogs (group three)	124
IIIa	Sonographic measurement of ocular parameters of area in indidgenous dogs (group one)	125
IIIb	Sonographic measurement of ocular parameters of area in indidgenous dogs (group two)	127
IIIc	Sonographic measurement of ocular parameters of area in indidgenous dogs (group three)	128
IVa	Measurement of percentage (%) area covered by each eye segments in indigenous dogs (group one)	129
IVb	Measurement of percentage (%) area covered by each eye segments in indigenous dogs (group two)	130
IVc	Measurement of percentage (%) area covered by each eye segments in indigenous dogs (group three)	131
V	Client consent form	132
VIa	Some of the Equipment and Materials used for the pre-scan ophthalmic study	133
VIb	Some of the equipment and materials used for scanning procedure	134
VII	Some of the Indigenous Nigerian dogs that were used for the study	135

CHAPTER ONE

INTRODUCTION

1.1 Preamble

Vision is an integral part of every sighted animal's life (Anon[8], 1997). The organ of vision is the eye, and sight is a sense that is precious to humans as well as many animals, and hence, scientists have studied it more than any other sense.

A dog's visual capabilities directly affect its ability to engage in high performance, visually orientated activities, such as guiding the blind, police work, obedience training, racing, and hunting (Miller and Murphy, 1995). Compared with the visual system in human beings, the canine visual system could be considered inferior in such aspects as degree of binocular overlap, color perception, accommodative range and visual acuity. However, in other aspects of vision, such as ability to function in dim light, rapidity with which the retina can respond to another image (flicker fusion), field of view, ability to differentiate shades of gray, and, perhaps, ability to detect motion, the canine visual system probably surpasses the human visual system (David, 1984; Miller and Murphy, 1995; Anon[8], 1997). This has made the dog a more efficient predator in certain environmental situations and permits it to exploit an ecological niche inaccessible to humans (Miller and Murphy, 1995).

Different breeds of dogs have different eye shapes and dimensions, and also have different retina configurations (Anon[4], 1998). Anatomically, the eye is composed mainly of two segments - anterior and posterior eye segments (Shaw, 2011). Three sections make up the anterior eye segment, namely anterior chamber, bounded by cornea anteriorly and iris and anterior lens surface posteriorly and filled with aqueous humor; the posterior chamber is the second chamber

and it is bounded anteriorly by iris, posteriorly by lens capsule and anterior vitreous face; filled with aqueous humor; and the third chamber is the vitreous, it is attached at the pars plana, posterior lens capsule and inner limiting membrane of retina; almost completely acellular; composed of hyaluronic acid, small amounts of collagen and rare hyalocytes. Separating the anterior and posterior chambers is the iris and ciliary body, whereas separating the posterior chambers and the vitreous chamber is the lens. The Posterior segment of the eye is composed of retina and choroid (Miller and Evans, 2013). The Uvea is composed of iris, ciliary body (anterior uvea) and choroid (posterior uvea). The Fundus is a part of the retina and all associated structures that are visible with the ophthalmoscope; the retina of dogs and cats is termed holangiotic i.e it has tapetal (superior) and nontapetal (inferior) parts (Shaw, 2011). Figure 1 shows a saggital gross section of the canine globe.

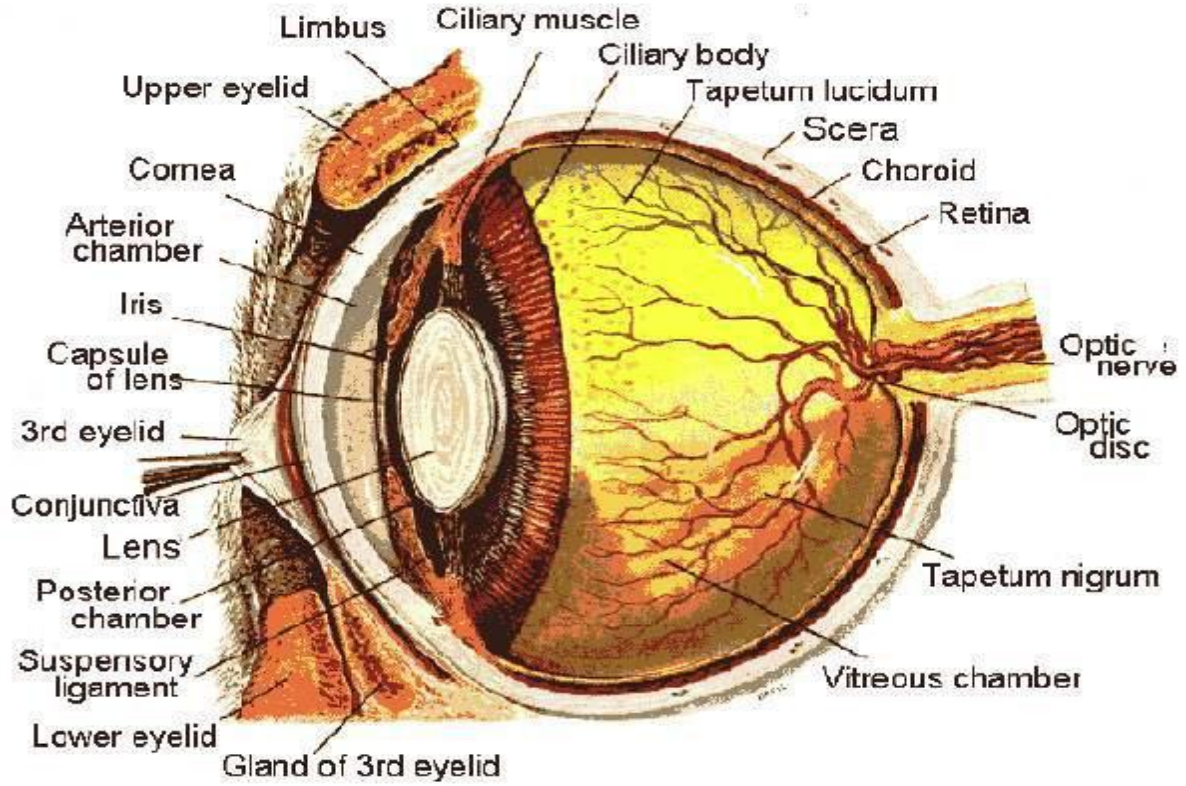

Figure 1: Gross Anatomy of the Eye of a Dog
Source: http://www.ttlntl.co.uk/3/Anatomy/eye.htm

For a complete and proper conduction of ophthalmic examination, knowing the chief complaint from the client, signalment and performance of a good medical history will greatly help the examiner in directing and refining the ophthalmic examination procedure, which will result in an accurate problem list and diagnosis. The examination environment is important and can greatly influence the examination results (Schoster *et al.,* 1995). Due to its anatomical structure, the eye permits direct observation of many pathologic processes as they develop. The vast of ophthalmic conditions can be diagnosed with a few relatively simple tools and techniques that almost every veterinarian can learn and use in clinical practice. Ophthalmic examination is usually preceeded by general examination, because some systemic diseases may manifest ocular signs (Beránek, 2014). A preliminary visual inspection of the globe and external ocular structures-eyelids, conjunctiva, sclera, pupil, cornea, and lens in day light or room light includes bilateral judgment of the visual axis and positions of the globe, symmetry of the external ocular structures, position of the eyelids, size of the palpebral fissure, position of the membrane nictitans, presence of nystagmus, anisocoria, blepharospasm, lagophthalmos, ocular or nasal discharge. The eyes should always be assessed for size, position, discharges, inflammation, redness (or other color changes), uneven/abnormal pupil size, corneal clouding and squinting (Hofmeister *et al.,* 2006).

Vision Testing involves menace response (blink reflex), cotton balls and maze testing (Schoster, *et al.,* 1995). Special techniques that can be used for the examination of the eyes include Schirmer tear test (STT), Aqueocentesis, Fluorophotometry, Tonometry, Biomicroscopy, Ophthalmoscopy, Gonioscopy, Doppler indirect blood pressure measurement, Electroretinography, Ocular ultrasonography (Beránek 2014).

Ultrasonography is useful for ophthalmologic examination of animals because it is readily available, cost-effective, safe, and noninvasive and can typically be performed without sedation (Mettenleiter, 1995 and Dietrich, 2007). The emergence of ultrasonography as a diagnostic tool has steadily increased ever since it was first used in the field of ophthalmology by Mundt and Hughes in 1956. Oksala and Lehtinen reported in 1958 the sound velocities in the various components of the eye. Baum and Greenwood came up with two dimensional immersion scan in 1958, which was subsequently improved upon by Purnell (1969), Coleman *et al* (1977) and Ossoinig (1979). Contact B-scan was introduced by Bronson and Fisher (1976), and it being portable, became part of everyday use in ophthalmology. There have been constant improvements in both, the standardized A-scan (Time amplitude scan) and B-scan (Brightness mode, two dimensional scan).

The diagnostic value of ultrasonography is high for animals with opacities of corneas, aqueous humor, lenses, or vitreous humor or pronounced eyelid swelling because direct observation of intraocular structures is not possible for such eyes and assessment of intraocular structures is important for determination of diagnoses and prognoses and for planning of treatments (Penninck *et al.,* 2001; Ramirez and Tucker, 2004). Even for animals for which direct observation of intraocular structures is possible, ultrasonography may be helpful for tumor identification, performance of measurements, and comparison of findings to those for the contralateral eye (Gonzalez *et al.*, 2001; Wollanke and Gerhards, 2011). Structures that cannot be observed by use of routine ophthalmologic examination techniques, such as ciliary bodies or retrobulbar spaces, can be evaluated via ultrasonography (Hoffmann *et al.,* 2004). Of the two display modes used during ocular ultrasonography of animals, brightness mode (B-mode) is used more commonly than amplitude mode (A-mode) (Ramirez and Tucker, 2004).

Ultrasonography is a useful tool to evaluate the contents of the globe and orbit as is done routinely in companion animal medicine (Ribeiro *et al.*, 2009). Transcorneal ultrasonography enables the evaluation of intraocular structures in eyes with opaque, diseased corneas in order to evaluate the prognosis for vision following resolution of the corneal disease. Corneal edema is a common clinical sign of corneal ulceration, keratitis, anterior uveitis, and many systemic diseases, and precludes the direct visualization of intraocular structures by ophthalmoscopy (Whittaker *et al.*, 1999). Under such conditions, alternative diagnostic methods for intraocular diseases must be explored (Boroffka *et al.*, 1998; Bentley *et al.*, 2003; Scotty *et al.*, 2004).

Both A-mode and B-mode ultrasound have been used for ocular biometry. A-mode was recognized as more accurate than B-mode in detecting small lesions of the eye and to group lesions in histopathologic differential diagnoses (Ekesten 1994; Nyland and Mattoon, 1995). Echobiometric comparisons of the ocular segments between dolicocephalic and brachiocephalic breeds showed differences regarding the axial globe length (Cottrill *et al.*, 1989). Tuntivanich *et al.* (2007) showed by means of B-mode ultrasonography that the axial globe length rapidly increases up to 52 weeks of age, after which little change occurs until adulthood. Ekesten and Torrang (1995) found similar results in the axial globe length when the A-mode was used. However, in the A-mode technique, differences in the anterior and vitreous chambers measurements were found in unsedated dogs, compared to the sedated ones (Ekesten, 1994).

Ocular dimensions varied considerably and depended on species, age, and sex (Paunksnienė *et al.*, 1997; Osuobeni and Hamidzada, 1999). Axial ocular length was significantly longer in human males than in females (Nyland and Mattoon, 1995); the lens thickness was increased and anterior chamber depth was decreased with aging in both sexes in human (Lim *et al.*, 1992). This was also found in the dog (Ekesten, 1994). Later, it was reported that axial ocular length did not

depend on age or sex, but was significantly greater in dogs of large breeds (Paunksnis *et al.*, 2001). Dolichocephalic breeds had a longer eye globe than did mesocephalic breeds (Cottrill *et al.,* 1989). Ocular dimensions were measured for camel, cow, pig, sheep (Osuobeni and Hamidzada, 1999; Paunksnienė and Babrauskienė, 1996; Paunksnienė *et al.,* 1997; Ramsey *et al.,* 1999). It was observed that the eye of the one-humped camel was smaller than that of a horse, and cow but bigger than of a sheep, pig, dog and cat (Osuobeni and Hamidzada, 1999).

1.2 Statement of research problem

Data regarding intraocular structures of Indigenous Nigerian breeds, age and sex of dogs are not available. Considering the wide variety of breeds of dogs and their significance as experimental models for the study of human myopia (Black *et al.,* 2008; Williams *et al.,* 2011) as well as the increasing number of cataract surgeries performed daily in veterinary facilities, it becomes important to know the ultrasonographic intraocular measurement values of ocular parameters for Indigenous Nigerian dogs.

The specific statements of research problems are:

- There is no information on ocular sonographic examination in dogs in Zaria, Nigeria
- There is paucity of data on ocular sonography as a diagnostic tool in dogs in Nigeria.

1.3 Justification for the study

The knowledge of the ultrasonographic appearance and normal dimensions of the eye would serve as a basis for ultrasonographic examinations when ocular disease may have caused alterations in the dimensions and appearance of intraocular structures (Potter *et al.,* 2008). Although there are satisfactory data about ophthalmic ultrasound in Exotic dogs, ocular biometric data study, regarding the correlation of the sizes of intraocular structures and

intraocular pressure, gender, weight and size in Nigerian indigenous dogs are scarce to non available.

Ocular ultrasonography has been a useful and modern diagnostic tool for ophthalmic conditions in Veterinary medicine. In this vane, it has become imperative to establish baseline information on the normal ocular sonographic parameters of indigenous dogs in Nigeria. This research is therefore necessitated by the paucity of information on ocular ultrasonography in Nigerian indigenous dogs.

In the present research, ocular biometry of the anterior and vitreous chamber depth, lens thickness, and the axial globe length, as well as various chamber areas among normal eyes of different ages of some Indigenous Nigerian dogs in Zaria was studied by means of B-mode ultrasonography.

1.4 Aim of the study

This study aims to provide baseline data on the ultrasonographic examination of the eyes of Indigenous Nigerian dogs and to establish, if any, the differences in ocular pachymetry of dogs eyes based on age, sex, weight and intraocular pressure readings. The study also aims to demonstrate the use of ocular sonograph in examinatio of ocular conditions in Zaria. This study is also intended to increase awareness of this diagnostic modality for ocular examinations in animals as well as to encourage veterinary practitioners to include ocular ultrasound as an integral part of ophthalmologic examination.

1.5 Objectives of the study

The objective of this study is to establish mean data values for intraocular structures and analyse if there are differences for each variable within the different sex, age and weight/size of indigenous dogs in Zaria.

Specific objectives of the study are to

i. To demonstrate the use of ultrasound in ophthalmology in Nigerian indigenous dogs;
ii. To identify normal ultrasonographic biometry of the eyes of dogs in Zaria;
iii. To appreciate the difference in the ocular biometric sonographs in the dogs' eyes of different sex, age and weight.

1.6 Research hypothesis

Ultrasound is not valuable in ophthalmologic examination of Indigenous Nigerian dogs in Zaria.

Ultrasound cannot be used to obtain sonographic ocular biometry of the Indigenous Nigerian dogs' eyes.

Ocular ultrasound cannot be used to verify any significant relationship in ocular parameters of Indigenous nigerian dogs' eye in Zaria based on sex, age or weight/size differences.

CHAPTER TWO

2.0 LITERATURE REVIEW

2.1 Ocular Anatomy of a Dog

Dogs are dichromats just like other mammals, they have color vision equivalent to red-green color blindness in humans (Anon[4], 1998). Different breeds of dogs have different eye shapes and dimensions, and also have different retina configurations. Dogs with long noses have a "visual streak" which runs across the width of the retina and gives them a very wide field of excellent vision, while those with short noses have an "area centralis"- a central patch with up to three times the density of nerve endings as the visual streak-giving them detailed sight much more like a human's (David, 1984). Some breeds, particularly the sighthounds, have a field of vision up to 270° (compared to 180° for humans), although broad-headed breeds with short noses have a much narrower field of vision, as low as 180° (Davis, 1998).

2.1.1 Components of the Ocular Globe

The eye is composed mainly of two segments-anterior and posterior eye segments (Shaw, 2011). Three sections/chambers make up the anterior eye segment, namely:

1. The Anterior chamber- this is bounded by cornea anteriorly and iris and anterior lens surface posteriorly; filled with aqueous humor, which exits through the filtration angle (where the iris meets the cornea)
2. The Posterior chamber-this is bounded anteriorly by iris, posteriorly by lens capsule and anterior vitreous face; filled with aqueous humor which is produced by the ciliarybody (Shaw, 2011).

3. The Vitreous chamber-This is attached at the pars plana, posterior lens capsule and inner limiting membrane of retina; almost completely acellular; composed of hyaluronic acid, small amounts of collagen and rare hyalocytes.

Separating the anterior and posterior chambers is the iris and ciliary body, whereas separating the posterior chambers and the vitreous chamber is the lens (see figure 2 below). The Posterior segment of the eye is composed of retina and choroid (Miller and Evans, 2013). The Uvea is composed of iris, ciliary body (anterior uvea) and choroid (posterior uvea). The Fundus is a part of the retina and all associated structures that are visible with the ophthalmoscope; the retina of dogs and cats is termed holangiotic i.e it has tapetal (superior) and nontapetal (inferior) parts (Shaw, 2011).

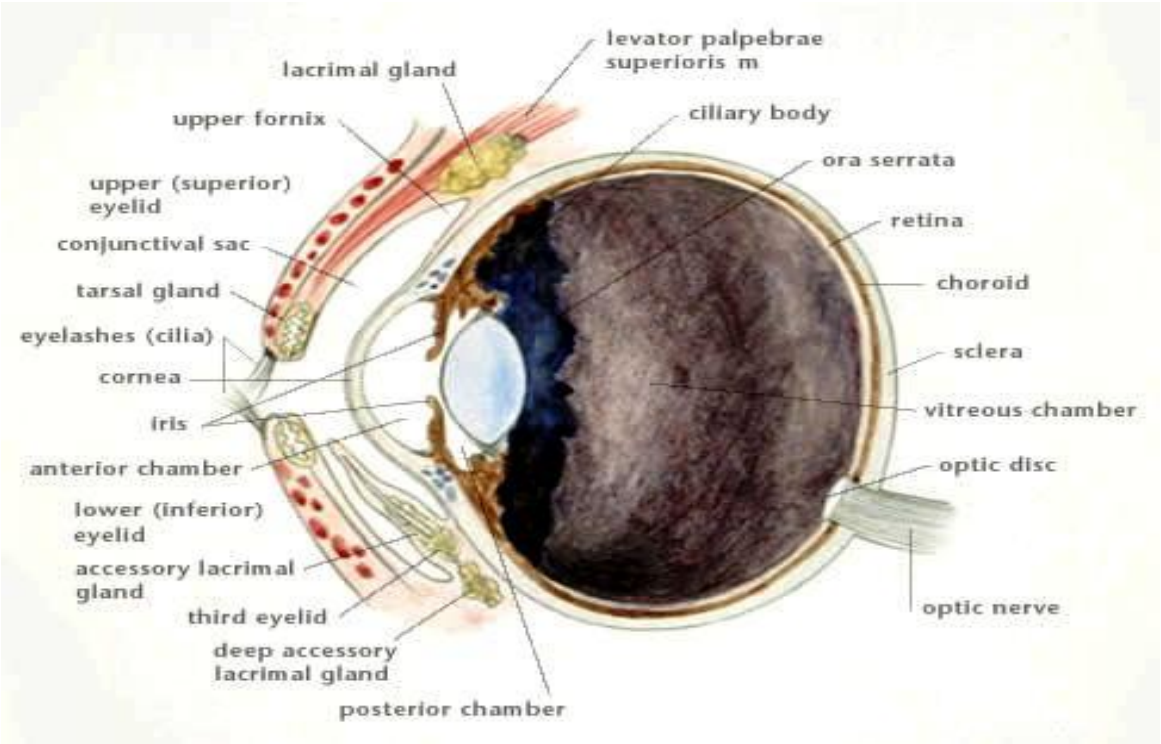

Figure 2.1a: Ultrastructure of the Dogs eye showing the essential components of the eye.

Source: iphohvet.com/Anatomy of Dog eye

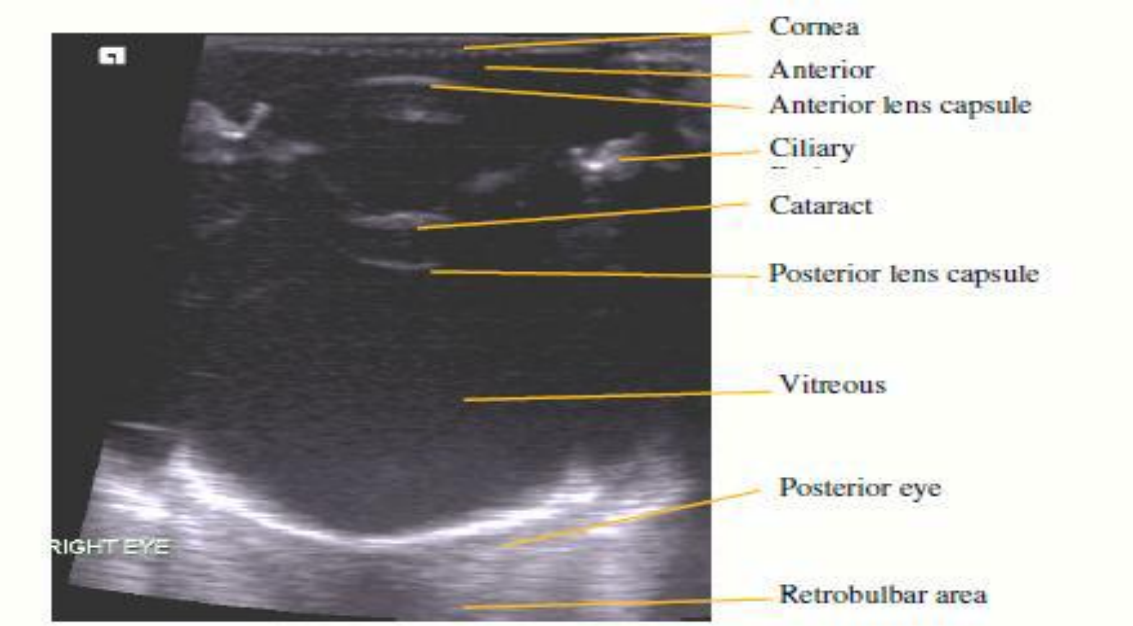

Figure 2.1b: Ocular Sonograph depicting intraocular structures that can be seen upon ocular ultrasonography

Source: Chopin, 2011

The ocular Orbit is composed of seven extraocular muscles namely dorsal rectus muscle, dorsal oblique muscle, lateral rectus muscle, medial rectus muscle, ventral rectus muscle, ventral oblique muscle, retractor bulbi muscle (Wrycha, 2014).

2.1.2 Ocular Structures

The Eyelid

The eyelid has Cilia which project from upper lid margin; not found on lower lid margin in dogs or cats. It has Meibomian glands, present in both eyelids and produce superficial oily layer of tear film. It also has Ciliary glands which are apocrine sweat glands that secrete into hair follicles or sebaceous glands or directly onto lid margin (Dyce *et al.,* 2010; Anon[1], 2014).

The muscles of the eyelid include: Orbicularis oculi which acts to close eyelids; Levator palpebrae superioris which is one of the most important muscle that acts to retract the upper eyelid; Palpebral and bulbar conjunctiva which contain Goblet cells that produce the glycoprotein layer of the tear film (Miller and Evans, 2013; Wrycha, 2014).

The Nictitans

This is the gland of the third eyelid and made up of mixed seromucous gland in the dog, serous in the cat and it contributes significantly to the aqueous production of the tear film. It has cartilage which reinforces the nictitating membrane. It also has lymphoid nodules which vary with age and antigenic stimulation in number, size and location; it is especially prominent on bulbar surface of third eyelid (Miller ad Evans, 2013). The dog has no specific muscle that draws the third eyelid across the globe such as is present in the cat; cat has 9 strands of smooth muscle fibers that extend into the third eyelid (Dyce *et al.,* 2010).

The Cornea

This is moistened by a tear film on the superficial oily layer (Meibomian glands), central aqueous layer (gland of third eyelid) and a thin glycoprotein layer covering cornea (Goblet cells). The corneal epithelium is a stratified squamous, non-keratinized. The basal lamina and superficial stroma is collagenous acellular zone. The corneal stroma is the lamellae which are composed of fine, evenly spaced collagen fibers. The Descemet's membrane is the basement membrane of posterior epithelium, whereas the endothelium is a simple cuboidal epithelium (Shaw, 2011; Wrycha, 2014).

The Iris

The anterior surface of the Iris is lined by discontinuous layer of stromal cells and there is no boundary between anterior chamber and iris (Miller and Evans, 2013). The stroma contains fibroblasts, collagen, nerve fibers, smooth muscle, melanocytes and blood vessels; cats have a pigment called pheomelanin, a lighter colored pigment that consists of long and thin filaments compared to round granules contained in typical melanocytes. A posterior epithelium and dilator muscle which are radially arranged smooth muscle fibers is located posterior to sphincter muscle which in turn are circumferentially arranged smooth muscle fibers. The Pupil is usually round in the dog but slit-like in the cat (Shaw, 2011).

The Structures of the Filtration Angle

This includes the primary pectinate ligaments (which anchors the anterior base of the iris to the inner peripheral cornea), the secondary pectinate ligaments, the corneoscleral trabecular meshwork (which consists of small trabeculae that in turn are separated by small intertrabecular spaces), the drainage vessels (compose of a deep scleral vascular channels-angular aqueous

plexus which drain to trabecular veins, then into the scleral venous plexus and the episcleral veins), the uveal trabecular meshwork (comprises most of the inner iridocorneal angle in area; forms the ciliary cleft), the ciliary cleft- bordered by secondary pectinate ligaments on one side, corneoscleral trabecular meshwork on the other side, anteriorly by the ciliary body and posteriorly by the uveal trabecular meshwork (Abrams, 2001; Shaw, 2011; Wrycha, 2014). See figure 3 bellow of the components that comprises the nasolacrimal apparatus of the dog.

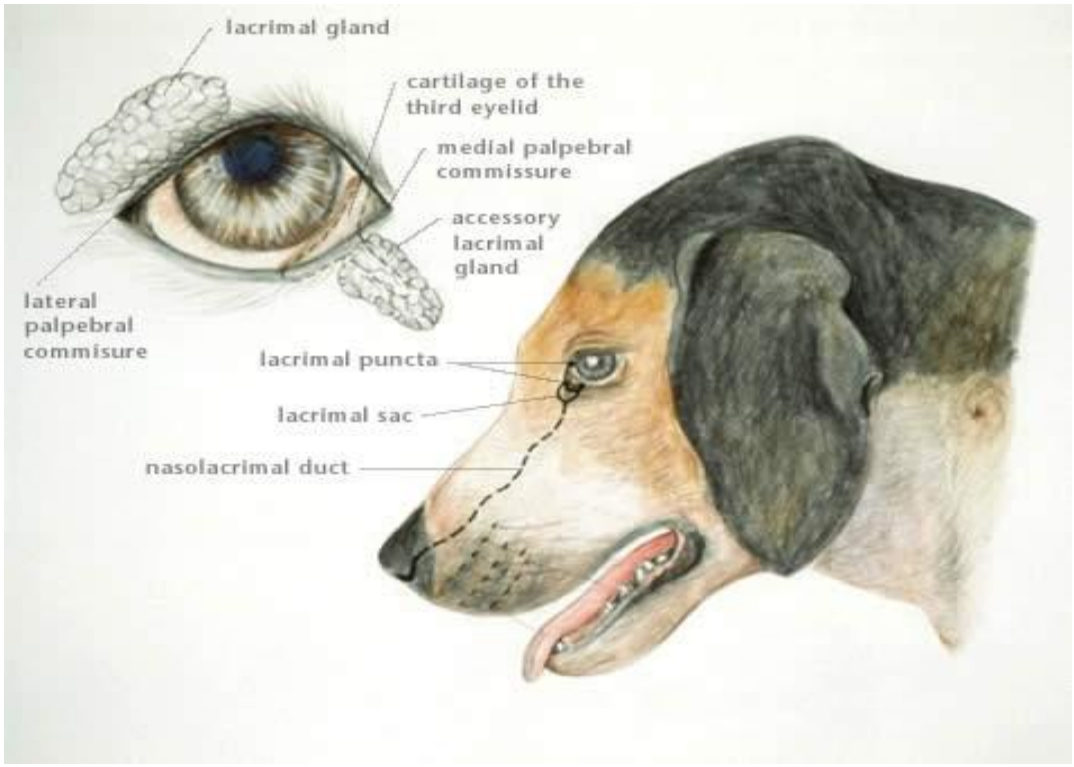

Figure 2.2: Components of the Nasolacrimal apparatus of the Dog

Source: iphohvet.com/Lacrimal Apparatus of Dog

The Ciliary Body

Ciliary body produces aqueous humor, which flows into posterior chamber, then thru the pupil into the anterior chamber and exits the eye via the drainage angle (Abrams, 2001; Shaw, 2011). It has two parts - a Pars plicata which is the ruffled portion that produces aqueous humour, whereas Pars plana is the smooth portion that produces vitreous. The ciliary epithelium has an outer pigmented and an inner non-pigmented portion; non-pigmented portion produces aqueous, hyaluronic acid, zonular ligaments and basement membrane. When the ciliary muscle contracts with parasympathetic stimulation, tension is decreased on the zonular fibers supporting lens and lens becomes more spherical (shorter focal distance) because of the native elasticity of the lens capsule. The zonular ligaments is made from polymerized units of fibrillin and scant collagen, it supports the lens (Shaw, 2011).

The Lens

This is made up of Lens capsule, a basement membrane secreted by the cells of the lenticular epithelium. The Lens epithelium is located only on the anterior surface of the lens. Lens fiber is hexagonal in shape and interdigitate at the sutures. The Sutures are “Y” shape on the anterior surface and inverted “Y” shape on the posterior surface (Wrycha, 2014).

The Choroid

This entails tapetum which is cellular in all carnivores; rodlets contain high levels of zinc-cysteine in the dog and zinc-riboflavin in the cat. Cat tapetum is thicker than the dog tapetum, and dog tapetum reflects light at a different wavelength and less efficiently than the cat (Shaw, 2011). The Choriocapillaris is the major blood supply for the outer retina, one of the most oxygen dependent tissues of the body (Miller and Evans, 2013). The Bruch’s membrane is the

structure that separates choroid and retina. It is composed of basement membrane of the pigmented epithelium of the retina, some intermediate connective and elastic tissue, and the basement membrane of the choriocapillaris. Choroidal vessels run parallel to each other (Shaw, 2011).

The Retina

The area of the retina in primates (including humans) that is rich in cone photoreceptors and is responsible for fine, sharp, straight-ahead vision is the Macula. The Fovea is the area where there is a depression formed by thinning of the inner retinal layers to allow light to directly shine on the photoreceptor layer (Shaw, 2011). The structures of the fovea is made up of Retinal pigmented epithelium; outer segment of rods and cones (cats have thicker rods than dogs), and an inner segment of rods and cones (contains mitochondria and rough endoplasmic reticulum); outer limiting membrane (which is a tight junctions between Müller cells and photoreceptor cells); outer nuclear layer (which are cell bodies of rods and cones), cone nuclei are larger and near the outer limiting membrane; outer plexiform layer (which synapses between photoreceptors and integrating neurons); an inner nuclear layer (which are cell bodies of integrating neurons, Müller cells, horizontal, bipolar and amacrine cells); an inner plexiform layer which synapses between integrating neurons and dendrites of optic tract neurons (ganglion cells); the ganglion cell layer which are cell bodies of optic tract neurons; nerve fiber layer (afferent fibers that form the optic nerve); and an inner limiting membrane which is the basal lamina secreted by Müller cells and attached to vitreous (Evans, 1993).

Retinal Blood Vessels

In the dog, 20 cilioretinal arterioles radiate from optic disc and from 3-4 major veins. It also has very short central retinal vein and the retinal vessels tend to be more tortuous than in other animals. In the cat however, there are 3 major pairs of cilioretinal arteries and veins which are dorso-medial pair (curve laterally), ventral-medial pair and ventral-lateral pair (Shaw, 2011; Miller and Evans, 2013).

The Optic Nerve

This is made up of the optic disc, lamina cribrosa which is the area where nerve exits through sclera, the myelinated and nonmyelinated axons (ganglion cell layer has unmyelinated axons; axons become myelinated at optic disc) and the meninges (Shaw, 2011; Miller and Evans, 2013). The meninges is made up of 5 parts. These include the dura mater which is continuous with cranial dura and merges anteriorly with outer 2/3 of sclera. The arachnoid and its trabeculae are closely associated with dura matter. The arachnoid cap cells cover the arachnoid to form the principle part of the arachnoid, and it support the dura from the subarachnoid space. The Pia matter is closely applied to the surface of the optic nerve and it sends septa into the optic nerve. Lastly, the Pia trabeculae originate in posterior lamina cribrosa region from the pia and it surrounds the internal nerve fascicles.

The Sclera

The sclera of the dog is thickest at the center of eyeground. It is similar to that of the cat, but only thinner. The entry point of optic nerve is 0.3-0.4 mm in the dog but 0.13-0.60 mm in cats; the equator of globe is 0.12-0.20 mm in dogs but 0.09-0.20 mm in cats; and the place of crossing in cornea for dogs is 0.6 mm whereas it is 1.1 mm in the form of a ring 5-7 mm wide in the cat.

The thickness in the cat at the center of eyeground is 0.09-0.20 mm (Dyce *et al.*, 2010; Shaw, 2011). The limbus is corneoscleral junction and it is the site of corneal stem cells.

2.2 Ophthalmic Examination

The first objective of ophthalmic examination is to determine the visual status and potential of each eye. Ophthalmic examination is usually preceded by general examination, because some systemic diseases may manifest ocular signs (Beránek, 2014). The ophthalmic examination should be carried out in a repeatable and sequential manner to ensure that nothing is overlooked. Examining the unaffected eye prior to the affected eye in animals with unilateral disease ensures that it is not forgotten and provides information on the individual patient's normal ocular appearance (Maggs, 2013).

2.2.1 Special Ophthalmic Techniques

Some special techniques that can be used for the examination of the eyes include Schirmer tear test (STT), Aqueocentesis, Fluorophotometry, Tonometry, Biomicroscopy, Ophthalmoscopy, Gonioscopy, Doppler indirect blood pressure measurement, Electroretinography, Ocular ultrasonography etc (Baránek 2014).

The Schirmer tear test (STT) records basal and reflex tearing as number of millimeters of wetting of a strip of absorbent paper placed in the lateral, ventral conjunctival fornix for one minute (Maggs, 2013). The lateral fornix is used to ensure that the strip lightly abrades the cornea and produces reflex tearing. If the strip is placed more medially, it may be prevented from touching the cornea by the third eyelid. The STT should be performed prior to application of *any* topical solutions, particularly anesthetic drops. General anesthesia and sedation also cause a temporary (at least 48 hours) depression of normal tearing. Normal STT values for dogs are well

established; a STT reading of > 15 mm in 60 seconds is considered normal. Wetting of less than 10 mm in 60 seconds is abnormal and is usually associated with evidence of keratoconjunctivitis. Wetting of 10-15 mm in 60 seconds represents a "gray zone" and warrants careful assessment in light of clinical signs. Reassessment at a later date should also be considered in these situations. The range of reported STT values in normal cats (3-32 mm; mean = 17 mm in 60 seconds) is much wider and more difficult to interpret than in dogs. However, experience suggests that lower readings than the reported mean can frequently be expected in completely normal cats (Strubbe and Gellat, 1999). This is probably due to autonomic control of tear secretion and short-term alterations in tear flow due to stress in the examination room. Feline STT values should still be recorded, but interpreted in conjunction with clinical signs.

Application of fluorescein dye to the cornea can yield a large amount of information (Strubbe and Gellat, 1999; Maggs, 2013). A few drops of irrigation solution are trickled over a strip impregnated with fluorescein to liberate dye onto the cornea. Care should be taken not to touch the strip onto the cornea. Excess dye is then rinsed from the corneal surface and the eye examined with either white or cobalt blue light. This simple, water-soluble dye has great affinity for the hydrophilic corneal stroma but is not absorbed by epithelial cells or Descemet's membrane. Its most common use therefore is identification and characterization of corneal ulcers (Martin, 2001). Excitement of the fluorescent dye with a cobalt blue light can assist with identification of minor lesions; however excessive dye must be adequately rinsed from the cornea to avoid over-interpretation of normal pooling. Small, "scuffed" areas of corneal epithelium are occasionally seen following the STT.

Passage of dye down the nasolacrimal duct is referred to as the Jones test and is used to assess functional and anatomic patency of the nasolacrimal apparatus (Maggs, 2013). Seidel's test also

utilizes fluorescein stain. This test is used to assess integrity of the cornea following suspected penetrating trauma or ulceration and to guide decisions regarding management of such wounds. In this case, excessive dye is not rinsed from the cornea but is examined with a cobalt blue light and magnification. Leakage of aqueous humor will cause small rivulets to form in the fluorescein dye pooled on the corneal surface.

Rose bengal stain is retained by devitalized corneal or conjunctival epithelial cells. Recent studies have suggested that even changes in amount or quality of some normal tear film components such as mucin and albumin can cause otherwise viable epithelial cells to retain rose bengal stain (Maggs, 2013). Its clinical utility is therefore detection of subtle epithelial abnormalities as seen in keratoconjunctivitis sicca ("dry eye") or dendritic ulcers that occur with feline herpesvirus keratitis. Rose bengal and fluorescein stains may affect culture and virological results and should be applied following collection of microbiological samples. Rose bengal is also epitheliotoxic and may cause discomfort in some animals, and therefore should be reserved for cases where it may provide useful additional information.

Retropulsion of the globe is a simple but useful method for investigating orbital disease (Strubbe and Gellat, 1999). This is performed by applying gentle digital pressure to both globes in a posterior direction through closed lids. The resistance to retropulsion and the resilience with which the globes "spring" back against the retropulsive force are subjectively assessed. This is quite distinct from digital tonometry where the globe is gently compressed against the orbital rim thus providing a crude and unreliable assessment of intraocular pressure (IOP). Retropulsion of the globe in a variety of directions may further localize orbital masses or outline smaller masses that would be missed by direct caudal retropulsion only (Maggs, 2013).

Assessment of intraocular pressure (tonometry) is essential for differentiation of the two major, vision-threatening conditions in which red-eye is the hallmark feature – uveitis and glaucoma (Gellat, 2007; Reinstein *et al.,* 2009). The availability of easily used applanation tonometers makes measurement of intraocular pressure (IOP) easier in all species, particularly cats (Leiva *et al.,* 2006; Gorig *et al.,* 2006). The pressure within the eye, the intraocular pressure (IOP), is based on the balance between production and drainage of aqueous humour (Abrams, 2001). A balanced intraocular pressure is required to keep the eye in shape, provide nutrients to intraocular structures and maintain normal function of these structures. Increased intraocular pressure occurs when there is a defective drainage of aqueous humour from the eye. Decreased intraocular pressure is the result of either reduced production, or in case of injury, leakage through a defect in the globe wall.

2.3 Tonometry

Tonometry is the measurement of intraocular pressure, IOP (Leiva *et al.,* 2006). Tonometry is essential in the work-up of animals with ocular conditions. Thus, a reliable tonometer should be standard equipment in all companion animal practices. There are three methods of measuring IOP: Indentation, applanation and rebound tonometry (Reinstein *et al.,* 2009). Indentation tonometers, such as Schiotz, indent the corneal surface and provide a measurement that can be converted for use in dogs by using the accompanying human conversion table (Miller and Picket, 1992). Applanation tonometry, such as TonoPen VET (Reichert) ®, measure IOP by flattening the corneal surface and are commonly used in general practice. Rebound tonometers, such as TonoVet, iCare ® measure IOP by projecting a small probe at the corneal surface and analyzing the characteristics of its rebound. Rebound tonometers have been shown to be as accurate as applanation tonometers (Gorig *et al.,* 2006; Leiva *et al.,* 2006). Recommended types include

rebound tonometer with a magnetized probe that bounces off the cornea when the cornea is touched with the probe (TonoVet) and applanation tonometer that measures the counter pressure when the probe touches the cornea (e.g. TonoPen). The results of IOP measurements must always be correlated with clinical findings and must be compared with IOP in the fellow eye. Normal IOP in dogs is 15-25 mmHg; whereas normal IOP in cats is 15-30 mmHg. Older animals have lower IOP than younger ones. Debilitated animals have lower IOP than healthy animals. IOP values increase if the animal is stressed; therefore, IOP values increase if the animal is firmly restrained during measurement. If IOP has been elevated over a period and the eye has become buphthalmic, the eye will not shrink noticeably even if the IOP is lowered. IOP > 30 mmHg over some days damages the optic nerve and retina; IOP > 40 mmHg is painful and causes enlargement of the globe (buphthalmia); IOP > 40-50 mmHg leads to paralysis of the sphincter muscle of the iris and causes mydriasis. IOP exceeding 50 mmHg could trigger blindness (Strubbe and Gellat, 1999). Thus, tonometry now has become an essential diagnostic procedure during eye examinations in animals. Intraocular pressure (IOP) measurement has an important role in the diagnosis of ocular diseases and monitoring of glaucoma in dogs. The owner doesn't usually notice the increasing IOP of his pet until the animal shows severe clinical symptoms, such as marked depression, blepharospasm, epiphora, corneal oedema, and episcleral congestion (Renwick, 1993).

In their findings, Miller and Picket in 1992 discovered that unlike the Schiotz tonometer, the TonoPen measures IOP directly and does not require any conversion. It can also be held horizontally and therefore allows measurements to be performed with the patient's head held in a normal, relaxed position. Finally, it has a small probe that permits easy measurement of IOP in even the smallest feline and pediatric canine eyes. Correct patient restraint is essential for

accurate tonometry (Leiva *et al.,* 2006; Paul *et al.,* 2006). The patient should be lightly restrained so as to not artificially raise IOP. In particular, direct pressure on the jugular veins and on the globe itself via the eyelids should be avoided. Recent study demonstrated that the body position can affect IOP readings in dogs without glaucoma; therefore, it is important to keep the dog's position consistent during the IOP measurement (Broadwater *et al.,* 2008).

The number of readings required to achieve an average varies depending on how disparate the readings are from each other and from the normal physiologic range. A small digital screen at the end distant from the tip displays the IOP in mmHg and provides an estimate of the "reliability" (coefficient of variance) of the result. This appears as a small bar above one of 4 percentage readings. This bar should be above the 5% mark or tonometry should be repeated on that eye. Across large populations, normal canine and feline IOP is reported as approximately 10-25 mmHg. However, significant variation is noted between individuals, technique, and time of day. Comparison of IOP between right and left eyes is therefore critical to interpretation of results. A good rule of thumb is that IOP should not vary between eyes of the same patient by more than 20% (Gorig *et al.,* 2006).

The obvious application for the TonoPen is the diagnosis of glaucoma where IOP is generally elevated. However tonometry is also used to diagnose uveitis; in which IOP is lowered due to loss of function of the inflamed ciliary body. Perhaps the most important role for tonometry is the monitoring of progress of these diseases and the adjustment of medications based on these data. Because IOP measurement obtained using different instruments vary (Gorig *et al.* 2006), it is recommended that the same instrument be used consistently when monitoring a patient's IOP (Reinstein *et al.,* 2009).

2.4 Ophthalmoscopy

Ophthalmoscopy is part of the complete ophthalmic examination procedure and involves the visualization of the fundus (Petersen-Jones and Crispin, 2002; Grahn *et al.,* 2004). The fundus is composite picture formed by the 3 basic tunics of the vertebrate eye (neurosensory, vascular, and fibrous) superimposed on one another. As viewed ophthalmoscopically, these components are the retina, choroid, and sclera. Normal fundic findings can be highly variable and are influenced by the animal's species, breed, age, and coat color (Maggs *et al.,* 2008). Ability to routinely and reliably evaluate the posterior segment of the eye is essential in any patient with a visual disturbance or for which the differential diagnose includes systemic infectious disease, vascular disorder, hypertension, or central nervous system disease.

Both direct and indirect ophthalmoscopy can be used to examine the eye (Grahn *et al.,* 2004; Schoster, 2006). In the indirect ophthalmoscopy, which could be either monocular or binocular, there is wider field of view than in the direct, the examiner’s face is a safe distance from patient, but the image is upside down and backwards as viewed in lens. The binocular method allows for 3 dimensional images, whereas the monocular method is great for quick clinical survey of fundus (Grahn *et al.,* 2004). The direct ophthalmoscopy is characterized by small field of view but high magnification, the panoptic head gives larger field of view than in the direct ophthalmoscope. However, examiners face is very close to patients face (Petersen-Jones and Crispin, 2002).

Mydriasis is the artificial dilation of pupil and this is necessary for full view of fundus during ophthalmoscopy (Maggs *et al.,* 2008). Anticholenergic drops particularly short acting only, not atropine, are used, e.g Tropicamide 1% is drug of choice (lasts 4 - 6 hours) and allows visualization of the fundus to see the optic nerve (size), vessels (engorgement, attenuation, hemorrhage), retina (tapetal hyper/hyporeflectivity, retinal detachment).

Restraint during opthalmoscopy should involve as minimal stress as possible, minimal restraint is best; ensure no restraint around the patient's neck and no pressure around the eye. Usually, small movements make huge differences (Gellat, 2000).

Conditions that can be seen upon ophthalmoscopic examination include "cherry eye" or prolapse of the third eyelid, corneal ulceration, keratoconjunctivitis Sicca (KCS), cataracts, glaucoma, e.t.c. (Grahn *et al.,* 2004).

During ophthalmoscopy and interpretation of findings, the fundus should be viewed systematically, assessing for

1. Reflectivity (Uniformly or focally increased; uniformly or focally decreased)

2. Vascularity (Attenuated; engorged; tortuous; out of focus due to elevation or depression)

3. Optic nerve (Color; degree of myelination; raised; depressed)

4. Pigmentation of tapetal versus nontapetal areas

2.5 Ocular Ultrasonography

Diagnostic ocular ultrasound is a two-dimensional imaging technique used to determine anatomical standards and pathological alterations, especially when ocular and intraocular opacities prevent the assessment of the posterior segment of the eye (Gelatt-Nicholson *et al*., 1999; Petite, 2009).

Ophthalmic ultrasound is an indispensable tool in veterinary ophthalmology because it helps in diagnosing alterations that are not identified in the routine eye examination, especially when there is opacification of the transparent media of the eye (cornea, aqueous humor, lens and vitreous humor) (Gonçalves *et al*., 2000; Scotty *et al.,* 2004). It plays an important role before

cataract surgery; it contributes to satisfactory postoperative results making it useful for the evaluation of the posterior segment and also with respect to the selection of patients who will be submitted to cataract removal. It also allows the establishment of the proper intraocular lens to be used in surgery lens replacement (McMullen & Gilger, 2006; Gift *et al.,* 2009; Ribeiro *et al.,* 2009).

Common indications for ocular ultrasound include opacification of the anterior segment such as the cornea or lens that inhibits ophthalmic examination; exophthalmos; abnormal retropulsion of the eye; displacement of the globe and trauma (Seiler, 2011). Advantages of ultrasound include the wide availability and the fact that it does not require general anesthesia. In fact, heavy sedation or anesthesia should be avoided for ultrasonographic examination of the eye, as the globe tends to rotate and the nictitating membrane may be elevated, complicating the examination (Spaulding, 2008).

2.5.1 Historical Reviews on Diagnostic Ocular Ultrasonography

In 1956, Mundt and Hughes used an A-scan on an intraocular tumor, demonstrating the possible use of ultrasound in ophthalmology. Soon a body of research was developed on the sound velocities of various tissues and compartments of the eye, and in the 1960s, ultrasound began to be used to measure distances in the eye (Bentley *et al.,* 2003). B-scan instruments developed in the 1970s were originally used through closed eyelids. Ossoinig in the 1960s developed the standardized A-scan, which is used to differentiate tissues, particularly tumors. In dogs, ocular ultrasonography was first used in 1968 (Davidson and Nelms, 1999).

In the 1990s, high frequency ultrasound was developed, which greatly improved the resolution and examination of anterior segment structures. Recent developments include the digitization of

ultrasound so that three-dimensional imaging is possible (Bentley *et al.,* 2003). Lately colour Doppler ultrasound has become a part of the present day's Standardized echography (Kumar and Goel, 2011).

2.5.2 Indications for Ocular Ultrasound

Indications for ocular ultrasound include any clinical entity which impedes visualization of all or a portion of the globe and retrobulbar region. Severe corneal edema, corneal lacerations or ulcerations, cataracts or ocular masses may preclude visualization of deeper structures with traditional ophthalmoscopic methods (Whitcomb, 2002). Another common indication for ocular ultrasound is disparity in ocular size or a protruding globe. Ultrasound is important in these cases to differentiate between enophthalmus, buphthalmus, or exophthalmus due to the presence of retrobulbar masses. In cases of ocular trauma, ultrasound can be used to evaluate the integrity of the globe. Ultrasound can also be used to confirm ophthalmoscopic findings, such as retinal detachment or early cataractous changes. Considering that mature and diffuse cataract do not allow a useful visualization of the posterior segment of the eye, ultrasonography is a valuable tool to evaluate vitreous and retinal conditions, as well as the stage of cataracts (Van der Woerdt *et al.,* 1993; Brazitikos *et al.,* 1999).

2.5.3 Importance of Diagnostic Ocular Ultrasonography

Some of the common eye conditions where diagnostic ultrasonography is helpful are:

A. Hyphema is represented by the presence of blood in the anterior chamber. The ultrasound image shows small echogenic areas anteriorly due to the bleeding (Ferrer, *et al.,* 2013).

B. Hypopyon (pus in the anterior chamber) is represented as an echogenic band in the anterior chamber due to the collection of purulent debris (Ferrer, *et al.,* 2013).

C. Dense cataract which when associated with marked and rapid decrease in visual acuity, afferent pupillary defect, diabetes mellitus, uveitis, trauma and myopia warrants the need to rule out retinal detachment (RD), intraocular tumor with calcification, posterior staphyloma, vitreous haemorrhage, asteroid hyalosis, optic nerve head cupping, abnormal growth over optic nerve head or axial length disparity (Ossoining, 1984; Jakobiec and Font, 1984).

D. Vitreous hemorrhage can result from tearing due to vitreoretinal traction, diabetic retinopathy, vasculitis, subarachnoid hemorrhage, and blunt trauma to the eye. Later, the hemorrhage may organize and develop fibrinous membranes (Ferrer, *et al.*, 2013). B-scan reveals widespread low-intensity echoes in the vitreous chamber, which show marked after-movement on dynamic scanning. In vitreous haemorrhage, on echo evaluation one may pick up retinal tear with detachment, disciform degeneration, and melanoma, fibro-vascular fronds with tractional RD or sub-hyloid haemorrhage (Bryne and Green, 1992).

E. Ocular sonography can also be used to determine the cause of leucokoria whether due to retinoblastoma, Coat's disease; Retinopathy of prematurity or old haemorrhage can be deduced (Giglio and Sherman, 1979).

Choroidal melanoma, the commonest primary intraocular tumor in adults, arises from the choroid and ciliary body. Most of these lesions arise posterior to the equator of the eyeball (Rai *et al.* 2007). On B-scan, it is seen as a lenticular-shaped mass arising from the choroid. Choroidal melanoma may be associated with retinal detachment. The tumor has a bilobed or 'cottage-loaf' appearance, which is caused by waisting as it breaks through Bruch's membrane (Ferrer, *et al.*, 2013). An area of excavation under a small posterior wall mass is indicative of melanoma, although this feature is not always present.

Benign melanocytic tumors include nevi and melanocytomas. A melanocytoma typically is heavily pigmented. They, too, have a dome-shaped configuration but, in contrast to melanoma, are highly reflective and do not have internal vascularity (Ferrer, *et al.*, 2013). Unfortunately, small melanomas may show an absence of low internal reflectivity, and, consequently, it may be difficult to differentiate a small benign lesion from a similar sized malignant one.

F. In inflammatory pathology: one of them, with granulomatous appearance, revealed as Vogt Koyanagi Harada syndrome. Vogt-Koyanagi-Harada (VKH) disease is a rare multisystem disorder that affects the eye, inner ear, skin and meninges. The characteristic ocular manifestations are severe bilateral panuveitis with iridocyclitis, serous retinal detachment, diffuse choroidal swelling and optic disc hyperemia (Agrawa and Biswas, 2001; Ferrer *et al.*, 2013). These findings are typically bilateral, but the severity may be asymmetric. Ultrasonographic image displays the lobular nodular thickening of the posterior ocular wall and the mixed detachments of the ocular membranes due to the inflammatory granulomatous lesions. In vitritis/endophthalmitis, ocular sonography helps in ruling out foreign body (FB) and rupture of intraocular cyst and helps in assessing the response to treatment (Bryne and Gendron, 1991).

G. In a painful blind eye, it is indicated to rule out uveal melanoma, old RD with chronic uveitis, intraocular/subretinal cyst, lens dislocation, failed RD surgery, inflamed phthisical eye, e.t.c (Jakobiec and Font, 1986). In patients planned for penetrating keratoplasty with opaque anterior segment (Rai et al., 2007), ocular sonography is indicated.

H. Patients with clear media where on indirect ophthalmoscopy suspicious lesions suggestive of intraocular tumors like choroidal melanoma, haemangioma, metastatic carcinoma, osteoma, etc are seen (Brandy *et al.*, 2008). Orbital screening should be performed in patients with abnormal choroidal folds and posterior scleritis.

Macular degeneration affects older adults, and the macula is affected primarily, so central vision is lost (Shaw, 2011). There are two types: the wet form in which new blood vessels invade the sub retinal space from the choroid and leak fluid thus separating the retina from the RPE, thereby leading to photoreceptor degeneration; and the dry form in which cellular debris (drusen) builds up between the RPE and the retina leading to photoreceptor degeneration

Drusen (calcified plaques within the optic disc) are usually bilateral and asymptomatic, but they may cause atrophy of the optic nerve. Hyperechoic lesions at the papilla with acoustic shadowing are seen at ultrasound (Rai *et al.*, 2007; Shaw, 2011). The presence of calcifications and their location are the clues to the diagnosis.

A coloboma of the optic nerve head involves a congenital defect in its structure occurring as a result of mal closure of the ocular fissure. At ultrasound, a defect in the optic disc and a papillary excavation are seen (Ferrer *et al.*, 2013). It may be mild, in which case there is a defect in the optic nerve substance, usually inferiorly. This defect may be more extensive and involve the juxtapapillary choroid and retina. It may be associated with a pit deformity and with a juxtapapillary staphyloma. This latter term refers to an out-pouching of the ocular wall around the optic nerve head.

I. In oculo-orbital trauma, it is imperative to look for sclerochoroidal rupture with RD, intraocular/orbital foreign body, lens displacement, optic nerve avulsion and orbital haemorrhage (Rai *et al.*, 2007).

Retinal detachment (RD) is usually due to a break or tear in the retina; it may also be caused by vitreoretinal traction due to contracting membranes or because of subretinal exudates (Ferrer *et al.*, 2013). The detached retina is usually attached to the firm anchoring points of the ora serrata

anteriorly and the optic nerve head posteriorly and, consequently, a total RD shows a funnel (V) shape. Dynamic scan may reveal an undulating motion of the retinal membrane. RD can be acute or chronic, total or partial (Rai *et al.*, 2007). In acute RD the membrane is thin and mobile. Over time the membranes become thicker and echogenic, and with eye movements become rigid. Arterial and venous flows can be seen inside. There are three types of RD, depending on the underlying mechanism: rhegmatogenous, or retinal tearing; tractional, or separation of the retinal layer due to tugging by vitreous membranes; and exudative, in which blood, fluid, or a lesion is present in the subretinal space. In the presence of RD, the subretinal space and vitreous should always be examined because they may contain blood, exudative fluid, or tumor, thus providing the cause of the detachment, a determination that is usually not possible at ophthalmoscopy. In some patients with partial RD, the request for ultrasound was to rule out a neoplasm causing detachment (Bedi *et al.*, 2006). Choroidal detachment is caused by accumulation of fluid in the potential suprachoroidal space, which is located between the choroid and sclera and extends from the ora serrata to the optic disc, but the choroid is fixed to the sclera by vortex veins. At ultrasound, the bands visible in the choroidal detachment are typically thick and rigid, convex (in obtuse angle), and not "anchored" on the optic disc but at the level of vortex veins. Arterial flow can be seen in the thickness of these membranes.

Vitreous detachment is seen in elderly individuals. It results from gel liquefaction and collection of fluid in the subvitreal space, which in turn, results in vitreous detachment. It is seen frequently in cataractous eyes on B-scan (Ferrer *et al.*, 2013). The posterior vitreous detachment or hyaloid detachment appear as avascular membranes and reduced volume of vitreous gel with very low echogenicity that also exhibit a typical fluid movement when the patient performs eye movement. Vitreous detachment can be observed either associated or not with hemovitreous.

J. In postoperative cases to assess endophthalmitis/toxic anterior segment syndrome, lens fragment/ intraocular lens(IOL) displacement into the vitreous cavity, choroidal detachment/ haemorrhage, status of retina post RD surgery, etc (Whitcomb, 2002).

Scan ophthalmic ultrasonography can be considered as an important adjuvant for the clinical assessment of various ocular and orbital diseases. With understanding of the indications for ultrasonography and proper examination technique, one can gather a vast amount of information not possible with clinical examination alone (Ferrer *et al.,* 2013).

2.5.4 Principles of ultrasound

Ultrasound is an acoustic wave consisting of an oscillation of particles within a medium. Ultrasound waves have frequencies greater than 20 KHz (> 20,000 oscillations/second), and are inaudible to humans (Bentley *et al.,* 2003). In ophthalmic ultrasound, frequencies are typically between 8 MHz to 50 MHz (with higher frequencies in development). Higher frequency results in higher resolution, but at the price of tissue penetration, as shorter, more frequent wavelengths cannot penetrate tissue as far as longer wavelengths (Giglio, 1977 and Bentley *et al.,* 2003). Most standard B-scan probes for globe imaging are 10 MHz, which can penetrate about 40 mm. High resolution probes are generally around 20 MHz and penetrate 10 mm. Ultrasound biomicroscopy is usually considered to be 50 MHz or higher, but tissue penetration is only 7 mm (Bronson and Fisher, 1976; Bentley *et al.*,2003).

An A-scan is a one-dimensional display where echoes are depicted as spikes arising from baseline. A thin, parallel sound beam passing through a small point in the eye forms an A-scan (Coleman *et al.,* 1977). The greater the difference between interfaces, the higher the spike will be, hence the name Amplitude-scan, or time amplitude display. A B-scan on the other hand, is

essentially an oscillating A-scan that passes through a cross-section of tissue. The echoes in a B-scan are represented as dots rather than spikes. The configuration of the dots and the brightness of the dots create the image. The greater the difference between interfaces or the stronger the echo, the brighter the dot will be, hence the name Brightness scan, or brightness intensity-modulated display (Rai *et al.,* 2007).

To create ultrasound images, an instrument must have a pulser, a transducer, a receiver, and a display screen (Coleman *et al.,* 1977, Bentley *et al.,* 2003). An ultrasound probe consists of a piezoelectric element, which converts mechanical energy to electrical energy and vice versa. The piezoelectric crystal is electrically stimulated, causing a mechanical vibration. The vibration leads to the release of a longitudinal sound wave that passes through the tissue. After each vibration, a pause of several microseconds occurs so that the transducer can receive returning echoes. The returning echo causes the piezoelectric crystal to vibrate, which then produces an electrical signal that is transmitted to the receiver and display screen. This pulse-echo process is repeated a thousand or more times per second to produce a 'real-time' display (Bentley *et al.,* 2003; Rai *et al.,* 2007).

Returning echoes produce an electrical signal that is received by the ultrasound as a weak radio frequency signal. This signal undergoes processing that can include amplification, compensation, demodulation, and rejection. Amplification is most important in ophthalmic ultrasound instruments. Three types of amplification are used; they are linear, logarithmic or S-shaped (Brandy *et al.,* 2008).

2.5.5 Instruments in ocular ultrasound

The highest frequency transducer available should be used, but a diagnostic examination can be performed utilizing a 5–10-MHz transducer (Whitcomb, 2002). High resolution (high frequency with a minimum of 7.5 MHz, but up to 50 MHz) transducers are used for ocular ultrasound. Linear transducers usually provide the best near field resolution, however smaller footprint transducers may be easier to manipulate (Spaulding, 2008). Rectal, tendon, and curvilinear transducers can all be utilized to produce diagnostic images (Whitcomb, 2002).

A-Scan: A-scans are one-dimensional displays in which returning echoes are reflected as vertical spikes from a baseline. Height of the spikes indicates the strength, or amplitude, of the echoes (Giglio and Sherman, 1979; Bentley *et al.,* 2003). There are different types of A-scans in ophthalmology. A-scans can be used for axial eye length measurements. This is known as biometry, and typically uses linear amplification, a focused transducer and a frequency between 10 and 15 MHz. A vector A-scan is used simultaneously with B-scan echograms and has similar characteristics to the B-scan, usually logarithmic amplification, a focused transducer, and a frequency of 10 MHz (Bentley *et al.*, 2003).

The standardized A-scan was developed by Ossoinig to enhance tissue differentiation. Standardized A-scans use S-shaped amplification, a non-focused 8 MHz transducer, and a parallel sound beam. Images are then compared to known patterns to make a diagnosis. Standardized A-scans have been used extensively in physician-based ophthalmology, and experienced users can make very definitive diagnoses of tumor and exudate type based on recognition of these patterns (Giglio, 1977; Bryne 1995). These studies have not been repeated to any great extent in veterinary medicine. One reason for this is that diagnostic A-scans are used to diagnose choroidal tumors, which are much more common in humans than in the typical

veterinary patient. The anterior uveal tumors more common in veterinary medicine are harder to image with A-scans (Bentley *et al.,* 2003).

B-scan: The B-scan probe emits an oscillating sound beam that 'slices' through a tissue, producing a two-dimensional acoustic section. Most B-scans used in ophthalmology use logarithmic amplification and a focused, narrow sound beam to produce a sector image. Most B-scans cover approximately 6 clock hours in each slice. Most B-scan probes have a frequency of 10 MHz. Each echo is represented by a dot, and the brightness of the dot represents the strength of the echo. B-scans are essentially a combination of multiple A-scans (Bronson and Fisher, 1976; Rai *et al.,* 2007).

Probes have a marker that indicates the direction of the slice, and corresponds to the upper portion of the echogram. To obtain a 'real time' image, the B-scan must produce 10-60 'slices,' or frames, per second through a tissue (Bentley *et al.,* 2003).

2.5.6 Probe positioning

In humans, certified ultrasound technicians use a standardized approach to ocular ultrasonography. This ensures a complete examination of the globe, and standardized examinations and labeling facilitate communication between echographers (Bentley *et al.,* 2003). Remember that each 'slice' of the B-scan only scans approximately six clock hours of the globe. In humans, this is overcome by three main probe positions: transverse, longitudinal, and axial. The transverse probe position means that the probe marker is parallel to the limbus. Longitudinal means the probe marker is perpendicular to the limbus. Images are labeled by the probe position, and what quadrant is being examined. The optic nerve is used as a reference point (Brandy *et al.,* 2008).

In veterinary medicine, the most common probe position is axial. The scan is performed with the eye in primary gaze and the probe face centered on the cornea. The image is intersected by the optic nerve as the sound beam is directed through the center of the lens, and the beam is swept along the two opposing meridians. This image is usually easiest to understand because the lens and optic nerve are in the center of the lesion, but there is decreased resolution of the posterior segment due to sound attenuation and refraction from the lens. In veterinary medicine, however, this is the easiest probe position to use in conscious animals (Giglio and Sherman, 1979).

In transverse and longitudinal planes of ocular scans, the probe is placed on the conjunctiva posterior to the cornea. These positions bypass the lens, which allows better sound penetration as there is no absorption of the sound wave, as occurs in the axial position. In humans, the patients are directed to look away from the probe, which allows excellent exposure for probe placement. Clearly, this is not an option in a conscious veterinary patient (Bentley *et al,* 2003). The transducer is placed on the upper eyelid parallel to the upper palpebral fissure. This produces a cross-sectional image of the eye with the medial canthus to the right and lateral canthus to the left of the image. All planes of the globe are evaluated by closing the eyelid with the transducer (Brandy *et al.,* 2008). It is important to use light pressure to prevent blinking. Attempts should be made to prevent ultrasound gel from contacting the cornea. Ultrasound gel is not detrimental to the intact cornea but will cause excessive blinking (Whitcomb, 2002). A complete examination of both eyes should be performed. This is important to rule out subclinical abnormalities in the unaffected eye and to compare ocular measurements.

No standardized labeling or examination system exists in veterinary ophthalmology that compares to the system in physician-based ophthalmology. The conventions used in human patients, however, can be easily adapted to veterinary patients (Bentley *et al.*, 2003). Typically,

scans are labeled vertical axial when the probe marker is at 12:00. Horizontal axial scans are always done with the marker facing towards the patient's nose. Oblique scans are labeled according to the clock hour the probe marker is facing.

2.5.7 Ocular Imaging Techniques

There are three possible approaches to examining the eye with ultrasound: direct placement of the transducer on the cornea after application of a topical anesthetic, imaging through the eyelid and through a standoff pad such as a water bath over the globe (Brandy *et al.,* 2008 and Seiler, 2011). The direct imaging method through the cornea results in the best image quality, however if there is severe swelling of the eyelid or corneal ulceration the transpalpebral method may be the better choice. Sterile coupling gel should always be used for ocular ultrasound (Spaulding, 2008). The structures of the globe are evaluated at a depth of 4–6 cm. The retrobulbar region is evaluated at a scanning depth of 6–10 cm (Whitcomb, 2002). The globe and retrobulbar area may be examined either through the eyelid (transpalpebral) or directly on the cornea (transcorneal). Ultrasound via the supraorbital fossa is an additional window for examination of the retrobulbar area only (Whitcomb, 2002).

Ocular ultrasound technique types include:

Transpalpebral – This approach is better tolerated by the dog. The image quality is reportedly inferior to the transcorneal approach but is similar. It is best not to clip the hair or apply alcohol to the upper eyelid to avoid contamination of the eye. Instead the hair is wet with a water soaked swab and ultrasound gel is applied. Ideally, sterile ultrasound gel should be used, particularly if the transcorneal approach is used, but non sterile ultrasound gel has been used without problems (Reef, 1998). It is important to flush any ultrasound gel from the eye with saline when the

examination is finished (Scotty and Cutler, 2004). The eyelid can act as a standoff pad to see the cornea, although a standoff pad on the transducer provides better evaluation of the cornea. It is not necessary for any other ocular structures (Diaz, 2004).

Transcorneal – This approach may give better images with fewer artifacts. It is not as well tolerated by the dog. A standoff pad is needed if the cornea is to be imaged, otherwise all other structures can be seen without one. Topical anaesthesia (e.g. Alcaine - proxymetacaine hydrochloride) can be applied with a 1m syringe and is necessary for transcorneal examination (Diaz, 2004). Multiple applications are needed and it is recommended to wait for 10 minutes before scanning. It is important to flush any ultrasound gel out of the eye when the examination is finished.

Supraorbital technique – This is used for further assessment of the retrobulbar region via the supraorbital fossa. Because of the shape of the fossa a small convex transducer is needed to get good contact with the skin. The hair needs to be clipped (Whitcomb, 2002).

2.5.8 Ocular Biometry

It is feasible to perform four measurements of the eye by ophthalmic ultrasound: anterior chamber depth, which includes the axial distance from the cornea to the anterior capsule of the lens (D1); lens thickness, measured from the anterior capsule of the lens to the posterior capsule of the lens (D2); vitreous chamber depth, measured from the posterior capsule of the lens to the posterior pole of the eye (D3); and the axial length of the eye, which corresponds to the measurement from the cornea to the posterior pole of the eye (D4) (Cottrill *et al.*, 1989; Gonzalez *et al.*, 2001).

2.6 Diagnostic Ocular Ultrasound

Structures routinely identified on ultrasound include the anterior chamber, ciliary bodies, and lens with anterior and posterior lens capsules, vitreous bodies, posterior wall of the globe, optic disc and optic nerve (Spaulding, 2008). The iris and posterior chambers can be difficult to distinguish from the ciliary body in normal dogs unless high frequency transducers are used (Seiler, 2011). In the posterior wall, the choroid and retina can normally not be seen separately either.

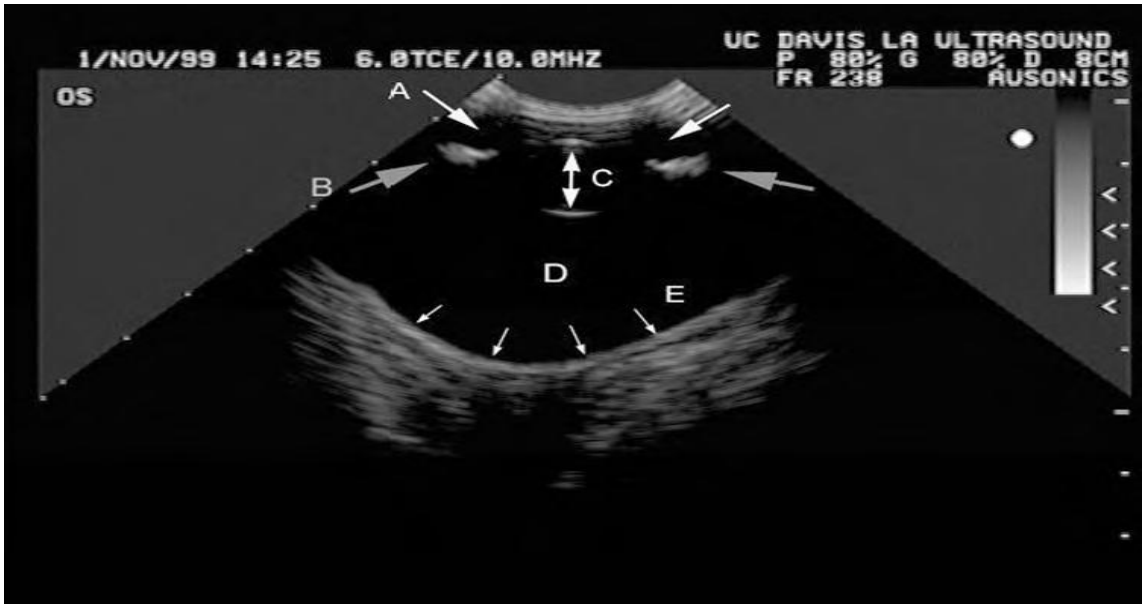

Figure 2.3: Normal sonographic appearance of the ocular globe
Source: Whitcomb, 2002
This image was obtained with a 6.0-MHz curvilinear transducer set at 10.0 MHz with a scanning depth of 8 cm. The cornea is not discernable in this image. (A) Anterior chamber. (B) Iris and ciliary body. (C) Anterior and posterior reflection of the lens capsule. (D) Vitreous. (E) Retina/choroidal layers.

The Cornea

This is best evaluated with a high resolution ultrasound transducer (Seiler, 2011). However, with a standoff pad placed between the transducer and upper eyelid a good sonograph can be obtained (Whitcomb, 2002). The cornea is seen as a thin hypoechoic layer deep and parallel to the eyelid. Normally it consists of three layers: two parallel hyperechoic lines separated by an anechoic layer representing the stroma. Alterations of the layers or thickness of the cornea may be observed with corneal disease such as inflammation, degeneration, neoplasia or trauma (Spaulding, 2008). Corneal abnormalities include corneal edema, corneal infiltrates, or stromal abscesses (Whitecomb, 2002).

Cornea edema is seen as a thickened and diffusely hypoechoic cornea. Corneal infiltrates or stromal abscesses may also cause corneal thickening with echogenic material within the cornea. Infiltrates may dissect between corneal tissue layers or may coalesce into focal accumulations within the corneal stroma. Corneal ulcerations will cause a thickened and irregular surface to the cornea (Whitcomb, 2002; Rai *et al*., 2007).

Anterior uveitis may be an indication for ultrasound if corneal edema prevents ophthalmologic examination. Anterior uveitis and/or glaucoma can result in distention of the anterior chamber (Whitcomb, 2002). In severe cases, inflammatory debris seen as ill-defined hyperechogenicities within the anterior chamber may be apparent on ultrasound. Color Doppler should be used if larger, mass-like structures are present to differentiate avascular blood clots from perfused neoplastic masses (Spaulding, 2008). The size of the anterior chamber can be increased (glaucoma, posterior lens dislocation, aphakia) or decreased.

The Iris and Ciliary body

They are seen as echogenic linear structures which extend from the peripheral globe towards the lens, and this region appear as a singular structure with standard ultrasound equipment. The corpora nigra or iridic granules are seen as an echogenic mound of tissue on the anterior surface of the dorsal iris. Occasionally, iris cysts may be seen within the corpora nigra. These are spherical structures with anechoic centers and are considered an incidental finding. Iris bombe is infrequently seen as sequelae to inflammation and/or glaucoma (Whitcomb, 2002).

The ciliary body is a common location for intraocular tumors (Seiler, 2011). Tumors of the iris and ciliary body range from focal masses to diffusely infiltrative processes. Ocular melanoma is a common tumor affecting the ciliary body, but other tumors such as lymphoma, adenoma, adenocarcinoma, medulloepithelioma or metastatic neoplasia have been described.

Ciliary cysts are easily seen with ultrasound and may be singular or appear in clusters on the vitreal side of the ciliary body. They are always located temporally near the lateral canthus. Ciliary cysts may be asymptomatic if no other ocular abnormalities are identified (Whitcomb, 2002).

The Lens

The normal lens is anechoic. Only the anterior and posterior reflections of the lens capsule can be seen in normal eye (Whitcomb, 2002). The lens should exhibit a reflection at the anterior and posterior lens capsule, but the normal cortex and nucleus should be anechoic. Sometimes a very strong echo from the lens capsule can cause multiple external reverberations (Bentley *et al.*, 2003). Abnormalities of the lens include cataracts; swelling; rupture of the lens capsule; subluxation or dislocation (Spaulding, 2008).

Cataract is characterized by abnormal hyperechoic echoes within the lens, the number and distribution of these echoes depends on the maturity of the cataract. Reduction of the lens volume seen as decreased lens thickness is seen in later stages or hypermature cataracts with cortical reabsorption (Seiler, 2011). Cortical and nuclear opacities may be differentiated (Bentley *et al.,* 2003). Cortical cataract is characterized by thickening of the anterior and posterior cortices, and visualization of the entire surface of the lens, whereas nuclear cataract refers to the nucleus becoming hyperechoic. An incipient cataract will only have a small echogenic area corresponding to the area of opacity. Lens thickness will increase with some types of cataracts, such as the osmotic cataracts seen in diabetes. Lens thickness will decrease as the lens becomes hypermature and begins to resorb (Giglio, 1977; Bryne, 1995; Bentley *et al.*, 2003). Mature acquired cataracts may vary somewhat in their sonographic appearance. Most cataracts demonstrate a thickened echogenic lens capsule with or without irregular margins (Whitcomb, 2002). The interior of the cataractous lens may be filled with echogenic material. The lens may demonstrate a misshapen and/or enlarged appearance. Congenital cataracts demonstrate a similar appearance as acquired cataracts.

Normally, the lens is positioned evenly between the ciliary bodies. Subluxation of the lens is the result of partial or complete separation of the lens from the peripheral ligamentous attachments. This can result in displacement of the lens either into the anterior chamber or into the vitreous cavity. Lens luxation may be associated with chronic cataract formation (Seiler, 2011). Posterior luxation appears as a spherical echogenic lens which is located ventrally within the vitreal chamber (Whitcomb, 2002). Luxated lens are easily identifiable in an abnormal position. Congenital defects such as persistent hyaloid arteries and associated lenticonus can be identified

with ultrasound. These lesions are important to planning cataract surgery and often cannot be seen through a cataractous lens (Bentley *et al.,* 2003).

The Vitreous

The normal vitreal chamber is filled with anechoic fluid. Echogenic swirling material within the vitreous may represent recent hemorrhage or vitreal debris secondary to inflammation (Whitcomb, 2002). Posterior vitreal detachments are often identified on cataract screening evaluations. Vitreal opacities can be differentiated from retinal detachments by turning the gain down. The more echogenic retina will continue to be visible, while most vitreal opacities will rapidly disappear. Floaters can often be seen in the vitreous from a variety of causes. Typically, vitreal degeneration appears as dots to linear strands that are freely floating in the vitreous (Bentley *et al.,* 2003). Asteroid hyalosis appears as multiple bright white dots in the vitreous. In synchysis scintallins, the cholesterol crystals sink to the ventral aspect of the vitreous. Posterior vitreal detachments can be identified. They can appear very similar to retinal detachments, but tend to be thinner, and disappear as gain is decreased (Bentley *et al.,* 2003; Rai *et al.,* 2007). The hyperechoic foci in asteroid hyalosis are caused by calcium containing lipids suspended in the vitreous cavity. The cholesterol crystals seen with synchysis scintillans on the other hand are not suspended and sink to the bottom of the liquefied vitreous body (Seiler, 2011). A detached vitreous body results in multiple linear or curvilinear hyperechoic convex echoes in the posterior vitreous cavity. Anechoic fluid can accumulate between the detached vitreous and the retina. Compared with a detached retina, vitreal membranes are usually lower in intensity (Rai *et al.,* 2007; Seiler, 2011). Inflammation, hemorrhage and infection can also lead to echoes within the vitreous. Hemorrhage may not be visible in an acute stage, but later on usually results in multiple hyperechoic echoes that are variable in appearance and may be difficult to distinguish from

asteroid hyalosis (Spaulding, 2008). Hemorrhage tends to form clumps of tissue over time as it organizes. Fibrous strands can develop secondary to clot formation, and retinal detachment may result. Inflammation can have an identical appearance compared with hemorrhage (Labruyere *et al.,* 2008). Persistent hyperplastic primary vitreous is seen as a thin, linear hyperechoic strand from the lens to the optic disc. Vitreal hemorrhage can be difficult to differentiate from other lesions such as tumors or inflammatory exudates. It varies in appearance depending on the location, amount and duration. With severe hemorrhage, the entire vitreous may be opaque, while with mild hemorrhage opacities of varying size can occur. Hemorrhage tends to settle ventrally, and if pseudomembranes occur (making hemorrhage appears to be a retinal detachment), they must be followed carefully to determine their endpoint. Pseudomembranes from hemorrhage will end in the vitreous while retinal detachments will still be attached at the optic nerve at least, if not the ora serrata (Bentley *et al.,* 2003). Hemorrhage is more likely to disappear as gain is decreased. Fresh hemorrhage is usually less dense, but older hemorrhage can be denser and therefore harder to diagnosis. Older hemorrhage may also not disappear with decreased gain. Carefully monitoring over time with consistent probe positioning and gain settings can help to distinguish hemorrhage from other lesions (Rai *et al.,* 2007; Bentley *et al.,* 2003). Other lesions that can be noted in the vitreous are foreign bodies. These are typically highly reflective and may or may not cause shadowing or multiple echoes, depending on their composition (Bentley *et al.,* 2003).

Intraocular foreign bodies are often located in the vitreous body (Labruyere *et al.,* 2008). The sonographic appearance of the foreign body depends on type, size and location of the foreign body. Metallic foreign bodies result in strong distal shadowing and reverberations, whereas wood foreign bodies rare often recognized by their shape and don’t always produce a strong shadow.

The Retina

The retina is a layer of cells lining the vitreal chamber. The normal retina cannot be differentiated sonographically from the other choroidal layers. Retinal detachment is an easily recognizable finding which can be partial or complete. Complete retinal detachment is recognized as a thin hypoechoic layer of cells of the lens (Whitcomb, 2002).

Retinal detachments are probably the most common indication for ophthalmic ultrasound (Bentley *et al.,* 2003). Retinal detachment is readily identified with ultrasound. The retina is firmly attached to the optic nerve and the ora serrata and remains attached to these points (Spaulding, 2008). The classic appearance of a retinal detachment is the 'gull' wing appearance, which occurs when the retina remains attached at the ora serrata and the optic nerve (Bentley *et al.,* 2003). However, a detached retina can have many different ultrasonographic appearances, depending on if it is partial or complete, exudative, or disinsertional. Again, when the gain is turned down, the reflective retina will remain on the image while vitreal opacities will often disappear (Bryne and Green, 2002; Bentley *et al.,* 2003). Detachment can be focal or diffuse along the entire retinal surface. Attachment to the optical disc is used to distinguish retinal detachment from vitreous membranes although the two conditions may look similar. As mentioned above, the detached retina usually is thicker and more echogenic than the vitreous membranes (Spaulding, 2008).

The Choroid

Chorioretinitis typically appears as a thickening of the choroid and/or retina, which may be hyperechoic or hypoechoic. Choroidal detachments generally have a sharper angle at the area of detachment than seen in a retinal detachment (Giglio and Sherman, 1979; Bentley *et al.,* 2003).

The Sclera

Scleral ruptures can be identified in trauma with careful examination. Often a hemorrhagic track will lead to the area of scleral rupture. Posterior scleritis has a typical ultrasonographic appearance. There is diffuse thickening of the posterior sclera, often associated with diffuse retina and choroidal thickening. Episcleral inflammation causes distention of sub-Tenon's space, producing a hypoechoic space outside the globe. When this occurs around the optic nerve, it is referred to as the "T-sign" (Bentley *et al.,* 2003).

The Orbit

Orbital disease can cause deformities of the posterior aspect of the globe, blunting of the posterior aspect of the globe, diffuse increased echogenicity of the retrobulbar space prohibiting delineation of the optic nerve, and discrete masses in the retrobulbar space (Bentley *et al.,* 2003; Rai *et al.,* 2007). Tumors tend to be hyperechoic and cause deformities of the posterior aspect of the globe and/or appear as discrete masses. Inflammatory retrobulbar processes can be diffusely hyperechoic to distinct hypoechoic masses. Diffuse, non-deforming lesions are most consistent with cellulitis. A retrobulbar abscess can mimic a mass, but if fluid is identified, it is more likely to be an abscess. These lesions can be differentiated by ultrasound guided aspirates (Bentley *et al.,* 2003).

The Retrobulbar Region

Ultrasonographic examination of the retrobulbar space is limited to the small cone-shaped area of soft tissue surrounded by the bony borders of the orbit (Attali-Soussay *et al.,* 2001). The retrobulbar space contains hyperechoic fat, the optic nerve accompanied by blood vessels, and

the orbital muscles that run tangentially to the back of the globe. Occasionally, the zygomatic gland can be seen on the lateral aspect.

The optic nerve can be recognized as a hypoechoic linear structure extending from the optic disc, as opposed to the ocular muscles which are abaxially located. The bone surface of the retrobulbar space should be seen as a smooth, hyperechoic border, irregularities or defects in this surface is suspicious for bone lysis (Mason *et al.*, 2001). Since ultrasound is very limited in investigating the presence and degree of bone lysis, other imaging methods should be pursued such as CT or MRI. Diffuse changes of the retrobulbar space with increased echogenicity or patchy areas of hypoechogenicities are seen with retrobulbar cellulitis (Seiler, 2011). Once an abscess is formed, it usually appears as a hypoechoic mass lesion that may deform the posterior wall of the globe, sometimes surrounded by hyperechoic tissue.

The retrobulbar space should be carefully evaluated for any shadowing structures that could represent foreign material. Retrobulbar tumors however have a very similar appearance compared to abscesses, and fine needle aspiration is usually needed for a final diagnosis (Attali-Soussay *et al.*, 2001).

2.7 Echodescription of common intraocular conditions

1. Vitreous floaters appear as one or more echo dots of less brightness in the mid /posterior vitreous cavity which show mobility with after movement display on B-scan. These may be associated with enlarged globe size. On A scan, these echodots have extremely low to low reflectivity (2-20%) and to appreciate them better overall gain may be increased by 5-6db (Whitcomb, 2002; Brandy *et al.*, 2008).

2. Vitreous haemorrhage may be fresh, resolving, organizing, organized with membrane formation and at times can lead to tractional retinal detachment RD (Bryne and Green, 2002). To pick up fresh vitreous haemorrhage, the overall gain can be increased by 10 db. They appear as multiple fine echo opacities dusting the vitreous body which do not extend beyond the posterior vitreous border (Jakobiec and Font, 1986). They are usually attached to the retinal surface but may get detached and are then seen as posterior vitreous detachment (PVD). Depending on the grade and location of the haemorrhage the PVD may or may not be stained. On A scan, these haemorrhagic spots (echo pulses) show low reflectivity (5-10%) (Rai *et al.,* 2007). In older haemorrhage, the echo dots are denser and show higher reflectivity (up to 60%) on A-scan. Stained PVD may also be seen. In resolving vitreous haemorrhage, in comparison with older scans, echodots on B scan show decrease in brightness and numbers. Subhyaloid haemorrhage is situated typically at the posterior pole between the anterior surface of retina and posterior vitreous face. It may be fluid in nature or may get organized (Giglio and Sherman, 1979). Sometimes an organized old pre-retinal haemorrhage may be seen in all the quadrants of the globe. Lifting of this organized vitreous haemorrhage during vitrectomy can produce iatrogenic retinal breaks and retinal detachment. An old organized vitreous haemorrhage can result in vitreous-membrane formation (seen as echogenic lines on B-scan) mimicking RD. The attachment of the echomembrane on/upto the optic nerve head and quantitative echography (difference in decibel setting 6-15db for retina and >20 db for vitreous membrane) help to differentiate RD from vitreous membranes (Jakobiec and Font, 1986, Rai *et al.,* 2007). At times these vitreous membranes, especially in cases of recurrent haemorrhage, become extremely thick and after attaching to the retina exert a tractional force on it resulting in a tractional RD (Bryne and Green, 2002). This is usually seen in proliferative retinopathy of different varieties like in diabetics, hypertensives, sickle cell disease, trauma.

Subtle findings like retinal break, scleral rupture, tumors like melanoma breaking into the Bruch's membrane, disciform degeneration, imbedded foreign body, etc can be picked up giving an insight to the etio-pathogenesis of the vitreous haemorrhage.

3. In endophthalmitis/ vitritis the inflammatory cells which are seen dot like on B-scan, are multiple, scattered diffusely or may be localised to the anterior, mid or the posterior one third of the vitreous cavity depending on the etiology (Maggs *et al.*, 2008). On A scan, these dots like opacities show low to medium reflectivity (10-60%). It is not possible to differentiate vitritis from vitreous haemorrhage in still pictures unless clinical details are available. These inflammatory cells organize very rapidly to form vitreous membranes and therefore frequent examinations should be performed (Rai *et al.*, 2007).

4. Asteroid Hyalosis is characterized clinically by presence of calcium crystals embedded in an amorphous matrix which on B-scan appears as multiple, densely packed, homogeneously distributed echodense dots of medium to high reflectivity (50-100%) which are usually localized to the core of vitreous body. One may find clear retrovitreal or pre-retinal space (Gelatt, 2000).

5. Posterior vitreous detachment (PVD): Normally vitreous is attached to the retina and a clear vitreous cavity is seen in front of the retinochoroidoscleral complex (Slatter and Basher, 2002). In PVD which may occur due to senility, trauma or vitreous haemorrhage, one sees echogenic membrane concentric to the globe, in front of the retinochoroidoscleral complex with clear subvitreal space. It may be small, interrupted, peripheral or continuous and total. If lined with red blood cells its echo density increases (Bryne, 1995). On A scan, the reflectivity of this membrane is low if the PVD is thin but it may be high if it is thick and lined with red blood cells. PVD usually does not show attachment to the optic nerve head (Rai *et al.*, 2007).

6. Retinal detachment means separation of neurosensory retina from the pigmentary retina. It may be total/subtotal, localized/peripheral or fresh/old with proliferative vitreoretinopathy (PVR) changes (Rai *et al.,* 2007). On B-scan, it appears as echogenic dense membrane, biconvex or biconcave with 100% attachment at the optic nerve head (ONH) and 90-100% reflectivity on A-scan. Attachment at ONH is not seen in localized, peripheral RD where membrane is visible only in a single quadrant. In uncomplicated cases, there is a clear space between the detached retina and the ocular coat spike indicating transudative nature of the subretinal fluid (Slatter, 1990).

7. Scleral Explants are used in rhegmatogenous RD surgeries where buckle or sponge is applied to indent the globe. On B-scan they appear as echogenic spots with the globe indentation towards the vitreous body and echolucent spot (shadowing) behind the scleral explant. The explant shows high reflectivity on A- scan. Silicone buckle is less echodense in comparison to the sponge (Chugh *et al.*, 2001).

8. Vitreous expanders like silicone oil or perfluorocarbons may be seen in operated RD cases. Emulsified silicone oil produces marked sound attenuation hindering the visualization of posterior segment (Rai *et al.,* 2007). It also results in a larger vitreous cavity which is relatively echo-free. Perfluorocarbons on the other hand show multiple, highly reflective liquid bubbles in the posterior vitreous.

9. Choroidal detachment is usually in the periphery and may be localized or total. When seen after glaucoma filtering surgery, it is seen as dome shaped elevation with clear sub choroidal space on B-scan and 90-100% double peaked tall spike on A-scan (Bryne, 1995). There is none or very little after movement on kinetic echography. In cases with impending expulsive haemorrhage or traumatic choroidal detachment, the sub choroidal space shows haemorrhage as multiple dot-like opacities on B-scan. There may be two or more domes which may meet in the

vitreous cavity to form kissing choroidals (Rai *et al.,* 2007). Choroidal detachment needs to be differentiated from RD and PVD (Whitcomb, 2002).

10. Intraocular tumors which commonly require B-scan evaluation are retinoblastoma, choroidal melanoma, hemangioma, metastasis, diktyoma and osteoma (Rai *et al.,* 2002).

Retinoblastoma is seen as a solid tumor arising from the retinal layer obliterating the vitreous cavity. It has to be differentiated from other causes of leucocoria. Calcification within the tumor mass is typical of retinoblastoma (Rai *et al.,* 2007). There may be shadowing effect behind the lesion in the orbital mass. Concomitant RD may be sometimes present. On A-scan, spikes with moderate internal reflectivity may be seen but in presence of necrosis and calcification, highly reflective, irregular spikes are observed. Sound attenuation is moderate to high (Bryne, 1995). The globe is usually normal in size except in glaucomatous stage when it becomes enlarged, whereas, in persistent hyperplastic primary vitreous, the globe size may be smaller and the vitreous cavity shows persistence of the primary vascular system seen as echo membranous track from optic nerve head to the back of the lens (Rai *et al.,* 2007). Retinopathy of prematurity is characterised by multiple vitreous membranes and RD in the periphery. The size of the globe may be smaller in these cases. In Coat's disease there is unilateral involvement and there may be presence of an exudative RD with turbid sub-retinal fluid or cholesterol crystals in the sub-retinal space.

Choroidal naevus/melanoma appears as a small dome shaped, localized, solid lesion, elevated from the ocular coats with low to medium reflective A-scan spike (40-60%). Tuberculoma may have a similar appearance on B-scan. Larger melanoma is seen typically as solid dome shaped mass, arising from the choroidal layer with strong border echoes, projecting into the vitreous cavity with solid RD and retromass shadowing effect (Whitcomb, 2002; Rai *et al.,* 2007).

Internal hollowing if present indicates tumor cell necrosis. At times vascularity, may be noticed with distinct after-movement. On A-scan, the internal echo-spikes show low to medium reflectivity. Choroidal haemangioma and osteoma are characterized by internal echo-spikes of high reflectivity. In haemangioma, the A-scan spikes show a honeycomb pattern because of multiple tissue interfaces. Lesions in choroidal metastasis have variable shape, reflectivity and sound attenuation. They are usually present at the macula and may be associated with RD. Diktyoma is a rare tumor in which an iris/ciliary body cyst or a free floating cyst in the aqueous/ vitreous humor may be seen (Jakobiec and Font, 1986).

11. Oculo-orbital trauma may have varied manifestation such as hyphaema with iridodialysis optic nerve avulsion which may be partial or total (Chugh *et al.,* 2001). On B-scan, the optic nerve head may be absent or there may be haemorrhage in the vitreous cavity with the globe being soft.

12. Miscellaneous conditions:

Fundal coloboma is a congenital abnormality seen in the inferonasal quadrant as defect in the retinochoroidal layer of the globe on B-scan. If the coloboma involves the ONH region, there is absence of ONH (Rai *et al.,* 2007).

Posterior staphyloma is a common finding, it appears as a sudden bowing backward of the globe with thinning of the retinochoroidal layer. It is usually seen at the posterior pole and the axial length of the globe is increased, indicating axial myopia. There may be presence of vitreous debri (Giglio and Sharman, 1979; Bryne and Green, 2002).

Post operative endophthalmitis can be differentiated from toxic anterior segment syndrome (TASS). In TASS, the severe inflammation is visible only in the anterior segment whereas in

endophthalmitis there is severe vitritis and exudation in the vitreous cavity. Also, B scan is useful in evaluating the response to intravitreal injection in endophthalmitis (Rai *et al.,* 2007).

Cysticercosis can occur in any ocular tissue (Maggs *et al.,* 2008). It is more common in vitreous cavity, subretinal space and subconjunctival space but other sites like extraocular muscles and optic nerve may also be involved. B-scan reveals a well defined cystic lesion with clear contents and a hyperechoic area suggestive of scolex. Serial echography helps in follow-up of the patient and resolution is indicated by disappearance of the scolex (Rai *et al.,* 2007).

2.8 Artifacts in Ocular Ultrasonography

1. Multiple signals:

When sound waves reverberate between interfaces, multiple artifactual echo signals are produced (Bentley *et al.,* 2003). These signals must be distinguished between true echoes, external and internal multiple signals occur.

External multiple signals results from reverberations between the probe tip and an acoustic interface. Examples of objects that produce external multiple signals are the surface of the crystalline lens, an artificial intraocular lens, an air bubble, the sclera or bone (such as the orbital bone). The multiple reverberations are the result of the reflection of a sound wave of significant magnitude back to the probe. When this true echo is strong enough, a portion of it will be reflected off the probe surface and will go back to the original interface. The second wave will then produce a reverberation echo that appears distal to the true echo in the echogram. In the image, the first reverberation echo will appear twice the distance between the probe tip and the originating acoustic interface (Bentley *et al.,* 2003).

Additional reverberation echoes may be produced by additional round trips of the sound wave. The true echo and the reverberation echoes are equidistant, and the reverberation echoes usually decrease in strength with increasing distance from the true echo (Bentley *et al.,* 2003; Brandy *et al.,* 2008). Furthermore, multiple signals move to a far greater degree than true echoes do when the probe is pressed against the tissues.

Internal multiple signals occur by reverberations within certain types of foreign bodies. They are associated with the sound beam striking a spherical foreign body, such as a gunshot pellet, or a small bubble of air or gas. Flat foreign bodies with closely spaced, parallel surface, such as slivers of glass, can also cause internal multiple signals (Bentley *et al.,* 2003).

Internal multiple signals appear as a chain of closely spaced signals emanating from the foreign body echo, or a 'comet tail' artifact. It is generated by some of the energy from the sound wave being trapped in the object. The trapped energy bounces back and forth, and portions will escape and return to the probe. This results in a chain of echoes of decreasing amplitude extending from the foreign body. A comet tail artifact can be useful in identifying the type of foreign body (Bentley *et al.,* 2003).

2. Shadowing:

Strong sound attenuation causes shadowing. An absence of echoes posterior to an extremely dense interface such as bone, calcium, or a large foreign body is due to complete shadowing. Partial shadowing leads to reduction of the echoes posterior to a lesion (e.g, in the case of large tumors). Shadowing may make evaluation of structures behind the source of shadowing difficult, but can also aid in diagnosis (Rai *et al.,* 2007). Shadowing can also occur due to refraction at the

edges of a smooth curved interface rather than solely by sound attenuation. This occurs at the edge of the globe or from a cystic lesion (Bentley *et al.,* 2003).

3. Enhancement:

Echoes are increased in amplitude posterior to a very weakly attenuating structure or lesion. When examined through the very low reflective vitreous cavity, the soft tissue and bone can be well demonstrated due to enhancement (Bentley *et al., 2003*).

4. Perpendicular sound beam incidence:

When the sound beam is directed perpendicularly in B-scan echograms, it can strike a very smooth highly reflective interface such as the surface of the retina, producing a bright, focal signal in the center of the echogram, particularly when a medium or low gain setting is used (Brandy *et al.,* 2008). To differentiate this signal from a foreign body or a localized area of calcification, the probe should be re-oriented to display the area in question at the periphery rather than the center. Re-positioning engages the area obliquely rather than perpendicularly, and should cause the bright area to disappear if it is indeed an artifact (Bentley *et al.,* 2003).

5. Baum's bumps:

Baum's bumps appear as elevation of the peripheral fundus, but are B-scan artifacts. These artifacts are thought to be created by refraction of the sound beam as it sweeps through the peripheral aspect of the lens in an axial probe position. Repositioning the probe peripheral to the limbus to avoid the lens should eliminate these artifacts (Bentley *et al.,* 2003).

2.9 Uses of Diagnostic Ocular Ultrasound

Sonography has revealed to be an important adjuvant in detection of ocular diseases such as cataracts, lesions of the anterior chamber, hemovitreous, neoplastic lesions, macular degenerations, congenital diseases and inflammatory pathologies (Ferrer, *et al.*, 2013).

Two modes of ocular ultrasound are considered feasible: the linear or A-scan mode and the B-scan mode. The A-scan echogram generates peaks or spikes of different heights from the isoeletric baseline which are formed by different densities of the ocular tissues. The B-scan mode, however, allows a two-dimensional real-time image of the eye and orbit (Gonzalez *et al.*, 2001). Van der Woerdt *et al.* (1993) found changes in the refractive media, notably vitreous degeneration and retinal detachment in eyes examined by ultrasonography.

Clinical use of A-scans:

A-scans in veterinary medicine are typically used for biometry, or measurement of ocular structures. Exams can be performed in awake, sedated or anesthetized animals (Bentley *et al.*, 2003). The probe can be placed directly on the cornea, or used with a scleral shell and waterbath (immersion technique). The probe should always be placed axially, and a good scan is one in which the height of the spikes from baseline are equal. Each spike should start at a perpendicular, not sloping angle from baseline. In dogs, particularly older dogs, good A-scans can be difficult to obtain because the posterior lens capsule is very thin and seems to not provide a very good interface for acoustic reflection (Bryne 1995; Bentley *et al.*, 2003).

Biometry is sometimes used for determining changes in ocular distances during disease, such as increased axial length in buphthalmic globes in glaucoma. Biometry can also be used to attempt to elucidate underlying pathophysiologies of diseases, such as documenting shallow anterior

chambers due to anterior shifting of the lens-iris diaphragm in cats with aqueous humor misdirection syndrome in cats (Czederpiltz *et al.,* 2005). Ekesten and torrang in 1995 found that lens thickness increased with age in Samoyeds, leading to a shallow anterior chamber. This age related changes may precipitate pupillary block, leading to primary angle closure (Bentley *et al.,* 2003).

The main use of A-scans, however, is to determine optical characteristics of the globe to calculate IOL strengths and the source of refractive errors (Giglio, 1977; Bentley *et al.*, 2003).

Clinical use of B-scans:

B-scans are typically used for evaluation of intraocular structures that cannot be seen through opaque media, such as corneal opacities, hemorrhage or hypopyon in the anterior chamber, cataracts, or vitreal opacities (Bentley *et al.,* 2003; Rai *et al.,* 2007). B-scans are typically used by applying the probe directly to the globe after application of topical anesthetic. A coupling medium, such as methylcellulose or a thick artificial tear, such as Genteal gel, is applied to the probe face prior to application. Examination through closed lids can be more difficult due to Bell's phenomenon (rotation of the globe with the eyes closed).

CHAPTER THREE

3.0 Material and Methods

3.1 Material/Equipments

A Medison S600 ultrasound machine equiped with a 7.5MHz curvilinear probe along with a Sony videographic thermal printer was used. Other equipment used included a Riester-ri-scope ophthalmoscope (Otoscope-Ophthalmoscope, Type-C), Tonometer (icare tonometer ONE®, TA02 model), BlackBerry *Z10* with 10.0 mega pixel digital camera, and Tiger electricity generator. See appendix 6 (Plate I and II) for pictures on some of the materials and equipments used.

Materials used included a weighing balance, ultrasound table, extension box, clinical lab coat, disinfectants and mouth gag. Consumables used in the study included, thermal printing paper, aquasonic gel, tissue paper, 10 ml syringes (with 21guage needles), cotton wool, disposable gloves and mouth muzzle for dogs. Other consumables included dettol antiseptic fluid, soap and petrol for fueling the generator.

3.1.1 Source of Study Animals

A total of eighty dogs, 46 males and 34 females of different ages with clinically healthy eyes were used for the study. The dogs were all indigenous local breed obtained from residents leaving within Zaria, particularly Hayin Dogo, Samaru and Sabon Gari areas of the study area (see appendix7, plate III). The clients' (dog owners) consent was sorted for and approval obtained before such dogs were used for the purpose of the study (see appendix 5). Dogs presented to the Small Animal Unit of Ahmadu Bello Uniersity Veterinary Teaching Hospital (SAU/ABUVTH) with grossly normal eyes during the study period were included in the study

and the client consent form were obtained and appropriately filled before the dogs were used for the study.

3.1.2 Diagnostic preparations

In the field, the procedure of pre-scanning clinical physical examinations and tonometry were carried out in the open shade. However, the pre-scanning ophthalmoscopy was conducted in the lobby or any relatively dark section of the clients' home. The scanning procedure was carried out in the open shade as was tonometry. In the SAU/ABUVTH, the diagnostic imaging laboratory of ABUVTH was used for the scanning procedures during the study whereas the other clinical ophthalmologic examinations such as physical and clinical examinations, tonometry and ophthalmoscopy were carried out in the SAU/ABUVTH floor.

3.2 Methodology

3.2.1 Study Area

This study was carried out in Zaria located in Kaduna State, within latitude 11□7 to 11□12' N and longitude 07□41' E. Zaria is a medium sized city with an estimated population of 408,198 (Anon[7], 2006). It is divided administratively into Zaria and Sabon Gari LGAs (Anon5, 1996). It has an estimated land area of about 300 square kilometers and it is approximated that about 40-75% of its working population derive its means of livelihood from agriculture (Anon[2], 2000).

3.2.2 Study Animal and Design

Eighty dogs, 46 males and 34 females of different ages were used for this study. All dogs used were divided into three (3) groups depending on their age (puppy/young-adult dogs, adult dogs and older/senior-years dogs).

3.2.3 Study Animal Screening and Distribution

Total of eighty Indigenous Nigerian dogs of various ages and weight, male and female, clinically and ophthalmologically healthy were selected for this study. The dogs were grouped into three groups based on their age and weight/size as: puppy or young-adult dogs (1-12 months of age), adult dogs (12-48 months of age) and older or senior-years dogs (48 months and above).

Group 1 (G1) was composed of thirty five (35) Indigenous dogs, ten (10) females and twenty five (25) males, with average weight of 6.583 kg and size categorized as either medium or small, age bracket was within 3-weeks to 12 – months - old. Group 2 (G2) was composed of twenty six (26) Indigenous dogs, fourteen (14) females and twelve (12) males, with average weight of 17.808 kg and size categorized as medium or small, age bracket was within 13 and 48 – months - old. Group 3 (G3) was composed of nineteen (19) Indigenous dogs, ten (10) females and nine (9) males, with average weight of 16.842 kg and size categorized as medium or small, aged 48-months or older.

3.2.4 Pre-ultrasound scanning consideration

All dogs that were selected for the study underwent a pre-study ophthalmic general physical and clinical examination. This was to obtain the biodata of each dog (which was documented appropriately) and to ascertain that each of the dogs selected for the study had satisfied all the necessary clinical criteria for a healthy eye (or sight). Ophthalmoscopy and Tonometry were the two advanced ophthalmic examinations that were undertaken to further acclaim the status of each of the dogs' eyes.

The dogs were adequately restrained using physical means (use of mouth muzzle in intractable ones) and psychologically subdued (by owners) all through the ophthalmic procedures of

tonometry, ophthalmoscopy and ocular ultrasonogrphy. Regular ophthalmic examination included direct ophthalmoscopy and tonometry. This was followed by ultrasonographic examination.

Ophthalmoscopy was carried out systematically, using the Reister-ri-scope ophthalmoscope, to view the ocular fundus, mainly the retina, some parts of the sclera and choroid as described by Maggs *et al.*, 2008. Restraint applied was with as minimal stress as possible; we ensured minimal to no restraint around the patient's neck and no pressure around the eye (Gellat, 2000).



Plate I: Conduction of Pre-ultrasound ophthalmoscopy during the study showing minimal but adequate restraint

Keys: A: the Examiner; B: Ophthalmoscope type C; C: the assistant's Hand; D: the Dog

Tonometry was conducted using the iCare tonometer which was held horizontally and therefore allows measurements to be performed with the patient's head held in a normal, relaxed standing position (Leiva *et al.,* 2006; Paul *et al.,* 2006). The dog was lightly restrained so as to not artificially raise IOP, avoiding in particular, direct pressure on the jugular veins and on the globe itself via the eyelids and keeping the dog's position consistent during the IOP measurement (Broadwater *et al.,* 2008).



Plate II: Tonometry procedure using iCare tonometer, with dog on a normal standing position and minimal animal restraint

Key: A: Examiner; B: Icare Tonometer; C: Dog under ophthalmic examiner; D: Assistant's hand

3.2.5 Ultrasound procedure/Technique

Ultrasonographic examination was performed using a B-mode ocular ultrasound unit (Medison S600 ultrasound machine) equipped with a 6.5 MHz curvilinear transducer. The structures of the globe were evaluated to a depth of 4–6 cm (Whitcomb, 2002). Ocular ultrasononograms were evaluated in respect to location of the intraocular structures of interest (i.e., anterior/posterior segment) and echo texture (isoechoic or hypo/hyper-echoic).

For ophthalmic ultrasound, the dogs were positioned on sternal or lateral recumbency and restrained manually, and the eyelids were held open by an assistant. The dog's head was firmly but lightly held, tilted and the eyelids were spaced out. Ultrasound coupling gel was applied to the cornea. Adequate contact between the probe of the ultrasound and the ocular surface was obtained with sterile ultrasound gel (as described by Whitcomb, 2002).

Using the direct corneal contact technique, the transducer was placed directly on the cornea after spreading the coupling gel. Light pressure was applied on the eye during the scan as excess pressure encouraged blinking. Both eyes were then examined. Light pressure was applied to maintain good contact between the transducer and the cornea. Each eye was examined initially in longitudinal view (horizontal section) with the ultrasound beam running from the medial to the lateral canthi, and then the head of the transducer was rotated 90° to achieve the transverse view (visualize the vertical section of the eye), i.e parallel to the palpebral fissure and perpendicular to it. By convention the transducer position marker was placed towards the nose when scanning parallel to the palpebral fissure, and superior (dorsal) when scanning perpendicular to the palpebral fissure. The transducer was fanned from one side to the other to completely examine the globe (Whitecomb, 2002 and Bentley, 2003).

A total of eighty dogs (160 eyes) were scanned. The structure of interest that were imaged and measured included the cornea (cornea thickness), anterior chamber (depth and area), anterior and posterior reflections of the lens capsule (lens thickness and area), and vitreous chamber (length and area). The globe was measured in an anterior to posterior direction at the point of maximal ocular diameter, so also was the area of the globe. The length dimensions were recorded in millimeter while the area dimensions were in square millimeter.

After ultrasound examination, excess coupling gel was carefully wiped from the eyes using tissue paper. All images were digitally recorded and the views analyzed (Toni *et al.,* 2013). Measurements of the corneal thickness was grouped and compared by age of the dogs, weight/size, gender and intraocular pressure (IOP) readings.



Plate III: Field set-up for Pre-ultrasound Tonometry and the conduction of ultrasound scanning

Measurements of axial globe length D5 in millimeter (mm) and globe area A4 in square millimeter (mm^2) were determined in the horizontal (longitudinal) meridian using the in-built measurement facility of the scanner as was done for the corneal thickness D1, anterior chamber depth D2, lens thickness D3, vitreous depth D4 in millimeter; and anterior chamber area A1, lens area A2, and vitreous area A3 in square millimeter (mm^2) (see figure 3.1 below). Data was obtained as the mean of distances from three ultrasonograms for each measurement. Ultrasonograms were rejected when distances measured are more than 5% different from the others from the same eye, so as to minimize technical errors from machine and sonographer (Toni *et al.*, 2013).

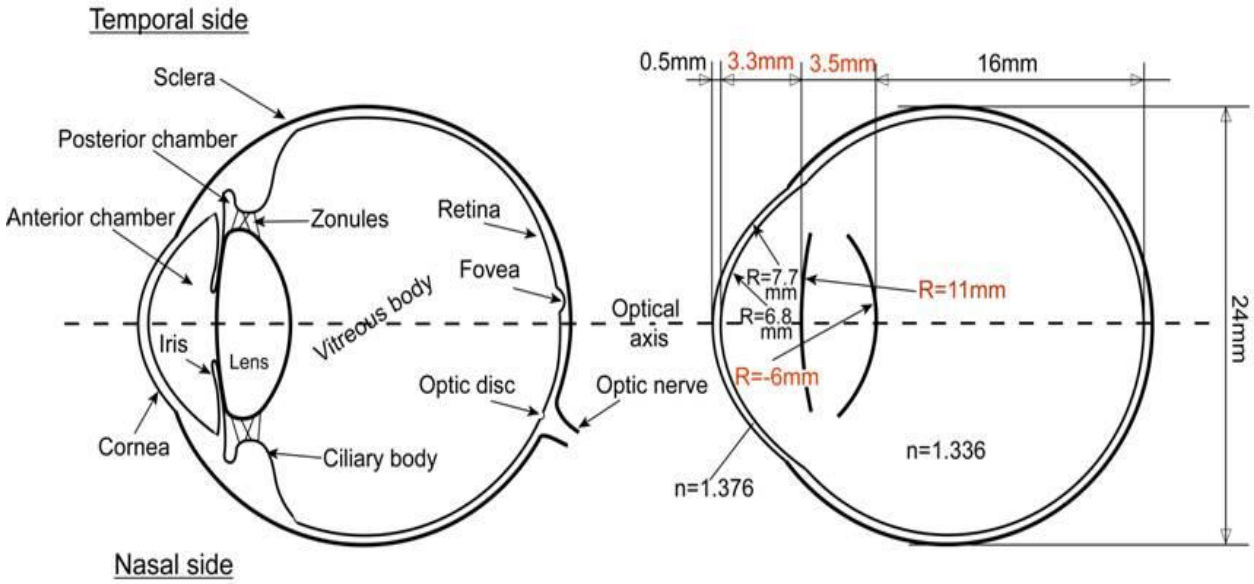

Figure 3.1: Schematic illustration of Intraocular biometric measurements of ocular parameters

Source: google.com/dogeyevet/ultrasound/measurement images/ocular_anatomy_9eg7.gif

3.2.6 Data recording and Statistical Analysis

Table 3.1: Measurement of the intraocular parameters in dogs of different age (mm) (mean±SD)

Group No.	Corneal Thickness		Anterior Chamber depth		Lens Thickness		Vitreous Chamber depth		Sagital Axis Length	
	Left	Right	Left	Right	Left	Right	Left	Right	Left	Right

A Student t-test was used for statistical analysis with a significance level of 5% (P □ 0.05), for comparison of mean values obtained for each variable between right and left eye in the indigenous dogs of the same group. For detection of differences between mean values obtained for each variable in the same groups, the Tukey's test was used with a significance level of 5% (P □ 0.05). It was also used to investigate the influence of gender on ocular parameters of the studied dogs.

The data obtained for all variables (corneal thickness, anterior chamber depth, lens thickness, vitreous chamber depth, and axial globe length of the eye; also anterior chamber area, lens area, vitreous chamber area and ocular globe area) were subjected to analysis of variance (ANOVA).

Pearson's test was applied to verify correlation between the weight of dogs and the variables ($p < 0.05$). Partial correlation was used (at $P < 0.05$), to investigate the relationship between IOP and ocular parameters in the indigenous dogs.

All animals were handled according to the *Laboratory Animal Control Guidelines*, and Ethics on Animal Use for School and research purposes (Hassan *et al*., 2005), which basically conform to the *Guide for the Care and Use of Laboratory Animals* of the National Institutes of Health in the USA (Anon[6], 1996).

CHAPTER FOUR

4.0 Results

4.1 Pre - ultrasound Findings

The mean weight obtained for the Indigenous dogs used in this study were 6.58 kg, 17.80 kg and 16.84 kg for puppy (G1), adult (G2) and older dogs (G3) respectively.

Pre-ultrasound ophthalmoscopic result of the fundus of the study dogs' eyes (right compared with left) revealed uniformity in size, shape, color and pigmentation of the fundic components – mainly the retina which was sighted through the red reflex, anterior segment disc, optic vessels, and lastly macula and fovea. This indicates that dogs' eyes were opthalmoscopically normal.

Tonometry also revealed that the IOP values were within the normal range (12-21mmHg) in all the study dogs examined.

4.2 Ultrasound Findings

4.2.1 Identification of Ocular structures on the Ultrasonogram

The conductive ultrasonic gel used as a standoff pad was effective and allowed adequate scanning of the anterior segment of the eye, as well as identification of its structures in all eyes scanned (see plate VII below).

The cornea was characterized by two parallel hyperechoic lines (anterior and posterior corneal surface). The anterior chamber, filled with aqueous humor, was identified as an anechoic area just posterior to the cornea. It was possible to identify the lens by identifying both anterior and posterior capsules as parallel hyperechoic lines. The nucleus of the lens was identified as an anechoic area. The vitreous chamber, filled with vitreous humor, was identified as anechoic area.

The posterior pole of the eye, which includes the retina, the choroid and the sclera, was identified as a hyperechogenic and convex structure (Plate VII).

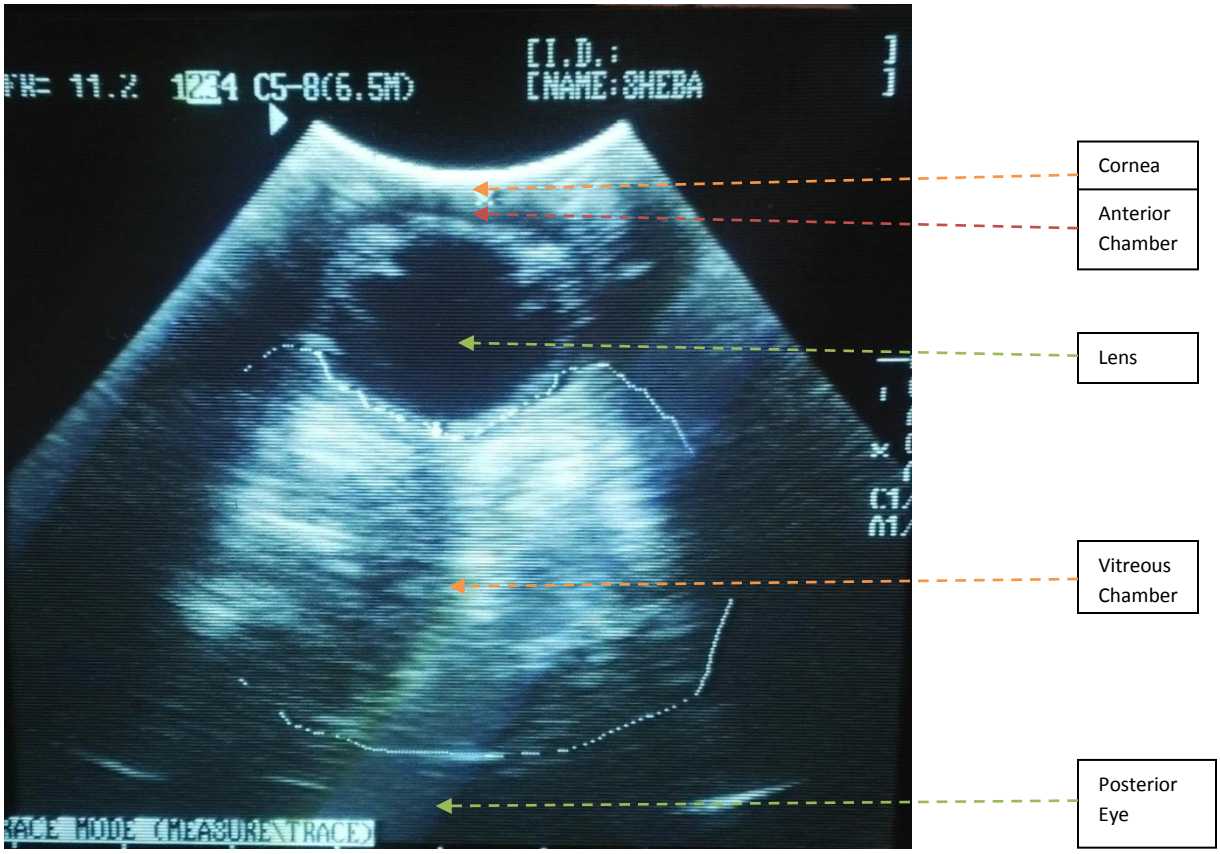

Plate IV: Transcorneal B-mode ultrasonography from a normal Indigenous nigerian dog's eye.

4.2.2 Ocular biometry results

Plates V and VI illustrate ocular biometry for ocular parameters of length (mm) and area (mm^2) respectively that were obtained during the study.

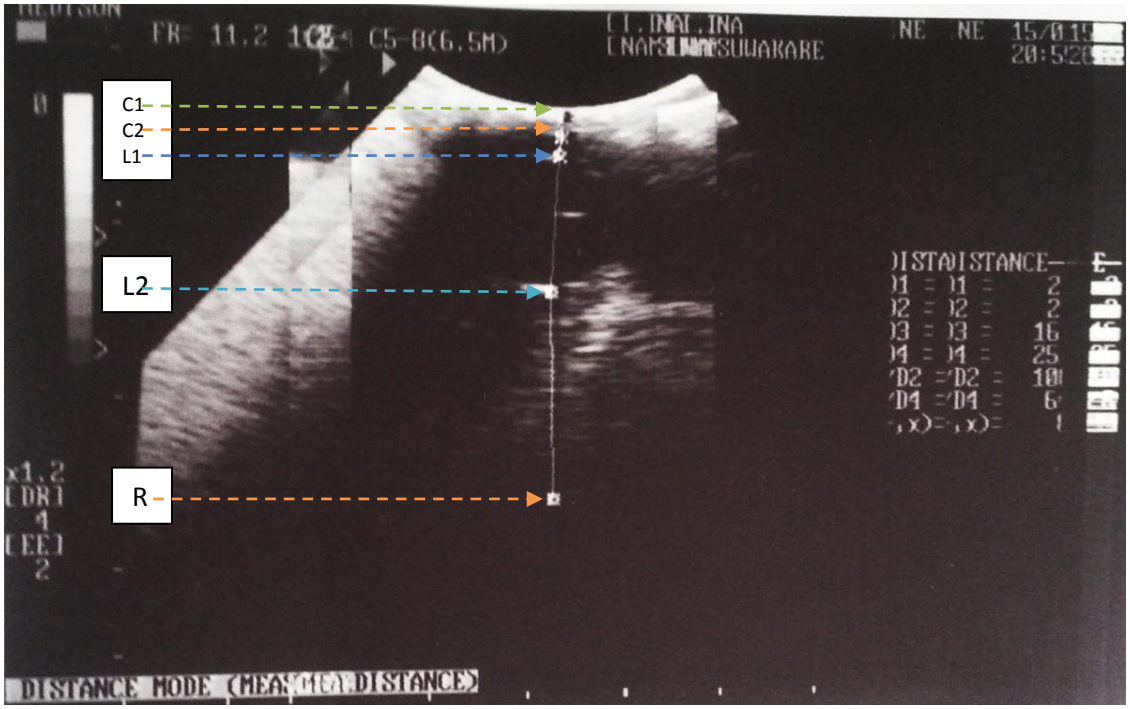

Plate V: Sonogram of ocular biometry of a clinically normal Indigenous Nigerian dog's eye
Key C: cornea; L1: anterior capsule, L2: posterior capsule, and R: retina.
Note the axial globe length (D5: 45mm, distance between C1 and R), corneal thickness (D1:2mm, distance between C1 and C2), the anterior chamber depth (D2: 2mm, distance between C2 and L1), lens thickness (D3: 16mm, distance between L1 and L2), and posterior chamber depth (D4: 25mm, distance between L2 and R).

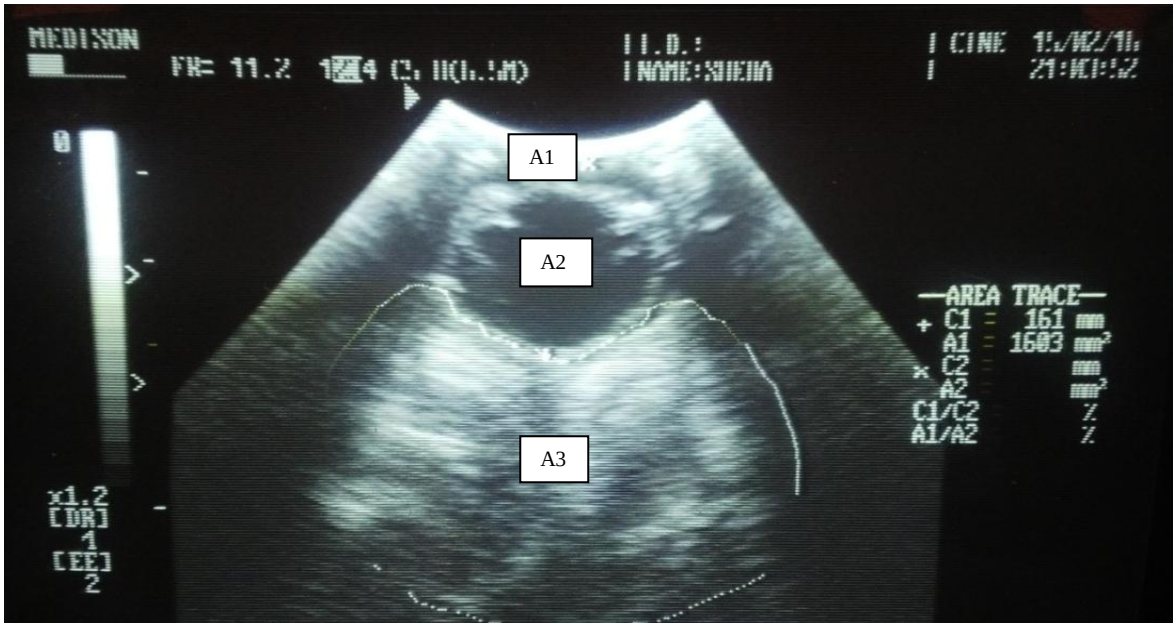

Plate VI: Sonogram of an Indigenous Nigerian dog's eye depicting area measurement of the vitreous chamber (A3:1603mm^2)

Key A1: Anterior chamber area, A2: Lens area, A3: Vitreous chamber area (1603mm^2)

4.2.3 Variability of Intra-ocular parameters according to age group in the study dogs

From the results of the ocular parameters obtained, it can be deduced that the cornea thickness (D1), lens thickness and area (D3 and A2) and ocular globe length and area (D5 and A4) all increased with age from groups 1 to 3 (see figures 4.1, 4.3, 4.7, 4.5 and 4.9 respectively), in both sexes. However, the anterior chamber depth and area (D2 and A1) and vitreous length and area (D4 and A3) increased initially with age from puppy to adults and then decreased slightly in older dogs (see figures 4.2, 4.6, 4.4, 4.8).

4.2.3.1 *Corneal thickness*

The value of the corneal thickness (D1) obtained for the puppy group (G1) was 1.2 ± 0.2 mm; adult group (G2) was 1.4 ± 0.2 mm and for the older dogs group (G3) it was 1.8 ± 0.2 mm.

4.2.3.2 *Anterior chamber depth*

The value of the vitreous chamber depth (D2) obtained for the puppy group (G1) was 2.3 ± 0.2 mm; adult dog group (G2) was 2.5 ± 0.3 mm and for the older dogs group (G3) it was 2.5 ± 0.4 mm.

4.2.3.3 *Lens thickness*

The value of the lens thickness (D3) obtained for the puppy group (G1) was 12.6 ± 0.6 mm; the adult dog group (G2) was 13.6 ± 0.8 mm and for the older dogs group (G3) it was 15.1 ± 0.9 mm.

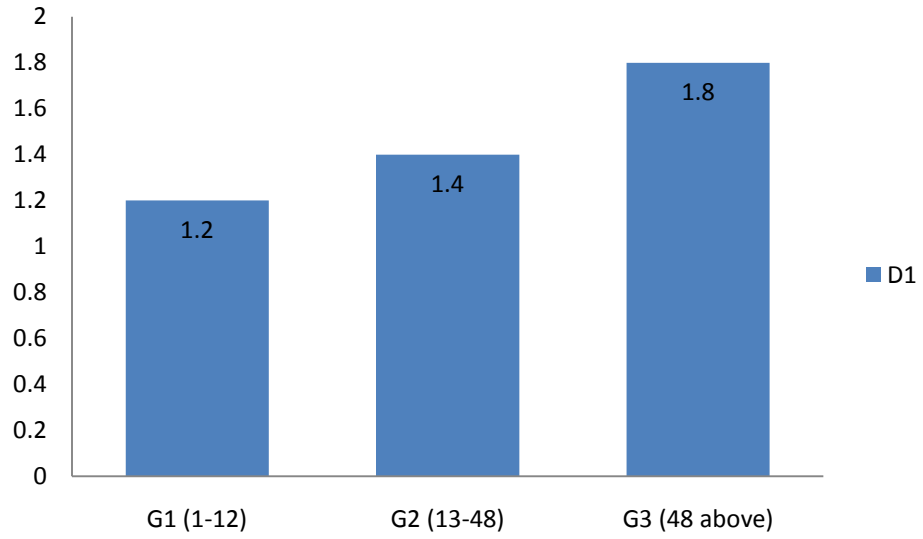

Figure 4.1: Variability of corneal thickness values in the puppy, adult and older dogs indicating distinct increment in thickness from puppy to adult and finally to older senior dogs

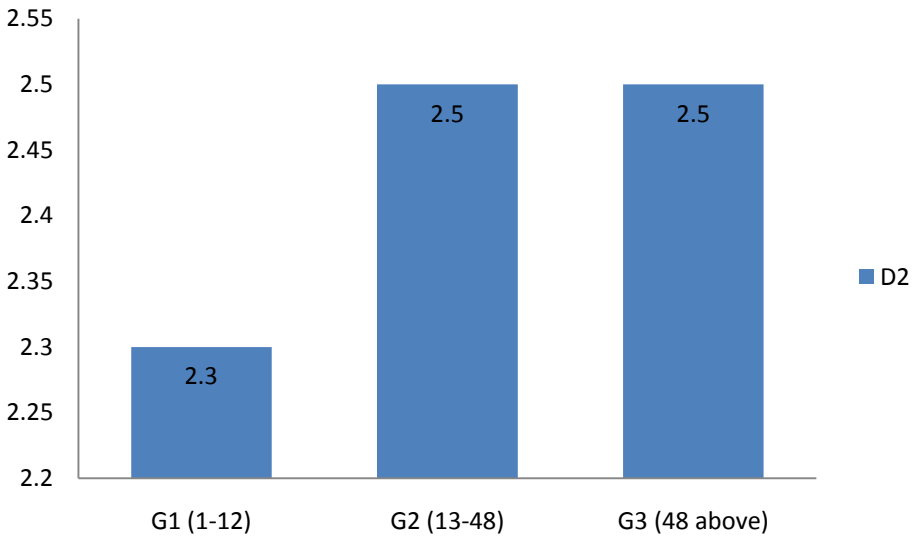

Figure 4.2: Variability of anterior chamber depth values in the puppy, adult and older dogs depicting distinct increment in depth from puppy to adult and maintained at older senior dogs

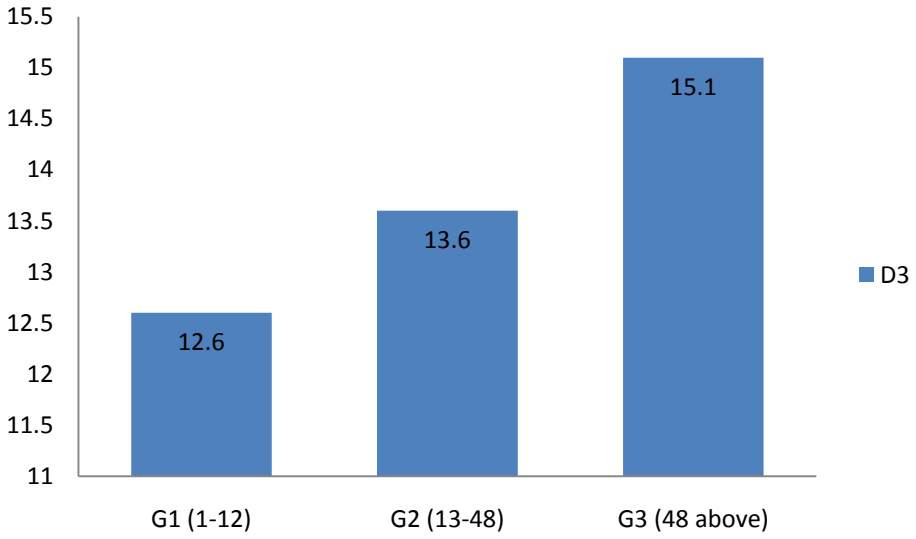

Figure 4.3: Variability of lens thickness values in the puppy, adult and older dogs indicating distinct increment in thickness from puppy to adult and finally to older senior dogs

4.2.3.4 *Vitreous chamber depth*

The value of the vitreous chamber depth (D4) obtained for the puppy group (G1) was 23.0 ± 1.0 mm; the adult group (G2) was 25.0 ± 1.5 mm and for the older dogs group (G3) it was 23.9 ± 1.4 mm.

4.2.3.5 *Axial globe length*

The value of the axial globe length (D5) obtained for the puppy group (G1) was 39.1 ± 1.4 mm; the adult dog group (G2) was 42.5 ± 1.5 mm and the older dogs group (G3) was 43.2 ± 2.1 mm.

4.2.3.6 *Anterior chamber area*

The value of the anterior chamber area (A1) obtained for the puppy group (G1) was 30.8 ±3.0 mm^2; the adult dog group (G2) was 34.5 ± 3.6 mm^2 and for the older dogs group (G3) it was 32.0 ± 4.6 mm^2.

4.2.3.7 *Lens area*

The value of the lens area (A1) obtained for the puppy group (G1) was 213.7 ± 21.1 mm^2; the adult dog group (G2) was 250.3 ± 23.6 mm^2 and for the older dogs group (G3) it was 264.8 ± 21.0 mm^2.

4.2.3.8 *Vitreous chamber area*

The value of the vitreous chamber area (A3) obtained for the puppy group (G1) was 931.0 ± 78.2 mm^2; the adult dog group (G2) was 1183.9 ± 323.0 mm^2 and the older dogs group (G3) was 1119.6 ± 57.8 mm^2.

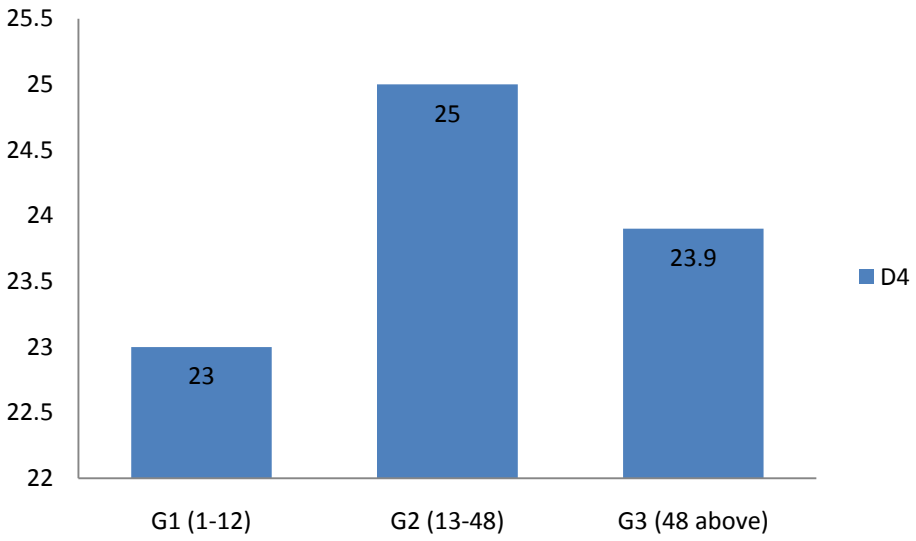

Figure 4.4: Variability of vitreous chamber depth values in the puppy, adult and older dogs depicting distinct increment in depth from puppy to adult and slightly decreasing at older senior dogs

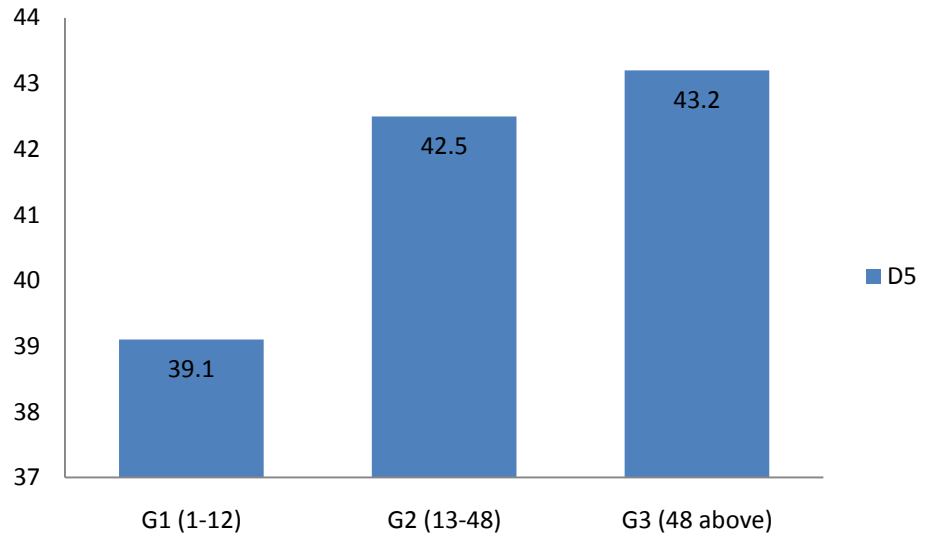

Figure 4.5: Variability of axial globe length values in the puppy, adult and older dogs indicating distinct increment in length from puppy to adult and finally to older senior dogs

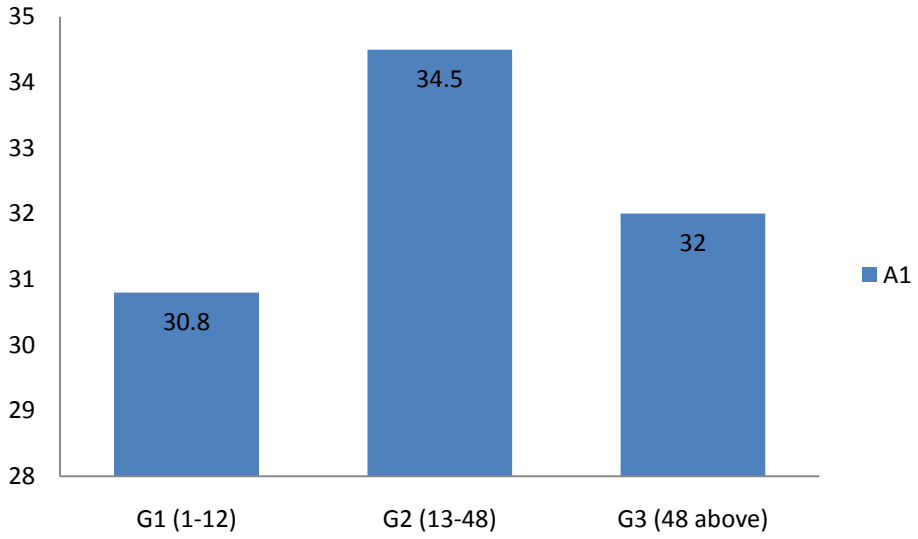

Figure 4.6: variability of anterior chamber area values in the puppy, adult and older dogs indicating distinct increment in thickness from puppy to adult and decreasing at older senior dogs

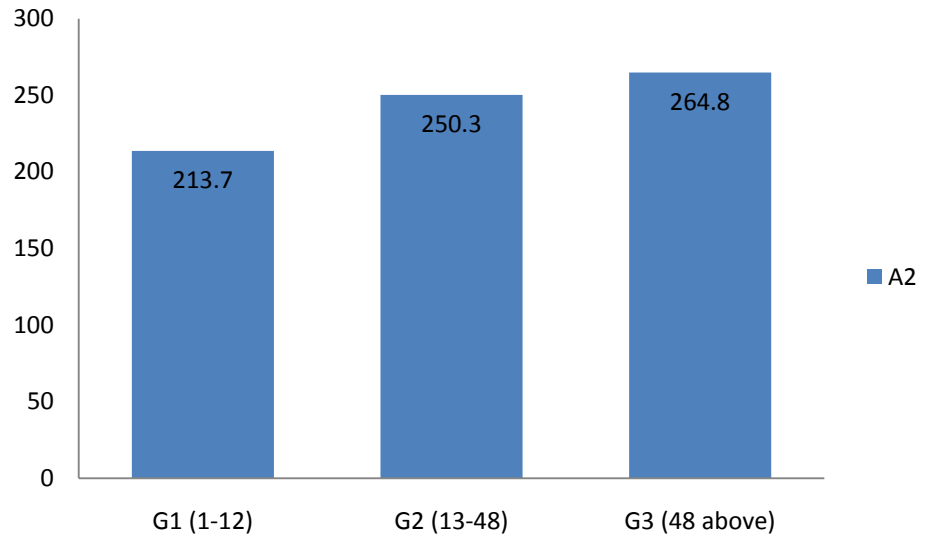

Figure 4.7: Variability of lens area values in the puppy, adult and older dogs indicating distinct increment in area from puppy to adult and finally to older senior dogs

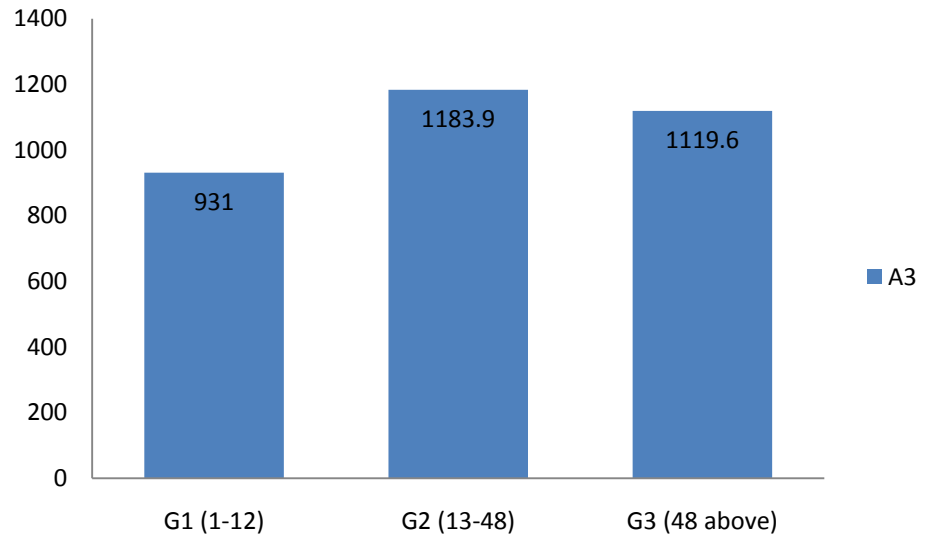

Figure 4.8: Variability of vitreous chamber area values in the puppy, adult and older dogs indicating distinct increment in area from puppy to adult and slightly decreasing at older senior dogs

4.2.3.9 *Globe area*

The value of the ocular globe area (A4) obtained for the puppy group (G1) was 1336.9 ± 82.2 mm^2; the adult dog group (G2) was 1455.6 ± 57.7 mm^2 and for the older dogs (G3) was 1477.9 ± 84.7 mm^2.

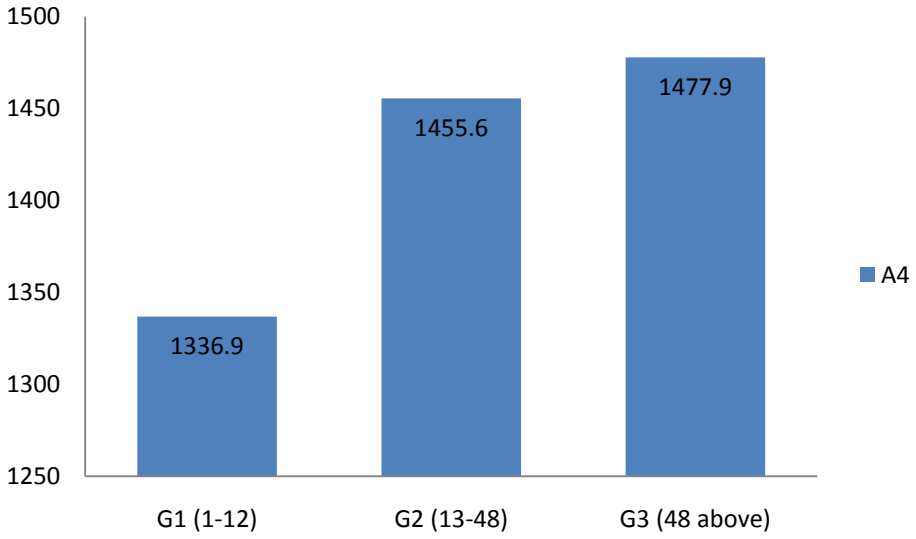

Figure 4.9: Variability of ocular globe area values in the puppy, adult and older dogs depicting distinct increment in thickness from puppy to adult and finally to older senior dogs

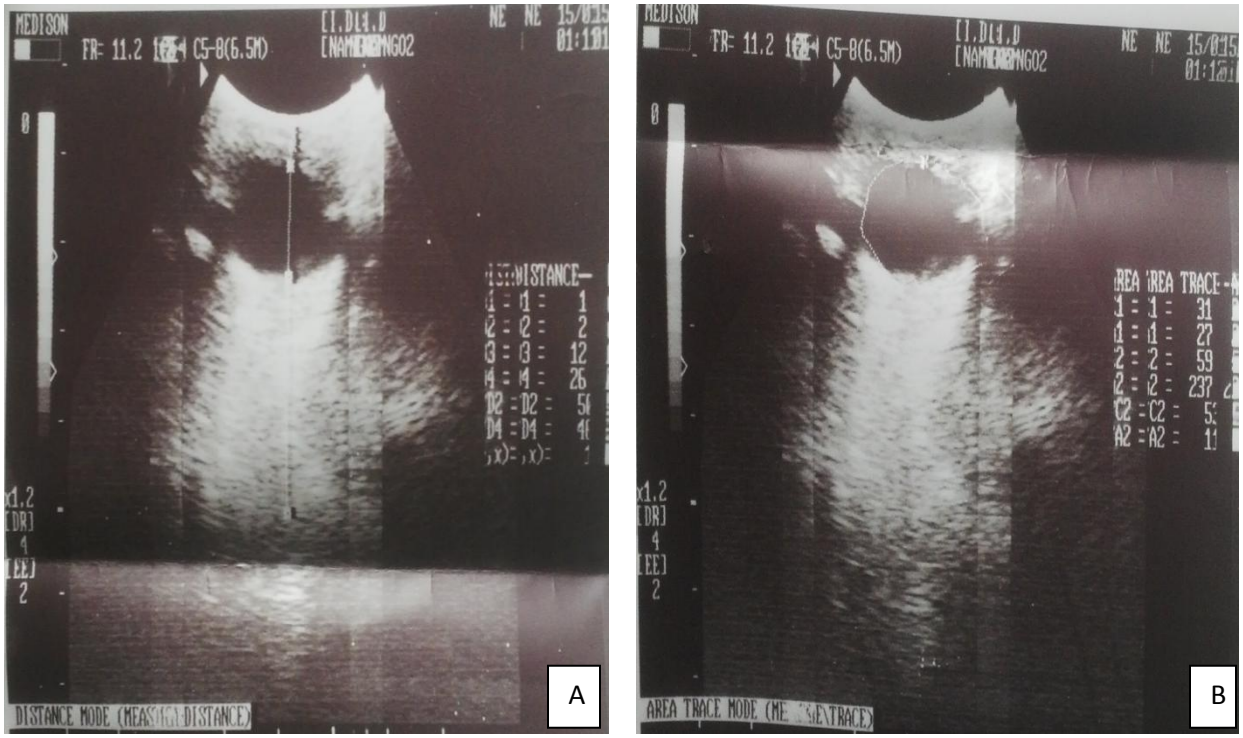

Plate VII: Sonogram of ocular biometry of one of the dogs in the puppy group (G1) of the Indigenous dogs that were studied - A (length biometry), B (Area biometry)
Note the axial globe length (D5: 41mm), corneal thickness (D1:1mm), the anterior chamber depth (D2: 2mm), lens thickness (D3: 12mm), and posterior chamber depth (D4: 26mm), Anterior chamber area (A1=27 mm^2), lens area (A2=237mm^2)

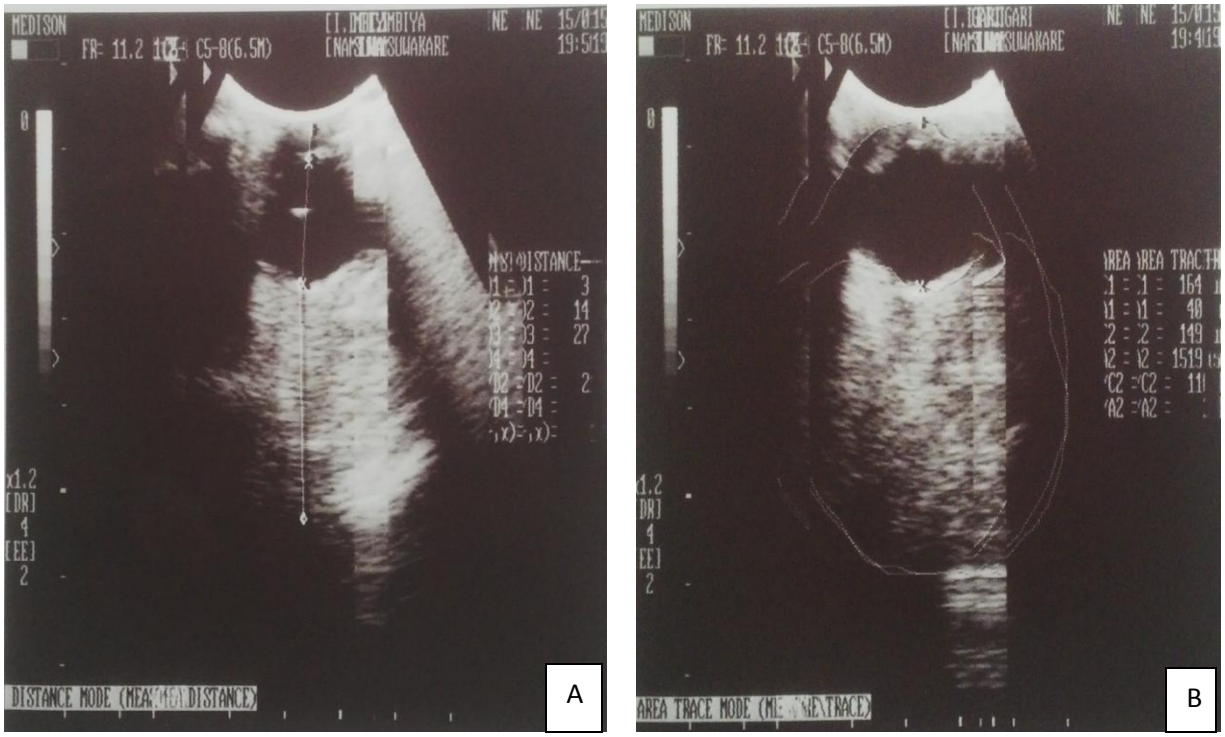

Plate VIII: Sonogram of ocular biometry of one of the dogs in the adult group (G2) of the indigenous dogs that were studied - A (length biometry), B (Area biometry)
Note the axial globe length (D5: 46mm), corneal thickness (D1:2mm), the anterior chamber depth (D2: 3mm), lens thickness (D3: 14mm), and posterior chamber depth (D4: 27mm), Vitreous chamber area (A3=1164 mm^2), globe area (A4=1519mm^2)

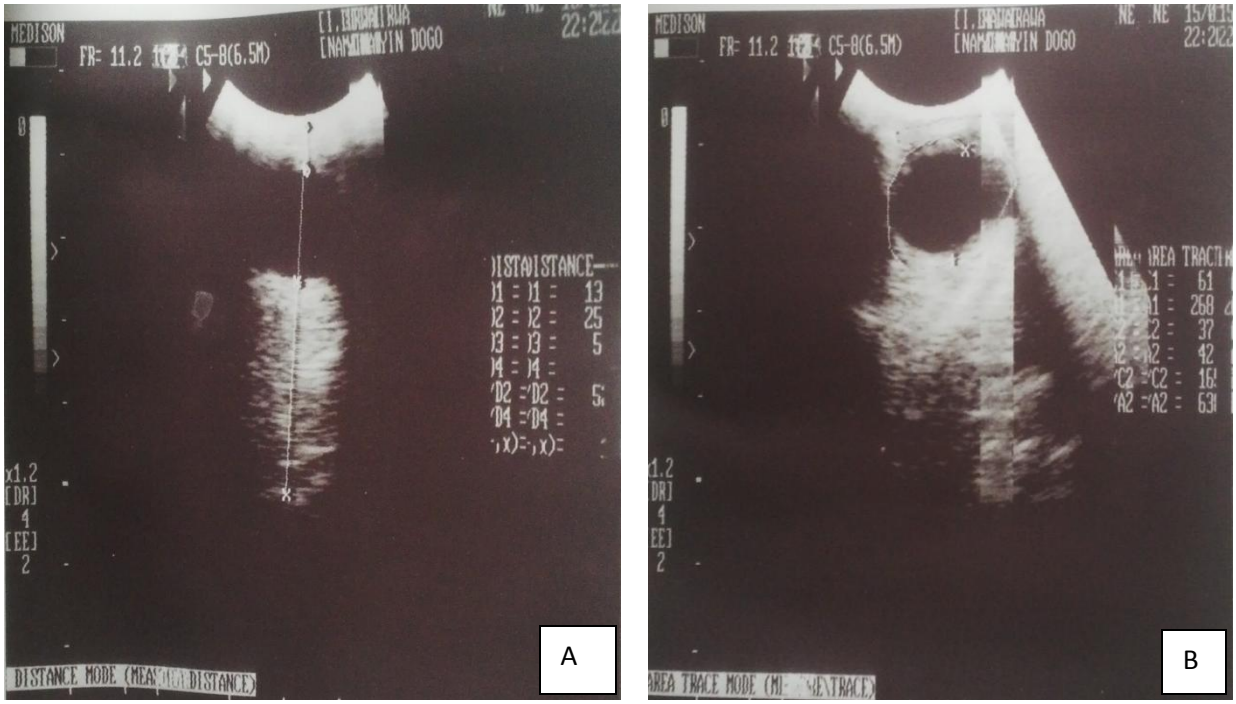

Plate IX: Sonogram of ocular biometry in the older group (G3) of the indigenous dogs that were studied – A (length biometry), B (Area biometry)

Note the axial globe length (D5: 43mm), corneal thickness (D1:2mm), the anterior chamber depth (D2: 3mm), lens thickness (D3: 13mm), and posterior chamber depth (D4: 25mm), Anterior chamber area (A1=37 mm^2), lens area (A2=268mm^2)

4.2.4 Ocular parameters of right and left eyes of study dogs

There was no significant change observed in the mean and standard deviation (± SD) of biometric readings among the right and left eyes of dogs within the same group ($P > 0.05$). However, the biometric readings for lens thickness (D3); vitreous length and area (D4 and A3); and axial length and globe area (D5 and A4) where significant within and between the groups G1, G2 and G3 ($P < 0.05$) as shown in tables 4.1 and 4.2 below.

Table 4.1: Mean and ±SD (mm) values for left and right intraocular structure measurements (length biometrics) comparing groups of dogs according to their age difference

Group No.	Corneal Thickness D1		Anterior Chamber depth D2		Lens Thickness D3		Vitreous Chamber depth D4		Sagital Length D5	Axis
	Left	Right	Left	Right	Left	Right	Left	Right	Left	Right
G1 (n=35)	1.17 ± 0.13a	1.20 ± 0.14a	2.23 ± 0.15a	2.43 ± 0.25a	13.34 ± 0.51a	11.89 ± 0.74a	23.06 ± 0.89a	22.97 ± 1.07a	39.77 ± 1.06a	38.51 ± 1.67a
G2 (n=26)	1.27 ± 0.18a	1.50 ± 0.21a	2.23 ± 0.21a	2.85 ± 0.32a	13.58 ± 0.83b	13.56 ± 0.864b	24.54 ± 1.55b	25.46 ± 1.45b	41.62 ± 1.55b	43.39 ± 1.50b
G3 (n=19)	1.76 ± 0.20a	1.76 ± 0.20a	2.43 ± 0.45a	2.57 ± 0.42a	14.67 ± 1.00ab	15.57 ± 0.86ab	23.95 ± 1.21ab	23.85 ± 1.62ab	42.67 ± 1.83ab	43.76 ± 2.29ab

Tukey test ($P < 0.05$)

Note: The same letters in a column indicate there was no difference between the groups ($p > 0.05$). Different letters in a row indicates the difference between groups ($p < 0.05$).

Table 4.2: Mean and ±SD (mm^2) values for left and right intraocular structure measurements (area biometrics) comparing groups of dogs according to their age difference

Group No.	Anterior Chamber Area A1		Lens area A2		Vitreous Chamber Area A3		Globe Area A4	
	Left	Right	Left	Right	Left	Right	Left	Right
1 (n=35)	30.46 ± 2.50a	31.20 ± 3.39a	238.66 ± 20.00a	188.77 ± 22.25a	968.89 ± 62.451a	893.06 ± 94.03a	1316.57 ± 69.00a	1357.17 ± 95.43a
2 (n=26)	32.96 ± 3.224a	35.96 ± 3.92a	254.39 ± 24.90a	246.27 ± 20.81a	1320.89 ± 561.38b	1046.96 ± 84.60b	1412.50 ± 51.66b	1498.62 ± 63.94b
3 (n=19)	30.46 ± 2.50a	31.76 ± 5.05a	260.38 ± 18.97a	269.24 ± 23.07a	1118.67 ± 61.21c	1120.57 ± 54.48c	1459.86 ± 84.50c	1495.91 ± 84.84c

Tukey test ($P < 0.05$)

Note: The same letters in a column indicate there was no difference between the groups ($p > 0.05$). Different letters in a row indicates the difference between groups ($p < 0.05$). A1: anterior chamber area. D2: lens area. D3: vitreous chamber area. D4: globe area

4.2.5 Ocular parameter and weight (size) of dogs

There was no correlation using Pearson's test was observed between corneal thickness value and the weight of the dogs in all the groups ($P > 0.05$). However, there was a positive correlation between weight and the other intraocular parameters that were measured in all groups ($P < 0.05$).

4.2.6 Ocular parameters variables in Male and Female dogs

There was no statistically significant relationship observed between the ocular parameters of the male and female ($P > 0.05$), within the groups (table 4.3). Similarly, no correlation was observed between IOP and lens thickness, D1 ($P > 0.05$). However, there existed a positive correlation as observed, between IOP and other intraocular parameters measured ($P < 0.05$), in all groups (see table 4.4).

Table 4.3: Relationships between mean (± SD) values of intraocular structures and gender using T-Test

Parameters	**Gender**	**G1(n=70 eyes) Male=25, Female=10**	**G2 (n=52 eyes) Male=12, Female=14**	**G3 (n=38eyes) Male=9, Female=10**
Corneal thickness	Male	1.18 ± 0.28	1.33 ± 0.33	1.67 ± 0.43
D1	Female	1.20 ± 0.26	1.43 ± 0.33	1.90 ± 0.21
Anterior depth	Male	2.26 ± 0.48	2.42 ± 0.36	2.67 ± 1.03
D2	Female	2.50 ± 0.62	2.64 ± 0.66	2.25 ± 0.76
Lens thickness	Male	13.44 ± 2.51	13.29 ± 1.27	15.39 ± 1.56
D3	Female	11.85 ± 1.16	13.82 ± 2.16	14.85 ± 2.25
Vitreous depth	Male	22.90 ± 2.26	24.29 ± 2.36	23.83 ± 1.30
D5	Female	23.30 ± 2.30	25.61 ± 4.21	23.05 ± 2.42
Axial length	Male	39.26 ± 2.90	41.33 ± 2.85	43.56 ± 2.34
D5	Female	38.85 ± 3.65	43.50 ± 3.51	41.90 ± 3.76
Anterior Area	Male	30.36 ± 6.11	34.29 ± 7.27	34.44 ± 13.05
A1	Female	32.00 ± 10.28	34.50 ± 9.08	29.40 ± 6.83
Lens area	Male	188.77 ± 22.25	246.27 ± 20.81	269.24 ± 23.07
A2	Female	161.04 ± 20.90	260.051 ± 23.76	269.97 ± 19.98
Vitreous Area	Male	943.36 ± 206.69	1098.67 ± 223.42	1170.56±41.91
A3	Female	900.00 ± 248.44	997.00 ± 93.66	1073.70 ± 133.15
Globe area	Male	1343.08 ± 213.03	1470.123 ± 154.92	1592.17 ± 174.52
A4	Female	1321.35 ± 278.65	1443.07 ± 107.40	1377.40 ± 110.74

T-Test ($P < 0.05$)

Table 4.4: Mean and ±SD (mm) values for intraocular structure measurements comparing groups of dogs according to their IOP readings.

Parameters	G1(n=70 eyes)	G2 (n=52 eyes)	G3 (n=38eyes)
Corneal thickness D1	1.20 ±.40584	1.5000±.50990	1.7895±.41885
Anterior depth D2	2.4286±.73907	2.8462±.78446	2.5263±.96427
Lens thickness D3	11.8857±2.16620	13.5769±2.13866	15.4737±1.89644
Vitreous depth D4	22.9714±3.10110	25.4615±3.59144	23.3158±2.60454
Axial length D5	38.5143±4.85902	43.3846±3.72104	43.1053±4.24126
Anterior area A1	31.2000±9.87212	35.9615±9.70971	31.5263±11.66366
Lens area A2	188.7714±64.75978	246.2692±51.53062	266.2632±52.39894
Vitreous area A3	893.0571±273.71711	1046.9615±209.46131	1114.2632±113.07512
Globe area A4	1357.1714±277.80817	1498.6154±158.30378	1484.2632±192.59394
IOP	13.3143±3.65233	13.1154±3.76114	13.1316±3.74849

Partial correlation ($P < 0.05$)

4.2.7 Percentage Area compartmentalization of Ocular Segments

The three (3) major ocular segments- anterior chamber, lens capsule and vitreous chamber represent approximately 2%, 17% and 76% respectively of the entire ocular globe area as demonstrated in figure 4.2. The remainder 5% is comprised of ciliary body and muscle, suspensory ligament and posterior chamber.

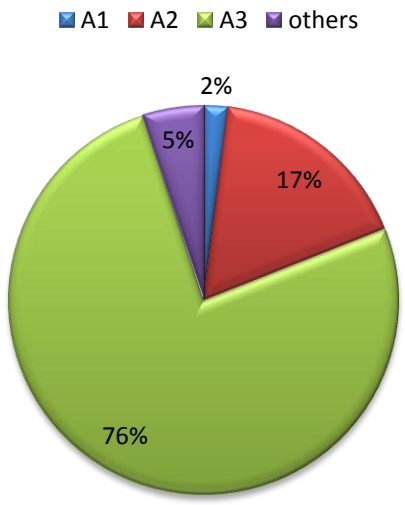

Figure 4.10: Percentage Area occupied by ocular chambers
Key: A1: anterior chamber area A2: lens capsule area A3: vitreous chamber area A4: others
Note: others represent area occupied by ocular structures other than the anterior chamber, lens and vitreous chamber, such as ciliary body and muscle, suspensory ligament and posterior chamber.

CHAPTER FIVE

5.0 Discussion

Numerous investigations have highlighted the accuracy of ultrasound in the detection of injuries to the chest, abdomen, musculoskeletal system, and eye (Rozycki *et al.,* 1993; Scalea *et al.,* 1999; Blaivas *et al.,* 2002; Dulchavsky *et al.,* 2001 and 2002). Recent studies have also shown that non-physician operators can reliably perform a number of focused clinical ultrasound examinations to facilitate on-site diagnosis (Shackford *et al.,* 1999).

Biometry of the globe has been undertaken with A-mode ultrasonography where it is used to determine axial length prior to intraocular lens implantation (Gaiddon *et al.,* 1992) or for research purposes (Ekesten, 1994). In this study, B-mode ultrasonography was used to determine values for ocular parameters of dogs in the study area. Published research has shown A-mode and B-mode ultrasonography to give axial measurements that were not statistically significantly different and thus implies that B-mode ultrasonography can be as accurate as A-mode biometry (Osuobeni and Hamidzada, 1999; Williams, 2004). Biometry results for the one hundred and sixty (160) eyes of indigenous dogs, in which serial measurements were taken in this study, suggest that inaccuracy did not appear to be a problem.

Pre-ultrasound ophthalmology and tonometry were feasible in all dogs by mild manual and psychological restraint. Ophthalmic ultrasound was achieved by mainly manual restraint, placing dogs on sternal recumbency and manual opening of the eyelids, which was described by Martins *et al.,* 2010. Thus, sedation and general anesthesia, proposed by earlier researchers such as Schiffer *et al.,* 1982 and Hager *et al.,* 1987, did not appear necessary in this circumstance. Therefore, anesthetic risks and additional costs were eliminated. All dogs were tolerant to

ultrasound examination of the eye and no iatrogenic injury on the corneal surface was observed; this concord with the findings of Martins *et al.* in 2010 and Toni *et al.* in 2010.

The use of the conductive gel acting as a standoff pad (Cottrill *et al.,* 1989), allowed adequate visualization of the cornea and anterior chamber, which was important for the obtaining reliable images and measurements. It also provided adequate contact of the transducer with the surface of the cornea, with minimal pressure on the eye, which resulted in less discomfort for the study animals, as stipulated by McMullen and Gilger, 2006; Wilkie *et al*., 2006 and Toni *et al*., 2010.

In the present study, there were no statistically significant differences observed when comparing the mean values obtained for intraocular biometric parameters between the right and left eyes of dogs in the same group (T – Test, with $P > 0.05$). This implied that the ocular parameters of the right and left eyes of a dog with healthy eyes were the same, confirming the same findings carried out in Samoyed dogs (Ekesten, 1994) and other species (Osuobeni and Hamidzada, 1999; Paunksnienė and Babrauskienė, 1996; Paunksnienė *et al.,* 1997; Ramsey *et al.,* 1999), including humans (Lim *et al.,* 1992). Therefore, measurements of the normal eye can provide reliable parameters for determination of the size of eye prosthesis in cases of malformation or enucleation of the eye. This is similar with the reports by other authors (Williams, 2004; Tuntivanich *et al.,* 2007).

However, the biometric values obtained for lens thickness, vitreous length and area, axial length and globe area were significant within and between the groups 1, 2 and 3 ($P < 0.05$). The finding revealed that these intraocular parameters increased from puppy to adult and old age. This finding were documented by earlier researchers that revealed that the ocular variables were influenced by age (Paunksnis *et al.,* 2001) or weight and size (Sampaio *et al.,* 2002 and Toni *et al.,* 2013). This feature is important considering the use of dogs as experimental models for the

study of myopia in humans (Black *et al.,* 2008; Williams *et al*., 2011), which remains a significant and highly prevalent worldwide problem (Toni *et al.,* 2013).

The values found in the present study for corneal thickness measured by B- scan ocular ultrasound biometry in Nigerian indigenous dogs were similar to those found in the study reported by Paunksnis *et al.,* (2001). However, values for other ocular parameters obtained, such as the anterior chamber depth, lens thickness, vitreous chamber depth and axial globe length were observed to be slightly higher than those found in the work of Paunksnis *et al.,* 2001. According to Ekesten in 1994, the corneal thickness increased throughout the dog's life; initially it grows rapidly, but later it grows more slowly. This was illustrated in the present study too. Paunknis and his study teams reported in 2001 that canine corneal thickness biometric values measured by different researchers may not exactly be the same.

Axial length is typically regarded as the primary determinant of refractive error. The correlation with refractive error is larger for axial length than for any other component of the eye (Mutti *et al.,* 2007; Fontes *et al.,* 2011). This study demonstrated and confirmed findings by Ekesten and Torrang in 1995 that axial length, increases with age. It was also observed that lens thickness increased with age from puppy to adult and older aged dogs, a feature that was noted in previous reports by Williams in 2004 in dogs and by Hoffer in 1993, in the human subjects. Similarly, this phenomenon was also observed in this study for corneal thickness. The findings also demonstrated that the anterior chamber depth and area, and vitreous length and area all increased initially with age from puppy to adult, but then decrease in older dogs. This could be due to the fact that increasing in lens thickness with age reduced the chambers of the eyes with which it borders with, i.e anterior chamber and vitreous chamber.

Significant increases in the axial globe length from young to adult and to older aged dogs was also documented by the findings of Tuntivanich *et al.* (2007). However, in the study of Tuntivanich *et al.* (2007), the axial globe length increased up to 52 weeks, and thereafter such increases were not significant.

There are conflicting findings in previous studies pertaining the influence of gender on ocular parameters (Gelatt and MacKay, 2005; Silver *et al.,* 2010). In this research, no differences were detected between male and female ocular parameters within the same groups using Turkey test ($P>0.05$). This therefore suggests that gender does not influence significantly ocular parameters of Nigerian indigenous dogs.

Paunksnis *et al.,* 2001 suggested that there was a relationship between ocular parameters of axial length, anterior length and vitreous length with weight of the experimental dogs used in their study. Similar finding was demonstrated in the present study. We observed a significant positive correlation ($P < 0.05$) between weight and anterior chamber length and area, lens thickness and area, vitreous length and area, and axial length and globe area. This implied that bigger and heavier dogs tend to posses greater values of ocular parameters.

No previous work has been established, to the best knowledge of the researcher, as to the influence of intraocular pressure (IOP) value on ocular parameters in dogs. In this research, it was revealed by means of partial correlation ($P < 0.05$), that there was a positive relationship between IOP and all ocular parameters (except corneal thickness) of Nigerian indigenous dogs' ocular parameters. However, it was established in previous work (Williams, 2004), that a significant reduction in the anterior chamber depth in eyes with diabetic cataracts may be a factor leading to raised intraocular pressure in some dogs, although correlating intraocular pressure

with cataract morphometry was difficult because of compounding factors such as lens induced uveitis.

The findings of the present study also revealed that the vitreous chamber was the largest area within the eye globe. Next to it was the lens area and the smallest was the anterior chamber area.

CHAPTER SIX

6.0 CONCLUSION AND RECOMMENDATION

6.1 Conclusion

Based on the findings arrived at in the present study it was possible to conclude that ophthalmic ultrasound in B-mode, was an effective method for the determination of the anatomical guide necessary for the performance of biometry of intraocular structures. Also, with an appropriate understanding of the indications for ocular ultrasonography and proper examination technique, one can gather a vast amount of information easily and quickly with ocular ultrasonography, which may not be possible with clinical examination alone in order to arrive at an acceptable diagnostic protocol and proffer management guide as well as prognosis for ocular conditions.

The intraocular parameters of length and area in the Indigenous Nigerian dogs' eyes are slightly lower than those of Exotic breeds and remarkably lower than those of the Dolicephalic exotic breeds. The lens thickness, vitreous thickness and sagital eyeball axis varied significantly and are age dependant. Ocular parameters of the left and right eye did not differ significantly in the Nigerian indigenous dogs. Similarly, the gender of Nigerian indigenous dogs did not exhibit influence on intraocular parameter values. However, age, size or weight and normal intraocular pressure values can be seen to influence ocular parameters values in indigenous dogs.

The ocular echobiometric readings of the extraocular strucuture (corneal thickness) did not differ significantly in the indigenous dogs based on weight, gender or intraocular pressure. Corneal thickness was also not uniform in adult dogs.

This study was the first to relate parameters of ocular structures in Nigerian indigenous dogs with age, gender, weight and size; and to document the portion by percentage of area occupied

by the three major compartments of the eyes. Therefore, the anterior, lens capsule and vitreous chambers represented 2%, 17% and 76% respectively, of the total ocular globe area.

6.2 Recommendation

An advanced research should be carried out to investigate ocular diseases or other systemic disease with ocular manifestation in Nigerian indigenous dogs, including ultrasound guided ocular biopsies, using a Doppler and or 3D- ultrasound machine.

A specialty of Veterinary ophthalmology should be created to accommodate research and training in ocular conditions; diagnosis, management (Medicine and surgery) and best management modalities should be groomed and established.

Veterinarians and clinicians should be encouraged to include routine ocular ultrasonography as part of regular ophthalmic examinations in patients presenting with ophthalmic conditions. In this vane, it is highly recommended that a standard portable ocular ultrasound unit be made available within the Small Animal Unit of the Veterinary Teaching Hospital, A. B. U Zaria and in any other standard Veterinary institutions.

REFERENCES

Abrams, K. L. (2001): Medical and surgical management of the glaucoma patient. Clinical techniques in small animal practice. 16(1): 71-76

Agrawa, A. and Biswas, J. (2011): Unilateral Vogt-Koyanagi-Harada Disease: Report of Two Cases. *Middle East African Journal of Ophthalmology*. 18(1): 82-84.

Anon[1] (2013): Ahmadu Bello University. http://www.abu.edu.ng/info/Zaria.php. Accessed 08/08/2013 12:32 pm.

Anon[2] (2000): Ahmadu Bello University. *Zaria Master Plan*, Department of Urban and Regional Planning, ABU Zaria, Nigeria.

Annon[3] (2014). www.iphohvet.com/Anatomyofdogeye. Accessed 23/02/2015, 15:49pm

Anon[4] (1998): Arts and Entertainment Network. Big dogs little dogs: The world of our canine companions. GT publishing corporation. 23-55. http://www.amazon.com/Bid-Dogs-Little-Canine-Companions/dp/ 1577193539. Accessed 03/01/2014 at 9:44 am.

Anon[5] (1996): Ministry of Economic Development. Kaduna State Statistical year book, Kaduna, Nigeria, Ministry of Economic Development, Statistics Division.

Anon[6] (1996): National Institutes of Health in the USA. *Laboratory Animal Control Guidelines, Guide for the Care and Use of Laboratory Animals.* NIH publications No. 86 to 23, revised

Anon[7] (2006): National Population Commission. Official records of the 2006 census. *National Population Commission*, Nigeria, Abuja, 2007.

Anon8 (1997): The Foundation of the American Academy of Ophthalmology. Museum of Vision and Ophthalmic Heritage 1997. www.museumofvision.org Accessed 11/11/2014, 9:23am

Attali-Soussay, K., Jegou, J. P. and Clerc, B. (2001). Retrobulbar tumors in dogs and cats: 25 cases. Veterinary Ophtalmology. 4:19-27.

Baum, G. and Greenwood, I. (1958). The application of ultrasonic location, techniques to ophthalmology: theoretic considerations and acoustic properties of ocular media: Part 1, Reflective properties. *American Journal of Ophthalmology*. 46:319-329.

Bedi, G. B.; Gombos, D. S.; Ng, C. S. and Singh, S. (2006). Sonography of the eye. *American Journal of Radiology*. 187:1061-72.

Bentley, E., Miller, P. E. and Diehl, K. A (2003). High resolution ultrasound as a diagnostic tool in veterinary ophthalmology. *Journal of American Veterinary Medical Association.* 223(11): 1617-1622.

Beránek, J. P. J. (2014). Current examination method of the canine eye. *European Journal of Companion Animal Practice*. 17(3):27-30

Black, J., Browning, S. R., Collins, A. V., Phillips, J. R. (2008). A canine model of inherited myopia: familial aggregation of refractive error in labrador retrievers. *Investigative Ophthalmology and Visual Science*. 49:11:4784-4789.

Blaivas, M.; Theodoro, D. and Sierzenski, P. R. (2002). A Study of Bedside Ocular Ultrasonography in the Emergency Department. *Academic Emergency Medicine.* 9:791–799.

Book, B., Van der Woerdt, A. Wilkie, D. A. (2008). Ultrasonographic abnormalities in eyes with traumatic hyphema obscuring intraocular structures: 33 cases (1991–2002). *Journal of Veterinary Emergency and Critical Care.* 18:383–387.

Boroffka, S.; Verbruggen, A. M.; Boevé, M. H. and Stades, F. C. (1998). Ultrasonographic diagnosis of persistent hyperplastic tunica vasculosa lentis /persistent hyperplastic primary vitreous in two dogs. Veterinary Radiology and Ultrasound. 39:440-444.

Boroffka, S. A.; Verbruggen, A. M. and Grinwis, G. C. (2007). Assessment of ultrasonography and computed tomography for the evaluation of unilateral orbital disease in dogs. *Journal of American Veterinary Medical Association.* 230:671–680.

Boroffka, S. A.; Voorhout, G. and Verbruggen A. M. (2006). Intraobserver and interobserver repeatability of ocular biometric measurements obtained by means of B-mode ultrasonography in dogs. *American Journal of Veterinary Research.* 67:1743-1749.

Brandy, C.; Hayden, B. S.; Kelley, L.; Arun, D. and Singh, M. D. (2008). Ophthalmic Ultrasonography: Theoretic and Practical Considerations. *Ultrasound Clinic Review*. 179–183

Brazitikos, P. D.; Tsinopoulos, I. T.; Papadopoulos, N. T. (1999). Ultrasonography classification and phacoemulssification of white senile cataracts. *Ophthalmology*.106:2178-2183.

Broadwater, J. J.; Schorling, J. J.; Herring, I. P. and Elvinger, F. (2008). Effect of body position on IOP in dogs without glaucoma. *American Journal of Veterinary Research*. 69(4): 527-530

Bronson, N. R. and Fisher, Y. L. (1976). Ophthalmic Contact B-Scan Ultrasonography for the Clinician. Westport, Connecticut., International Publications. Inc.27.

Byrne S. (1995). A-scan axial eye length measurements: *a handbook for IOL calculations*. Mars Hill (NC): Grove Park Publishers

Byrne, S. F. and Gendron, J. S. (1991). Diameter of normal extraocular recti muscles with echography. *American Journal of Ophthalmology*. 112:706.

Byrne, S. F. and Green, R. L, (1992). Extraocular muscles in *Ultrasound of the Eye and Orbit*, Mosby year book: 376.

Byrne, S. F. and Green R. L. (1992). Optic nerve in Ultrasound of the Eye and Orbit, Mosby year book: 403.

Byrne, S. F. and Green, R. L. (1992). Examination techniques for the globe in Ultrasound of the Eye and Orbit , Mosby year book: 42

Byrne, S. F. and Green, R. L. (2002). *Ultrasound of the eye and orbit.* 2nd ed. St Louis: Mosby.

Chopin, J. (2011). The Proceedings of the 2011 Equine Chapter Meeting at the ACVSc Science Week Gold Coast International Hotel Gold Coast, Queensland, Australia Proceedings Edited. 22-26

Chugh, J. P.; Susheel, M. and Verma, A. (2001). Role of Ultrasonography in Ocular Trauma. *Indian Journal of Radiology and Imaging*. 11: 75-9.

Coleman, D. J.; Lizzi, F. L. and Jack, R. L. (1977). *Ultrasonography of the eye and orbit*. Philadelphia: Lea and Febiger.

Cottrill N. B., Banks W. J. and Pechman R. D. (1989). Ultrasonographic and biometric evaluation of the eye and orbit of dogs. *American Journal of Veterinary Research*.50,(6):898-903.

Czederpitlz, J. M. (2005). Putative aqueous humor misdirection syndrome as a cause of glaucoma in cats: 32 cases (1997-2003). *Journal of American Veterinary Medical Association*. 227:1434-41.

David, A. (1984). *Dog*: The Most Complete, illustrated, Practical Guide to dogs and their World. Book sales Inc and MACDONALD Publishing. 98-105

David L. W. (2004). Lens morphometry determined by B-mode ultrasonography of the normal and cataractous canine lens. *Veterinary Ophthalmology*. 7(2): 91–95 Blackwell Publishing Ltd.

Davidson, M. G. and Nelms, S. R. (1999). Diseases of the lens and cataract formation. In: Gelatt K.N. (Ed.), *Veterinary Ophthalmology*. 3rd ed. Lippincott Williams and Wilkins, Philadelphia 818-828

Davis, J. (1998). Dr P's Dog Training: Vision in Dogs and People. Dog world. www.uwsp.edu/psych/dog/la/davis2.htm. Accessed 12/12/2014, 9:15am

Diaz, D. (2004): Collaborative ocular melanoma study; Echography (Ultrasound): Iodine-125 plaque therapy. *American journal of clinical oncology.* 22:2483-2444

Dietrich, U. M. (2007). Ophthalmic examination and diagnostics part 3: diagnostic ultrasonography. In: Gelatt KN, ed. *Veterinary ophthalmology*. 4th ed. Ames, Iowa: Blackwell Publishing. 507–519.

Dulchavsky, S. A.; Schwarz, K. L. and Kirkpatrick, A. W. (2001). Prospective evaluation of thoracic ultrasound in the detection of pneumothorax. *Journal of Trauma.*50:201–205.

Dulchavsky, S. A.; Henry, S. E.; Moed, B. R.; Diebel, L. N.; Marshburn, T.; Hamilton, D. R.; Logan, J.; Kirkpatrick, A. W. and Williams, D. R. (2002). Advanced ultrasonic diagnosis of extremity trauma: the FASTER examination. *Journal of Trauma.*53:28 –32.

Dyce, K. M.; Sack, W. O and Wensing, C, J, G. (2010). *Veterinary Anatomy*. Saunders NewYork.

Ekesten B. (1994). Biological variability and measurement error variability in ocular biometry in Samoyed dogs. *Acta veterinaria Scandinavica*.35:427-433.

Ekesten, B. and Torrang, I. (1995). Heritability of the depth of the opening of the ciliary cleft in Samoyeds. *American Journal of Veterinary Research*. 56:1138-1143.

Evans, H. E. (1993). Anatomy of the Dog. In Miller's *Anatomy of the Dog* 3rd Ed. Ithaca, NewYork

Ferrer, E.; Ros Mendoza, L. H.; Dessi, G.; Stefanini, T.; Zaragoza, E. S. and La spezia, I. T. (2013). Role of B-scan ocular ultrasound as adjuvant for the clinical assessment of eyeball diseases. European Society of Radiology. EPOS™. www.myESR.org assessed on 9/11/2014 2:15PM

Fontes, B. M.; Fontes, B. M.; Castro, E. (2011). Intraocular lens power calculation by measuring axial length with partial optical coherence and ultrasonic biometry. *Arquivo Brasileiro de Oftalmologia.*74(3):166-170.

Gaiddon J.; Rosolen S. G.; Steru, L. (1992). Use of biometry and keratometry for determining optimal power for intraocular lens implants in dogs. *American Journal of Veterinary Research*. 52(5):781-783

Gelatt-Nicholson, K. J.; Gelatt, K. N. and Mackay, E. (1999). Doppler imaging of the ophthalmic vasculature of the normal dog: blood velocity measurements and reproducibility. *Veterinary Ophthalmology.* 2:87-96.

Gelatt, K. N. (2000). *Essentials of Veterinary Ophthalmology*, Lippincott Williams and Wilkins, Philadelphia, Pennsylvania, USA

Gelatt , K. N. (2007). *Veterinary Ophthalmology* , Blackwell Publishing, Iowa, USA

Gellat, K. N.; Brooks, D. E. and Kallberg, M. E. (2007). The canine Glaucoma. In Gellat KN, ed. *Veterinary Ophthalmology* 4th ed. Ames, Iowa: Blackwell Publishing; 753-811

Gelatt, K. N. and Mackay, E. O. (2004). Secondary glaucoma in the dog in North America. Veterinary Ophthalmology. 7:245-259.

Gelatt, K. N. and Mackay, E.O. (2005). Prevalence of primary breed-related cataracts in the dog in North America. Veterinary Ophthalmology. 8:101-111.

Gift, B. W., English, R. V., Nadelstein, B., Weigt, A. K. and Gilger, B. C. (2009). Comparison of capsular opacification and refractive status after placement of three different intraocular lens implants following phacoemulsification and aspiration of cataracts in dogs. *Veterinary Ophthalmology*. 12(1):13-21, 2009.

Giglio, E. (1977). Diagnostic Ultrasound Application of A-Scan to the eye. In Sherman, J.: *Advanced diagnostic Procedures*. Duncan, OKLA., Optometric Extension Foundation.

Giglio, E. and Sherman, J. (1979). Ophthalmic Ultrasound as a Diagnostic Tool. *Journal of American Optometry association*. 50: 73-8.

Giglio, E. J. and Ludlam, W. M. (1967). High resolution ultrasonic equipment to measure intra-ocular distances. *Journal of American Optometry Association*. 38:367–371.

Gilger, B. C., Davidson, M. G. and Howard, P. B. (1999). Keratometry, ultrasonic biometry, and prediction of intraocular lens power in the feline eye. *American Journal of Veterinary Research*.59(2):131-134.

Gilger B. C. and Whitley R. D. (1991). Canine corneal thickness measured by ultrasonic pachymetry. *American Journal of Veterinary Research*.52(10):1570-1572.

Gilger B. C. and Wright J. C. (1993). Corneal thickness measured by ultrasonic pachymetry in cats. *American Journal of Veterinary Research*.52(2):228-230.

Gonçalves, G. F., Pippi, N. L., Raiser, A. G., Mazzanti, A., Oliveira, S. T., Neves, J. P., Leotte, A. M. and Hintz, C. W. (2000). Biometria ultra-sonográfica bidimensional em temporeal do globo ocular de cães. Ciência Rural.30(3):417-420.

Gonzalez, E. M., Rodriguez, A. and Garcia, I. (2001). Review of ocular ultrasonography. Veterinary Radiology & Ultrasound. 42:6:485-495.

Gorig, C.; Coenen, R. T. and Stades, F. C. (2006). Comparisons of use of new handheld tonometer and established applanation tonometer in dogs. *American Journal of Veterinary research*. 67(1): 134-144

Grahn, B. H.; Storey, E. S. and Mcmillan, C. (2004). Inherited retinal dysplasia and persistent hyperplastic primary vitreous in miniature Schnauzer dogs. *Veterinary ophthalmology*. 7(3):151-158

Grahn, B. H.; Cullen, C. L. and Peiffer, R. L. (2004). *Veterinary Ophthalmology Essentials*, Butterworth –Heinemann, Philadelphia, Pennsylvania, USA

Hager, D. A.; Dziezyc, J.; Millchamp, N. J. (1987). Two- dimensional real-time ocular ultrasonography in the dog. *Veterinary Radiology*.28(2):60-66.

Hassan, A. Z; Kadima, K. B.; Remi-adewumi, B. D.; Awasum, C. A. and Abubakar, M. T. (2005): Animal models in surgical training: Choice and ethics. Review. *Nigerian journal of surgical research*.7(3–4): 260-267.

Hoffer, K. J. (1993). Axial dimension of the human cataractous lens. *Archives of Ophthalmology*.111: 914–918.

Hoffmann, I. and Köstlin, R. (2004). Die sonographische Untersuchung des vorderen Augenabschnittes beim Kleintier. Teil 1: Untersuchungstechnik und echographische Normalbefunde. *Tierarztl Prax K.* 32:175–179.

Hoffmann, I. Schäffer, E. and Reese, S. (2004). Die sonographische Untersuchung des vorderen Augenabschnittes beim Kleintier. Teil 2: pathologische Befunde. *Tierarztl Prax K.* 32:238–246.

Hofmeister, E. H., Mosunic C. B., Torres B. T. (2006). Effects of ketamine, diazepam, and their combination on intraocular pressures in clinically normal dogs. *American journal of veterinary research*. 67:1136-1139

Jakobiec, F. A. and Font R. L. (1986). Orbit, in Spencer WH: *Ophthalmic Pathology*-An atlas and Textbook, ed 3. Philadelphia, WB Saunders Co:2766

Kumar, S and Goel, R. (2011). Diagnostic Ultrasonography of the Eye. All India Ophthalmological Society, New Delhi – 110029 (India) CME SERIES (No. 24)

Labruyere J. J., Hartley, C., Rogers, K. (2008). Ultrasonographic evaluation of vitreous degeneration in normal dogs. Veterinary Radiology and Ultrasound. 49(2):165-171.

Labruyere, J. J., Hartley, C. and Holloway, A. (2011). Contrast-enhanced ultrasonography in the differentiation of retinal detachment and vitreous membrane in dogs and cats. *Journal of Small Animal Practice.* 52:522–530.

Leiva, M.; Naranjo, C. and Peña, M. T. (2006). Comparison of the rebound tonometer (ICare®) to the applanation tonometer (Tonopen XL®) in normotensive dogs. *Veterinary Ophthalmology.* 9(1): 17-22.

Lim, K. J., Hyung, S. M., Youn, D. H. (1992). Ocular dimensions with aging in normal eyes. *Korean Journal of Ophthalmology*.6:19-31.

Maggs, D. J 2013. Pearls of the ophthalmic exam. Academy seminar proceedings. Veterinary Ophthalmology. 1-6

Maggs, D.; Paul Miller and Ron Ofri. (2008). Slatter's *Fundamentals of Veterinary Ophthalmology*, 4th edition.

Mason, D. R., Lamb, C. R. and McLellan, G. J. (2001). Ultrasonographic findings in 50 dogs with retrobulbar disease. *Journal of American Veterinary Medical Association*. 37(6): 557-562.

Martin, C. L. (2001). Evaluation of Patients with decreased vision or blindness. Clinical techniques in small animal practice. 16(1): 62-70

Martins, B. C.; Rodrigues Jr, E. F.; Souza, A. L. G.; Almeida, D. E.; Brito, F. L.; Canola, J. C.; Brooks, D. E.; Laus, J. L. (2010). A and B mode ultrasonography in preoperative evaluation of lens and posterior segment of dogs eyes with cataract. *Pesquisa Veterinária Brasileira*.30(2):121-126.

McMullen R. J. Jr., Davidson, M. G., Campbell, N. B., Salmon, J. H. and Gilger, B. C. (2010). Evaluation of 30- and 25-diopter intraocular lens implants in equine eyes after surgical extraction of the lens. *American Journal of Veterinary Research*.71:809-816.

McMullen R. J. Jr, and Gilger B. C. (2006). Keratometry, biometry and prediction of intraocular lens power in the equine eye. *Veterinary Ophthalmology*. 9:357-360.

Mettenleiter, E. M. (1995). Sonographic diagnosis (B-mode technique) for the eyes in horses. 1. Methods and normal findings. *Tierarztl Prax* .23:481–488.

Miller, M. E. and Evans, H. E. (2013). Miller's *Anatomy of the Dog*. Erun de lara. 4th ed. Elsevier Health. Saunders. NewYork.

Miller, P. E and Murphy C. J. (1995). Vision in dogs. *Journal of American Veterinary Medical Association*. 207:12

Miller, P. E. and Picket, J. P. (1992). Comparison of the human and canine Schiotz tonometry conversion tables in clinically normal dogs. *Journal of American Veterinary Medical Association.* 201(7): 1021-1025

Mundt, G. H. and Hughes, W. E. (1956). Ultrasonics in ocular diagnosis. *American Journal of Ophthalmology*. 41:488- 498.

Mutti, D. O.; Hayes, J. R.; Mitchell, G. L.; Jones, L. A.; Moeschberger, M. L.; Cotter, S. A.; Kleinstein, R. N.; Manny, R. E.; Twelker, J. D.; Zadnik, K. (2007). Refractive error, axial length, and relative peripheral refractive error before and after the onset of myopia. *Investigative Ophthalmology and Vision Science*.48(6):2510-2519.

Nyland, T. G. and Mattoon, J. S. (1995). *Veterinary diagnostic ultrasound*. W.B. Saunders company. P.178-197.

Oksala, A. and Lehtinen A. (1957). Diagnostic value of ultrasonics in ophthalmology. Ophthalmologica. 134:387–395.

Oksala, A. and Lehtinen A. (1958). A measurement of the velocity of sound in some parts of the eye. Acta Ophthalmol (Copenh).36:633–639.

Ossoinig, K. C. (1984). Ultrasonic diagnosis of Grave's ophthalmopathy, in Gorman CA, Waller RD, Dyer JA (eds): *The eye and orbit* in Thyroid disease. New York, Raven Press.

Ossoinig, K. C. (1979). Standardized echography: basic principles, clinical applications and results. *International Ophthalmology Clinics*.19:127-210.

Ossoinig, K. C.; Cennamo, G. and Byrne S. F. (1981). Echographic differential diagnosis of optic nerve lesions, in Thijssen JM, Verbeek AM(eds): Ultrasonography in Ophthalmology, Dordrecht, Dr WJunk: 327.

Osuobeni, E. P. and Hamidzada, W. A. (1999). Ultrasonographic determination of the dimensions of ocular components in enucleated eyes of the one-humped camel. *Research in veterinary science*.67:125-129.

Paul, A. M; Bentley, E.; Diehl, K. A. and Miller, P. E. (2006). Effects of neck pressure by a colar or harness on IOP in dogs. *Journal of American Animal Hospital Association*. 42(3): 207-248

Paunksnienė, M. and Babrauskienė, V. (1996). Structural peculiarities of domestic eye tunics. *Veterinarija ir zootechnika. T*.1(23):90-94.

Paunksnienė, M., Babrauskienė, V., Paunksnis A. (1997). Ultrasonographic evaluation of animal eye dimensions. *Veterinarija ir zootechnika. T*.3(25):29-33.

Paunksnis, A.; Svaldenienė, S.; Paunksnienė, M. and Babrauskienė, V. (2001). Ultrasonographic evaluation of the eye parameters in dogs of different ages. ISSN 1392-2114 *ULTRAGARSAS*, Nr.2(39).

Penninck, D.; Daniel, G. B. and Brawer, R. (2001). Cross-sectional imaging techniques in veterinary ophthalmology. Clinical Techniques in Small Animal Practice. 16(1):22-30.

Petersen- Jones, S. M. and Crispin, S. M. (2002). *BSAVA Manual of Small Animal Ophthalmology* , 2nd edn. British Small Animal Veterinary Association , Gloucester, UK

Petite, A. (2009). Ocular Ultrasonography. In: Britsh Samal Animal Veterinary Association, 2009, Birmingham. *Proceedings…, Gloucester: British Small Animal Veterinary Association.*

Potter, T. J.; Hallowell, G. D. and Bowen, I. M. (2008). Ultrasonographic anatomy of the bovine eye. *Veterinary Radiology and Ultrasound*. 49: 172-175.

Purnell, E. W. (1969). B mode orbital ultrasonography. *International Ophthalmology Clinics*.9:643-665

Rai, P.; Ali Shah, S. I.; Cheema, A. M.; Niazi, J. H. and Sidiqui, S. J. (2007). Usefulness of B-Scan Ultrasonography in Ocular Trauma. *Pakistan Journal of Ophthalmology* , 23(3).

Ramirez, S. and Tucker, R. L. (2004). Ophthalmic imaging. *Veterinary Clinic of North American Equine Practice*.20:441–457.

Ramsey, D. T., Hauptman, J. G, Petersen-Jones, S. M. (1999). Corneal thickness, intraocular pressureand optical corneal diameter in Rocky Mountain Horses with cornea globosa or clinically normal cornea. *American Journal of Veterinary Research*. 60:1317-1321.

Reef, VB. (1998). Ultrasonographic evaluation of small parts. In: Reef VB, ed. *Equine diagnostic ultrasound.* Philadelphia*:* W. B. Saunders Company; 480–547.

Reinstein, S. L.; Rankin, A. J. and Allbaugh, R. (2009). Canine glaucoma: pathophysiology and diagnosis. Compendium of continuing education for Veterinarians; 1: 450-453

Renwick, P. W. (1993). Glaucoma. In: Petersen-Jones SM, Crispin S. Manual of Small Animal Ophthalmology. *British Small Animal Veterinary Association*, 193-211.

Ribeiro, A. P., Silva, M. L., Rosa, J. P., Souza, S. F., Teixeira, I.A. and Laus, J. L. (2009). Ultrasonographic and echobiometric findings in the eyes of Saanen goats of different ages. Veterinary Ophthalmology. 12:5:313-317.

Rozycki, G. S.; Ochsner, G. M.; Feliciano, D. V.; Thomas, B.; Boulanger, B.; Davis F. E.; Falcone, R. E. and Schmidt, D. A. (1993). Early detection of hemoperitoneum by ultrasound examination of the right upper quadrant: A Multicenter Study. *Journal of Trauma*.45:878–883.

Sampaio, G. R.; Ranzani, J. J. T.; Shellini, S. A. (2002). Sexo, peso e conformação anatômica do olho sobre o cálculo de poder dióptrico de lentes intra-oculares no cão. Ciência Rural. 32(2):263-268.

Scalea, T. M.; Rodriguez, A. and Chiu, W. C. (1999). Focused Assessment with Sonography for Trauma (FAST): results from an international consensus conference. *Journal of Trauma*.46:466 –472.

Schiffer, S. P.; Rantanen, N. W.; Leary, G. A.; Bryan, G. M. (1982). Biometric study of the canine eye using A-mode ultrasonography. *American Journal of Veterinary Research*.43(5):826-830.

Schoster, J. V. (2006). *Normal fundus and variations in Dog, Cat and Horse*, University of Pensylvania, School of Veterinary Medicine, Ophthalmology. Madisyn Norford. 4-33.

Schoster J. V., Wickman L. and Stuhr C. (1995). The use of ultrasonic pachymetry and computer enhancement to illustrate the collective corneal thickness profile of 25 cats. *Veterinary and comparative ophthalmology*.5(2):68-73.

Scotty, N. C. and Cutler, T. J. (2004). Diagnostic ultrasonography of equine lens and posterior segment abnormalities. *Veterinary ophthalmology*. 7:127-139

Scotty, N.C., Cutler, T.J., Brooks, D.E. and Ferrell, E. (2004). Diagnostic ultrasonography of equine lens and posterior segment abnormalities. Veterinary Ophthalmology. 7:127-139.

Seiler, G. S. (2011). Ocular imaging techniques. Veterinary Radiology and Ultrasound. 52(3):313-316. www.cvm.ncsu.edu/.../seiler_ accessed on 23/03/2014 at 12:16HR

Shackford, S. R.; Rogers, F. B. and Osler, T. M. (1999). Focused abdominal sonogram for trauma: the learning curve of nonradiologist clinicians in detecting hemoperitoneum. *Journal of Trauma*.46:553–564.

Shaw, G. (2011). The Eye Anatomy, Histology & Histopathology. gilliancshaw@gmail.com accessed on 04/04/2014 15:35 HR

Silva, F., Osorio, M., Brito, C., Sousa, A., Godhino, C., Valente, F. and Gomes, A. (2013). Anophthalmia and Microphthalmia: A Clinical case with prenatal diagnosis. *Diagnostico prenatal*. Diapre108:1-4

Silva, M. L.; Martins, B. C.; Ribeiro, A. P.; Groszewicz de Souza, A. L. and Laus, J. L (2010). A- and B-modes echobiometry in cataractous and non-cataractous eyes of English Cocker Spaniel dogs *Brazilian Journal of Veterinary and Animal Sciences*.62(5):1080-1085.

Slatter, D. (1990). *Fundamentales of Veterinary Ophthalmology*. 2nd ed. WB Saunders Co.Philadelphia. 233-237

Slatter, D. and Basher, T. (2002). Orbit**.** In: *Textbook of Small Animal Surgery*, 3rd ed. (ed. Slatter D) W.B. Saunders, Philadelphia. 1430–1451.

Spaulding, K. (2008). Eye and orbit. In: Penninck D. (ed.) *Atlas of small animal ultrasonography*. Blackwell, Ames. P 49-91.

Strubbe and Gelatt. (1999). Ophthalmic examination and diagnostic procedures. In: Gelatt KN. *Veterinary Ophthalmology* 3rd ed. Lippincott Williams & Wilkins, 459-462.

Svaldenienė E., Paunksnienė M., Babrauskienė V. (1998). Canine corneal thickness peculiarities in vivo and after eye ball enucleation. Veterinarija ir zootechnika. 6(28):38-40.

Toni, M. C.; Meirelles, A. E. W. B.; Laus, J. L and Canola, J. C. (2013). Ophthalmic ultrasound of dogs with different skull conformations. *Revista Brasileira de Ciências Agrárias.* Recife.8(2):331-335.

Toni, M. C.; Meirelles, A. E. W. B.; Gava, F. N.; Camacho, A. A.; Laus, J. L.; Canola, J. C. (2010). Rabbits' eye globe sonographic biometry. *Veterinary Ophthalmology*.13(6):384-386.

Tuntivanich, N., Petersen-Jones, S. M., Steibel, J. P., Johnson, C. and Forcier, J. Q. (2007). Postnatal development of canine axial globe length measured by B-scan ultrasonography. Veterinary Ophthalmology.10(1):2-5.

Van der Woerdt, A., Wilkie, D. A. and Myer, W. (1993). Ultrasonographic abnormalities in eyes of dogs with cataracts: 147 cases (1986-1992). *Journal of American Veterinary Medical Association*. 203:838-841.

Whitcomb, M.B. (2002). How to diagnose ocular abnormalities with ultrasound. Proceedings in American Association of Equine Practitioners 481: 272-275

Whittaker, C. J. G.; Gelatt, K. N. and Wilkie, D. A. (1999). Food animal ophthalmology. In: *Veterinary Ophthalmology*, 3rd ed. (ed. Gelatt KN) Lippincott Williams and Wilkins, Philadelphia, PA: 1117- 1176.

Wilkie, D. A.; Gemensky-Metzler, A. J.; Colitz, C. M. H.; Bras, I. D.; Kuonen, V. J.; Norris, K. N.; Basham, C. R. (2006). Canine cataracts, diabetes mellitus and spontaneous lens capsule rupture: a retrospective study of 18 dogs. *Veterinary Ophthalmology*.9(5):328-334.

Williams, D. L. (2004). Lens morphometry determined by B-mode ultrasonography of the normal and cataractous canine lens. *Veterinary Ophthalmology*.7,(2):91-95.

Williams, L. A., Kubai, M. A., Murphy, C. J. and Mutti, D. O. (2011). Ocular components in three breeds of dogs with high prevalence of myopia. Optometry and Vision Science.88:2:269-274.

Wollanke, B. and Gerhards, H. (2011). Atlas der Ultraschalluntersuchung beim Pferd. In: Glatzel P, ed. *Atlas der Ultraschalluntersuchung beim Pferd*. Hannover, Germany: Schlütersche Verlagsgesellschaft mbH Co KG.

Wong, T. Y., Foster, P. J. (2001). Variations in ocular biometry in adult Chinese population in Singapore: the Tanjong Pagar Survey. Investigative Ophthalmology and Visual Science.42:73-80.

Wrycha, K. (2014). Anatomy and Histology of the Canine and Feline Eye. Dubielzig Lab www.vetmed.wisc.edu/pbs/dubielzig/page accessed 9/14/2014 9:24AM

APPENDICES

APPENDIX Ia:
GROUPING OF INDIGENOUS DOGS THAT UNDERWENT OPHTHALMIC EXAMINATIONS PRE OCULAR ULYTRASONOGRAPHY (GROUP ONE)

	GROUP ONE	35 DOGS	(70 EYES)	MALE=15	FEMALE=10	
DOG ID	SEX	AGE(months)	WEIGHT (kg)	SIZE	RIOP (mmhg)	LIOP (mmhg)
Major	M	2.75	3.7	small	14-18	14-18
Mayya	F	2.75	3.1	small	14-18	14-18
Bingo-pup1	F	0.75	1	medium	14-18	14-18
Bingo-pup2	M	0.75	1.6	medium	14-18	14-18
Bingo-pup3	M	0.75	1	medium	14-18	14-18
Bingo-pup4	F	0.75	0.8	medium	14-18	14-18
Bingo-pup5	M	0.75	1.2	medium	14-18	14-18
Bingo-pup6	M	0.75	1	medium	14-18	14-18
Blacky	M	2.5	3	medium	14-18	14-18
Suzzy	F	4	5	medium	14-18	14-18
Puppy	M	7	17	medium	14-18	14-18
Smart1	F	4	4	small	18-21	14-18
Loveline	F	3	4.5	small	18-21	10-14
Jack2	M	3	2	small	10—14	10-14
Rugged	M	9	14	medium	10—14	10-14
Jack3	M	2.5	2.5	medium	10—14	10-14
Boss	M	2.5	2	medium	14-18	10-14
Rugeed-pup1	F	1	1.5	small	10—14	10-14
Rugged-pup2	M	1	0.8	small	10—14	10-14
Rugeed-pup3	M	1	1.2	small	10—14	10-14
Rugged-pup4	M	1	1	small	10—14	10-14
Daure	M	8	11	medium	10—14	10-14
Dinga	M	12	10	medium	7—10	7-10
Turawa	F	8	6	medium	7—10	7-10
Womanda	M	8	7	medium	7—10	7-10
Bature	M	8	9	medium	14-18	10-14
Bullet	M	10	9	medium	14-18	10-14
Escort	M	12	17	medium	14-18	14-18
Germus	M	11	9	medium	14-18	14-18
Zaki-D	M	12	9.5	medium	7—10	7-10
Smart-D	F	12	11	medium	5—7	5-7
Gimbiya	M	12	15	medium	10—14	14-18
Police	M	12	10	medium	5—7	5-7
Tiger-M	M	12	17	medium	7—10	7-10

APPENDIX Ib:

GROUPING OF INDIGENOUS DOGS THAT UNDERWENT OPHTHALMIC EXAMINATIONS PRE OCULAR ULYTRASONOGRAPHY (GROUP TWO)

	GROUP TWO	26 DOGS	(52 EYES)	MALE=12	FEMALE=14	
DOG ID	SEX	AGE (months)	WEIGHT (kg)	SIZE	RIOP (mmhg)	LIOP (mmhg)
Tanker	F	42	21	medium	14-18	14-18
Bingo1	F	36	23	small	14-18	14-18
Bingo2	F	18	14	medium	14-18	14-18
Bingo3	M	18	23	medium	14-18	14-18
Blondy	M	18	20	medium	14-18	14-18
Cheleku	F	18	14	Dwarf	14-18	14-18
Bakasi	F	36	24	medium	18-21	18-21
Jack1	M	15	14	medium	14-18	10-14
Smart2	F	18	13	medium	14-18	10-14
Dinya	F	24	16	medium	14-18	14-18
Tega	F	36	15	medium	10—14	10-14
Jega	M	18	22	medium	10—14	10-14
Ebola	M	30	22	medium	7—10	7-10
Tiger	F	48	14	medium	10—14	10-14
Sophy	F	30	17	medium	14-18	14-18
Rambo	M	18	11	medium	5—7	5-7
Killer	M	18	14	medium	7—10	7-10
Rumpa	M	18	15	medium	14-18	14-18
Magajiya	F	24	11	medium	14-18	14-18
Shurwa	F	30	12	small	7—10	7-10
Iska	F	24	19	medium	7—10	7-10
Simbad	M	36	15	medium	7—10	7-10
Maiyaki	M	36	40	medium	7—10	7-10
Dogari	F	24	18	medium	7—10	7-10
Shago	M	48	24	medium	10—14	7-10
Barri	M	36	12	medium	14-18	14-18

APPENDIX Ic:

GROUPING OF INDIGENOUS DOGS THAT UNDERWENT OPHTHALMIC EXAMINATIONS PRE OCULAR ULYTRASONOGRAPHY (GROUP THREE)

	GROUP 3	19 DOGS	(38 EYES)	MALE=9	FEMALE=10	
DOG ID	SEX	AGE (months)	WEIGHT (kg)	SIZE	RIOP (mmhg)	LIOP (mmhg)
Abarbada	M	168	19	medium	5—7	5-7
Zaki-M	M	192	20	medium	7—10	7-10
Snicks	M	60	16	medium	10—14	10-14
Tina	F	132	17	medium	10—14	10-14
Bulus	F	144	18	medium	18-21	18-21
Gambari	F	120	18	medium	18-21	14-18
Jikaji	M	84	17	medium	18-21	18-21
Barau	F	108	13.5	medium	14-18	14-18
Kamji	F	60	14.5	medium	10—14	10-14
Gaggaro	M	96	16	medium	10—14	10—14
Balami	M	144	17	medium	14-18	18-21
Schirro	F	60	16	medium	10—14	10—14
Mulanka	M	78	13	medium	10—14	10—14
Yaki	M	84	17	medium	10—14	14—18
Jobber	F	84	19	medium	10—14	10—14
Gizo	F	66	14	medium	10—14	10—14
Kafi kurege	F	108	17	medium	14-18	14-18
Shahu	M	60	24	medium	10—14	10—14
Bingo-D	F	60	14	medium	7—10	7—10

APPENDIX IIa:

SONOGRAPHIC MEASUREMENT OF OCULAR PARAMETERS OF LENGTH IN INDIDGENOUS DOGS (GROUP ONE)

S/N	RD1	LD1	RD2	LD2	RD3	LD3	RD4	LD4	RD5	LD5
1	1	1	3	3	14	13	26	25	44	42
2	1	2	4	3	14	14	26	23	45	42
3	1	1	2	2	9	14	20	25	32	42
4	1	1	2	2	10	13	17	20	30	36
5	1	1	1	2	9	15	22	21	33	39
6	1	1	2	2	9	12	25	25	37	40
7	1	1	2	2	10	16	21	26	34	45
8	2	2	2	2	9	15	18	26	32	44
9	1	1	2	2	12	13	20	22	35	38
10	2	1	2	2	9	13	24	20	37	36
11	1	2	2	3	12	16	17	21	32	42
12	1	1	2	2	12	10	20	17	35	30
13	2	1	3	2	11	12	24	20	40	35
14	1	1	2	2	15	14	23	19	41	36
15	1	2	2	2	12	13	28	21	43	38
16	1	1	2	2	10	12	23	25	36	40
17	1	1	2	2	10	15	21	26	34	44
18	1	1	2	2	9	13	20	25	32	41
19	1	1	2	2	10	14	26	22	39	39
20	1	1	2	2	12	14	23	19	38	36
21	1	1	2	2	8	11	21	24	32	38
22	2	1	2	2	12	13	22	23	38	39
23	2	1	2	2	15	14	20	24	39	41
24	1	1	4	2	12	12	24	27	41	42

25	1	2	3	3	14	13	25	22	43	40
26	1	1	2	2	13	11	24	24	40	38
27	1	1	2	2	15	16	20	20	38	39
28	1	1	3	2	15	12	29	26	48	41
29	1	1	3	3	14	16	22	21	40	41
30	1	1	2	2	13	12	22	23	38	38
31	2	1	3	2	12	13	24	24	41	40
32	1	2	3	2	14	14	27	23	45	41
33	2	1	4	3	13	13	26	25	45	42
34	1	1	3	3	13	14	28	26	45	44
35	1	1	4	3	15	12	26	27	46	43

APPENDIX IIb:

SONOGRAPHIC MEASUREMENT OF OCULAR PARAMETERS OF LENGTH IN INDIDGENOUS DOGS (GROUP TWO)

S/N	RD1	LD1	RD2	LD2	RD3	LD3	RD4	LD4	RD5	LD5
1	2	1	3	4	9	9	37	38	51	52
2	1	1	3	2	17	15	24	28	45	46
3	1	1	2	2	12	15	26	27	41	45
4	1	1	2	2	14	11	23	21	40	35
5	1	1	2	2	16	12	21	23	40	38
6	2	1	2	2	14	15	20	21	38	39
7	2	1	2	2	14	18	25	23	43	44
8	1	1	2	2	9	12	30	25	42	40
9	1	1	2	2	14	16	23	20	40	39
10	2	2	3	2	18	17	24	22	47	43
11	1	2	3	2	14	14	31	28	49	46
12	1	1	3	2	14	16	25	21	43	40
13	1	1	3	2	14	12	24	20	42	35
14	1	2	3	3	16	14	22	22	42	41
15	2	2	4	2	14	11	28	27	48	42
16	1	2	3	2	12	13	22	20	38	37
17	2	2	3	2	14	13	23	24	42	41
18	2	1	3	3	12	14	25	23	42	41
19	1	1	3	2	14	12	25	23	43	38
20	2	1	5	3	13	15	25	27	45	46
21	2	1	2	2	12	12	24	25	40	40
22	1	2	3	2	12	14	25	28	41	46
23	2	1	3	2	16	15	30	24	51	42
24	2	1	4	3	11	12	25	27	42	43
25	2	1	4	2	15	12	28	25	49	40
26	2	1	2	2	13	14	27	26	44	43

APPENDIX IIc:

SONOGRAPHIC MEASUREMENT OF OCULAR PARAMETERS OF LENGTH IN INDIDGENOUS DOGS (GROUP THREE)

S/N	RD1	LD1	RD2	LD2	RD3	LD3	RD4	LD4	RD5	LD5
1	2	1	4	4	16	14	23	24	45	43
2	1	1	3	4	15	12	24	24	43	41
3	1	2	4	4	16	14	25	24	46	44
4	2	2	3	3	16	12	25	22	46	39
5	2	2	2	2	14	13	22	20	40	37
6	2	2	3	3	15	16	20	23	40	41
7	2	2	3	2	17	15	27	24	49	43
8	2	2	2	2	18	19	22	22	44	45
9	2	2	1	2	14	15	20	22	37	41
10	2	2	2	1	16	16	23	22	43	41
11	2	2	1	1	19	19	27	25	49	47
12	2	2	2	2	13	14	21	25	38	43
13	2	2	3	2	15	14	21	24	41	42
14	2	2	2	3	15	15	22	23	41	43
15	1	2	2	2	13	13	23	23	39	40
16	2	2	3	2	12	13	20	22	37	39
17	2	2	1	1	19	19	26	27	48	49
18	1	1	3	2	15	14	23	24	42	41
19	2	1	4	3	16	13	29	27	51	44

APPENDIX IIIa:

SONOGRAPHIC MEASUREMENT OF OCULAR PARAMETERS OF AREA IN INDIDGENOUS DOGS (GROUP ONE)

S/N	RA1	LA1	RA2	LA2	RA3	LA3	RA4	LA4
1	50	49	68	71	1148	1095	1506	1215
2	51	53	69	61	1165	1027	1427	1372
3	28	30	108	272	495	921	1118	1149
4	32	28	120	222	600	861	1056	1115
5	24	34	124	248	578	798	975	1101
6	29	30	122	260	464	814	819	1001
7	17	30	174	240	645	901	1128	1098
8	15	26	169	278	512	790	839	1100
9	14	28	196	298	672	712	1023	1013
10	27	16	159	177	1066	1170	1611	1475
11	21	34	217	271	706	799	1243	1386
12	11	26	167	219	555	595	969	1022
13	34	18	232	233	747	792	1297	1179
14	22	27	250	285	926	1058	1440	1334
15	32	21	181	275	987	860	1337	1318
16	34	19	175	160	1130	1009	1581	1510
17	42	22	174	184	1225	1195	1669	1453
18	28	32	112	282	482	921	1102	1214
19	27	30	152	299	524	889	1422	1261
20	26	29	141	263	701	927	1114	1276
21	28	30	104	252	602	602	1156	1201

22	31	30	173	189	874	909	1237	1288
23	33	30	236	281	1122	1200	1336	1399
24	42	31	268	268	1029	1101	1563	1424
25	34	33	189	192	1210	1188	1495	1388
26	29	33	183	168	1206	917	1794	1259
27	32	32	309	271	1250	1359	1679	1789
28	46	32	278	268	975	968	1437	1224
29	37	37	218	298	869	884	1287	1214
30	30	30	224	250	1059	1080	1436	1455
31	33	30	200	219	1030	1030	1560	1560
32	30	29	286	286	1189	1044	1474	1380
33	31	30	259	250	1228	1214	1847	1780
34	39	39	255	275	991	980	1676	1410
35	53	38	315	288	1295	1301	1848	1717

APPENDIX IIIb:

SONOGRAPHIC MEASUREMENT OF OCULAR PARAMETERS OF AREA IN INDIDGENOUS DOGS (GROUP TWO)

S/N	RA1	LA1	RA2	LA2	RA3	LA3	RA4	LA4
1	33	36	273	298	772	1205	1314	1404
2	22	27	237	259	736	908	1495	1369
3	34	21	261	209	888	8088	1108	1195
4	30	25	265	244	962	782	1645	1302
5	25	14	253	218	859	860	1363	1460
6	30	36	278	306	974	1098	1645	1430
7	19	34	174	160	1130	1009	1581	1510
8	35	25	243	315	788	1150	1422	1575
9	42	46	338	296	988	902	1389	1289
10	20	24	223	223	981	959	1187	1139
11	33	39	194	259	1041	1171	1413	1471
12	30	37	259	231	1064	999	1453	1314
13	34	35	237	251	938	951	1462	1441
14	33	40	227	211	1103	1111	1468	1439
15	44	51	246	281	1131	891	1540	1282
16	34	38	208	281	759	861	1544	1331
17	41	42	231	317	1113	1091	1349	1313
18	30	33	276	211	1208	1091	1592	1491
19	49	50	258	291	905	1008	1499	1400
20	33	33	204	240	1036	1101	1564	1346
21	26	28	351	370	1668	1591	1730	1680
22	24	33	255	245	1261	1231	1572	1477
23	38	49	195	210	1036	1030	1523	1488
24	30	48	282	219	1295	1123	1760	1689
25	38	47	330	381	1290	1209	1580	1444

APPENDIX 3c:

SONOGRAPHIC MEASUREMENT OF OCULAR PARAMETERS OF AREA IN INDIDGENOUS DOGS (GROUP THREE)

S/N	RA1	LA1	RA2	LA2	RA3	LA3	RA4	LA4
1	42	41	284	299	1141	1150	1780	1736
2	36	50	369	278	1141	1150	1790	1660
3	44	49	326	300	1208	1189	1593	1489
4	44	38	260	242	1014	1100	1485	1495
5	29	30	203	212	1114	1114	1310	1315
6	32	30	215	276	1264	1269	1510	1569
7	34	36	293	270	1207	1254	1559	1513
8	23	26	253	269	1098	1088	1312	1325
9	29	27	282	290	958	908	1210	1255
10	20	25	303	299	1116	1099	1372	1410
11	24	23	344	330	1258	1206	1698	1650
12	22	27	278	281	1001	1072	1415	1470
13	19	26	215	209	1111	1181	1378	1410
14	20	19	251	248	1140	1190	1412	1455
15	24	24	192	199	909	910	1288	1280
16	22	22	200	202	891	902	1250	1289
17	28	28	201	221	1195	1209	1580	1444
18	64	48	317	317	1148	1181	1863	1891
19	43	40	273	216	1257	1201	1396	1350

APPENDIX IVa:

MEASUREMENT OF % AREA COVERED BY EACH EYE SEGMENTS IN INDIGENOUS DOGS (GROUP ONE)

S/N	% ANTERIOR AREA	% LENS AREA	% VITREOUS AREA
1	3.6	5.1	82.4
2	3.7	4.6	78.3
3	2.6	16.8	62.5
4	2.8	15.8	67.3
5	2.8	17.9	66.3
6	3.2	21	70.2
7	2.1	18.6	69.5
8	2.1	23	67.1
9	2.1	24.3	68
10	1.4	10.9	72.5
11	2.1	18.6	57.2
12	1.9	19.4	57.8
13	2.1	18.8	62.2
14	1.8	19.3	71.5
15	2	17.2	74.7
16	1.7	10.8	59.8
17	2	11.5	68.5
18	2.6	17	60.6
19	2.1	16.9	52.7
20	2.3	16.9	68.1
21	2.5	15.1	51.1
22	2.4	14.3	70.6
23	2.3	18.9	84.9
24	2.4	17.9	71.3
25	2.3	13.2	83.2
26	2	11.5	69.5
27	1.8	16.7	75.2
28	2.9	20.5	73
29	2.5	20.6	70.1
30	2.1	16.4	74
31	2	13.4	66
32	2.1	20	78.2
33	1.7	14	67.3
34	2.5	17.1	63.9
35	2.6	16.9	72.8

APPENDIX IVb:

MEASUREMENT OF % AREA COVERED BY EACH EYE SEGMENTS IN INDIGENOUS DOGS (GROUP TWO)

S/N	% ANTERIOR AREA	% LENS AREA	% VITREOUS AREA
1	2.9	6	69.1
2	2.5	21	72.7
3	1.7	17.3	57.4
4	2.4	20.4	73.6
5	1.9	17.3	59.2
6	1.4	16.7	60.9
7	2.1	19	67.4
8	1.7	10.8	69.2
9	2	18.6	64.7
10	3.3	23.7	70.6
11	1.9	19.2	83.4
12	2.5	15.7	76.7
13	2.4	17.7	74.6
14	2.4	16.8	65.1
15	2.5	15.1	76.2
16	3.4	18.7	71.7
17	2.5	17	56.3
18	3.1	20.6	82.8
19	2	15.8	74.6
20	3.4	18.9	66
21	2.3	15.3	73.4
22	1.6	21.1	95.6
23	1.7	16.4	81.7
24	2.9	13.5	68.6
25	2.3	14.5	70.1
26	2.8	23.5	82.6

APPENDIX IVc:

MEASUREMENT OF % AREA COVERED BY EACH EYE SEGMENTS IN INDIGENOUS DOGS (GROUP THREE)

S/N	% ANTERIOR AREA	% LENS AREA	% VITREOUS AREA
1	2.4	16.6	65.2
2	2.5	18.8	66.4
3	3	20.3	77.8
4	2.8	16.8	75
5	2.2	15.8	84.9
6	2	15.9	82.3
7	2.3	18.3	80.1
8	1.9	19.8	82.9
9	2.3	23.2	75.7
10	1.6	21.6	79.6
11	1.4	20.1	73.6
12	1.7	19.4	71.9
13	1.6	15.2	82.2
14	1.4	17.4	81.3
15	1.9	15.2	70.83
16	1.7	15.8	70.6
17	1.9	14	79.5
18	3	16.9	62
19	3	7.8	89.5

APPENDIX V:
CLIENT CONSENT FORM

DEPARTMENT OF VETERINARY SURGERY AND RADIOLOGY
FACULTY OF VETERINARY MEDICINE
ABU, ZARIA
CLIENT CONSENT FORM

I, Audu, Hassan A., a PG student in the above stated department with Reg No. MSc/VET-MED/23500/12-13 wish solemnly to seek your indulgence to permit me use your dog(s) for the purpose of an M.Sc research work I am conducting. The research is purely a simple, easy and non-invasive procedure, entailing only of ophthalmologic examinations-ophthalmoscopy, tonometry and an ultrasound of the dog's eyes. This study will abide to all the Ethics on Animal Use for School and research purposes (Hassan *et al*., 2005) , and devoid from all forms of cruelty or abuse to such animal.
Thank you for granting my request.

……
Audu, Hassan A.
PG/Vet surgery and Radiology

……
Dr S.T Fadason
Chairman Supervisory Committee

……..
HOD Veterinary Surgery and Radiology

……..

Client name:-

Hassan, AZ; Kadima, KB; Remi-adewumi, BD; Awasum, CA and Abubakar, MT (2005): Animal models in surgical training: Choice and ethics. Review. *Nigerian journal of surgical research*.7(3– 4): 260-267

APPENDIX VIa

Some of the Equipment and Materials used for the pre-scan ophthalmic study



A- icare tonometer ONE®



B: Otoscope-Ophthalmoscope Type-C

APPENDIX VIb

Some of the Equipment and Materials used for the scanning procedure



Key: Ultrasound machine (US), probe (P), thermal printer (TP), Aquasonic gel (AG), tissue paper (T), iCare tonometer pack (TM)

APPENDIX VII:

Some of the Indigenous Nigerian dogs that were used for the study





Key A: puppy B: Adult dogs